KAPLAN

MEDICAL

USMLE®

STEP 1

Lecture Notes 2018

Anatomy

USMLE® is a joint program of the Federation of State Medical Boards (FSMB) and the National Board of Medical Examiners (NBME), neither of which sponsors or endorses this product.

KAPLAN

MEDICAL

USMLE®

STEP 1

Lecture Notes 2018

Anatomy

USMLE® is a joint program of the Federation of State Medical Boards (FSMB) and the National Board of Medical Examiners (NBME), neither of which sponsors or endorses this product.

This publication is designed to provide accurate information in regard to the subject matter covered as of its publication date, with the understanding that knowledge and best practice constantly evolve. The publisher is not engaged in rendering medical, legal, accounting, or other professional service. If medical or legal advice or other expert assistance is required, the services of a competent professional should be sought. This publication is not intended for use in clinical practice or the delivery of medical care. To the fullest extent of the law, neither the Publisher nor the Editors assume any liability for any injury and/or damage to persons or property arising out of or related to any use of the material contained in this book.

© 2018 by Kaplan, Inc.

Published by Kaplan Medical, a division of Kaplan, Inc.
750 Third Avenue
New York, NY 10017

10 9 8 7 6 5 4 3 2 1

Course ISBN: 978-1-5062-2823-5

All rights reserved. The text of this publication, or any part thereof, may not be reproduced in any manner whatsoever without written permission from the publisher. This book may not be duplicated or resold, pursuant to the terms of your Kaplan Enrollment Agreement.

Retail ISBN: 978-1-5062-3952-1

Kaplan Publishing print books are available at special quantity discounts to use for sales promotions, employee premiums, or educational purposes. For more information or to purchase books, please call the Simon & Schuster special sales department at 866-506-1949.

Editors

James White, PhD
Assistant Professor of Cell Biology
School of Osteopathic Medicine
Rowan University
Stratford, NJ

Adjunct Assistant Professor of Cell and Developmental Biology
University of Pennsylvania School of Medicine
Philadelphia, PA

David Seiden, PhD
Professor of Neuroscience and Cell Biology
Rutgers–Robert Wood Johnson Medical School
Piscataway, NJ

Table of Contents

Part I: Early Embryology and Histology: Epithelia

Chapter 1: Gonad Development 3

Chapter 2: First 8 Weeks of Development 7

Chapter 3: Histology: Epithelia 13

Part II: Gross Anatomy

Chapter 1: Back and Autonomic Nervous System 27

Chapter 2: Thorax 41

Chapter 3: Abdomen, Pelvis, and Perineum 93

Chapter 4: Upper Limb 187

Chapter 5: Lower Limb 203

Chapter 6: Head and Neck 215

Part III: Neuroscience

Chapter 1: Nervous System Organization and Development 235

Chapter 2: Histology of the Nervous System 245

Chapter 3: Ventricular System 257

Chapter 4: The Spinal Cord 263

Chapter 5: The Brain Stem 287

Chapter 6: The Cerebellum 321

Chapter 7: Basal Ganglia 329

Chapter 8: Visual Pathways 337

Chapter 9: Diencephalon 347

Chapter 10: Cerebral Cortex 353

Chapter 11: Limbic System 371

Index 377

Additional resources available at
www.kaptest.com/usmlebookresources

PART I

Early Embryology and Histology: Epithelia

Gonad Development 1

Learning Objectives

- ❑ Explain information related to indifferent gonad
- ❑ Interpret scenarios on testis and ovary
- ❑ Answer questions about meiosis
- ❑ Interpret scenarios on spermatogenesis
- ❑ Solve problems concerning oogenesis

INDIFFERENT GONAD

Although sex is determined at fertilization, the gonads initially go through an **indifferent stage** weeks 4–7 when there are no specific ovarian or testicular characteristics. The indifferent gonads develop in a longitudinal elevation or ridge of **intermediate mesoderm** called the **urogenital ridge**. The components of the indifferent gonads are as follows:

- **Primordial germ cells** provide a critical inductive influence on gonad development, migrating in at week 4. They arise from the lining cells in the wall of the yolk sac.
- **Primary sex cords** are finger-like extensions of the surface epithelium which grow into the gonad that are populated by the migrating primordial germ cells.
- **Mesonephric (Wolffian)** and the **paramesonephric (Mullerian)** ducts of the indifferent gonad contribute to the male and female genital tracts, respectively.

TESTIS AND OVARY

The indifferent gonad develops into either the testis or ovary.

Development of the **testis and male reproductive system** is directed by the following:

- **Sry gene** on the short arm of the **Y chromosome**, which encodes for **testis-determining factor** (TDF)
- **Testosterone,** which is secreted by the **Leydig cells**
- **Müllerian-inhibiting factor (MIF),** which is secreted by the **Sertoli cells**
- **Dihydrotestosterone (DHT):** external genitalia

Development of the **ovary and female reproductive system** requires estrogen. Ovarian development occurs in the absence of the Sry gene and in the presence of the WNT4 gene.

MIF: Müllerian-inhibiting factor
TDF: testis-determining factor

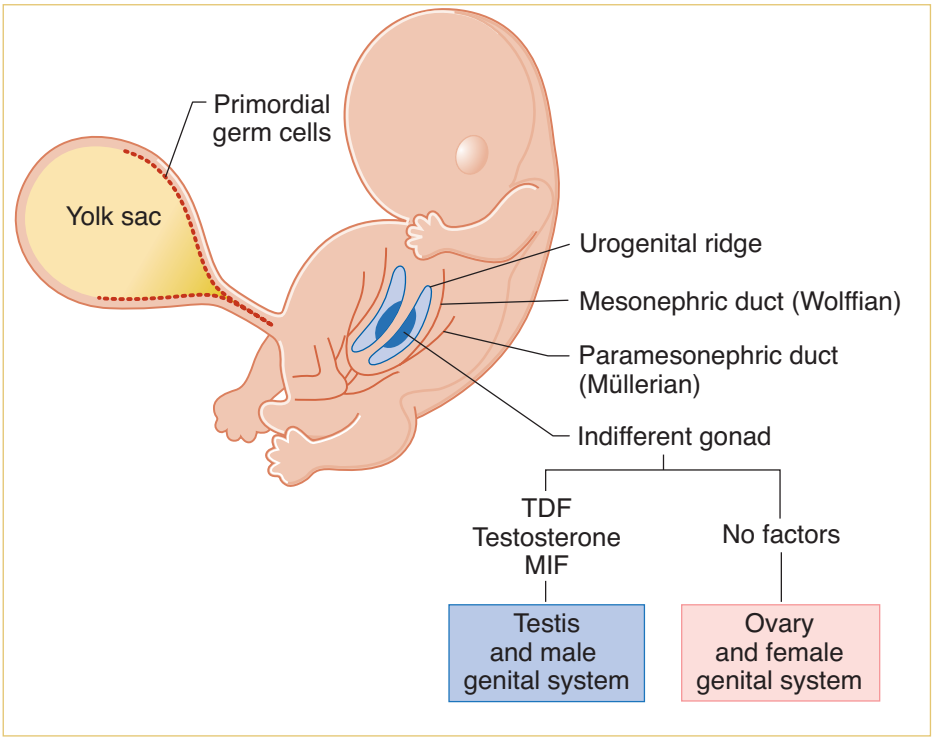

Figure I-1-1. Development of Testis and Ovary

MEIOSIS

Meiosis occurs within the testis and ovary. This is a specialized process of cell division that produces the male gamete **(spermatogenesis)** and female gamete **(oogenesis)**. There are notable differences between spermatogenesis and oogenesis.

Meiosis consists of 2 cell divisions. In **meiosis I**, the following events occur:

- **Synapsis:** pairing of 46 homologous chromosomes
- **Crossing over:** exchange of segments of DNA
- **Disjunction:** separation of 46 homologous chromosome pairs (no centromere-splitting) into 2 daughter cells, each containing 23 chromosome pairs

In **meiosis II,** synapsis does not occur, nor does crossing over. Disjunction does occur with centromere-splitting.

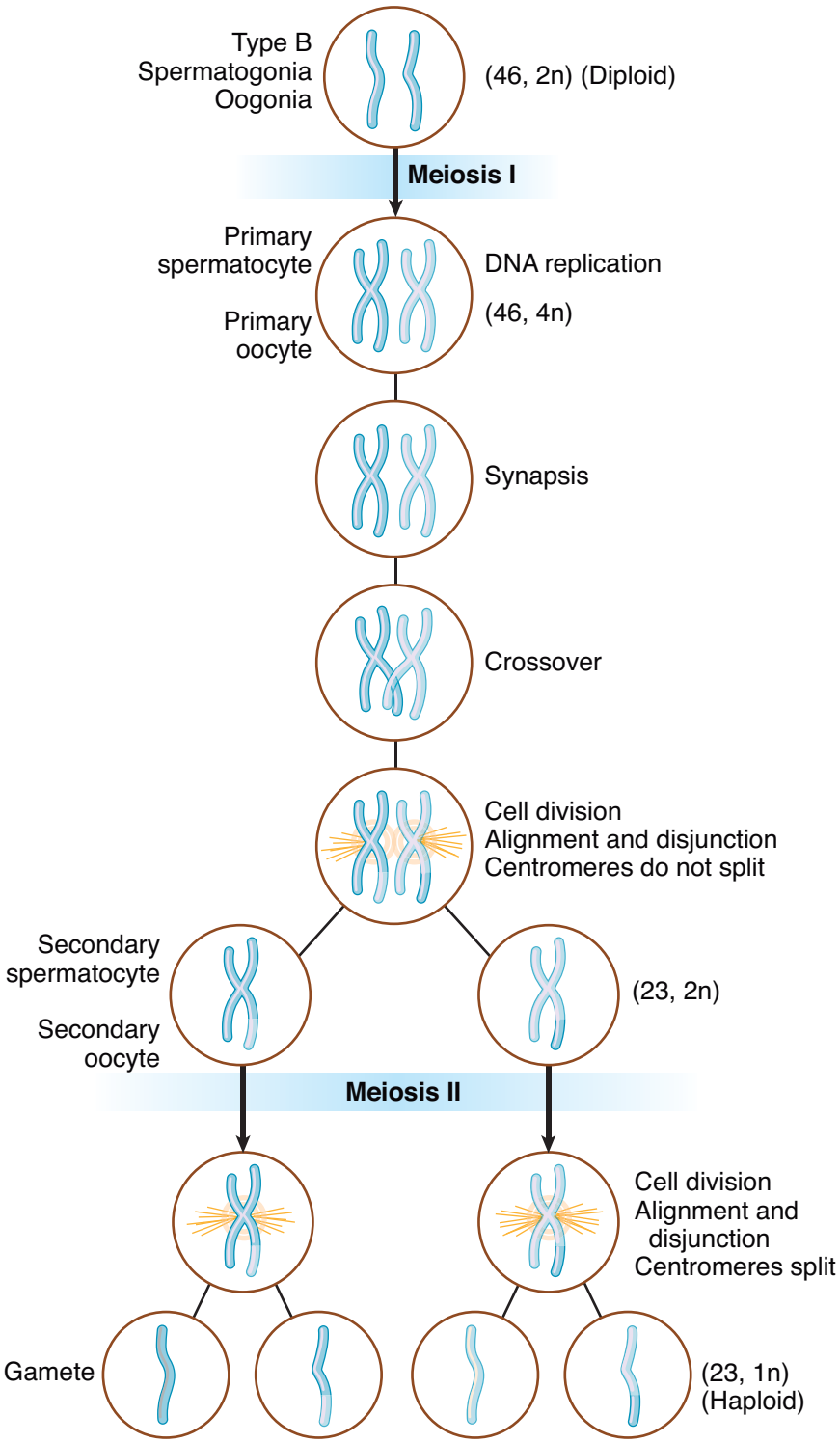

Figure I-1-2. Meiosis

SPERMATOGENESIS

At week 4, primordial germ cells arrive in the indifferent gonad and remain **dormant until puberty**.

- When a boy reaches puberty, primordial germ cells differentiate into **type A spermatogonia,** which serve as stem cells throughout adult life.
- Some type A spermatogonia differentiate into **type B spermatogonia.**
- Type B spermatogonia enter meiosis I to form **primary spermatocytes.**
- Primary spermatocytes form 2 **secondary spermatocytes**.
- Secondary spermatocytes enter meiosis II to form 2 **spermatids.**
- Spermatids undergo **spermiogenesis,** which is a series of morphological changes resulting in the mature **spermatozoa**.

OOGENESIS

At week 4, primordial germ cells arrive in the indifferent gonad and differentiate into oogonia. Oogonia enter meiosis I to **form primary oocytes**. All primary oocytes are formed by **month 5 of fetal life**; they are **arrested the first time in prophase (diplotene) of meiosis** I and remain arrested until puberty.

- Primary oocytes arrested in meiosis I are present at birth.
- When a girl reaches puberty, during each monthly cycle a primary oocyte becomes unarrested and completes meiosis I to form a secondary oocyte and polar body.
- The secondary oocyte becomes **arrested the second time in metaphase of meiosis II** and is ovulated.
- At fertilization within the uterine tube, the secondary oocyte completes meiosis II to form a **mature oocyte** and **polar body.**

First 8 Weeks of Development

2

Learning Objectives

- ❑ Solve problems concerning beginning of development
- ❑ Demonstrate understanding of the formation of the bilaminar embryo
- ❑ Solve problems concerning embryonic period

WEEK 1: BEGINNING OF DEVELOPMENT

Fertilization occurs in the **ampulla of the uterine tube** when the male and female pronuclei fuse to form a **zygote**. At fertilization, the secondary oocyte rapidly completes meiosis II.

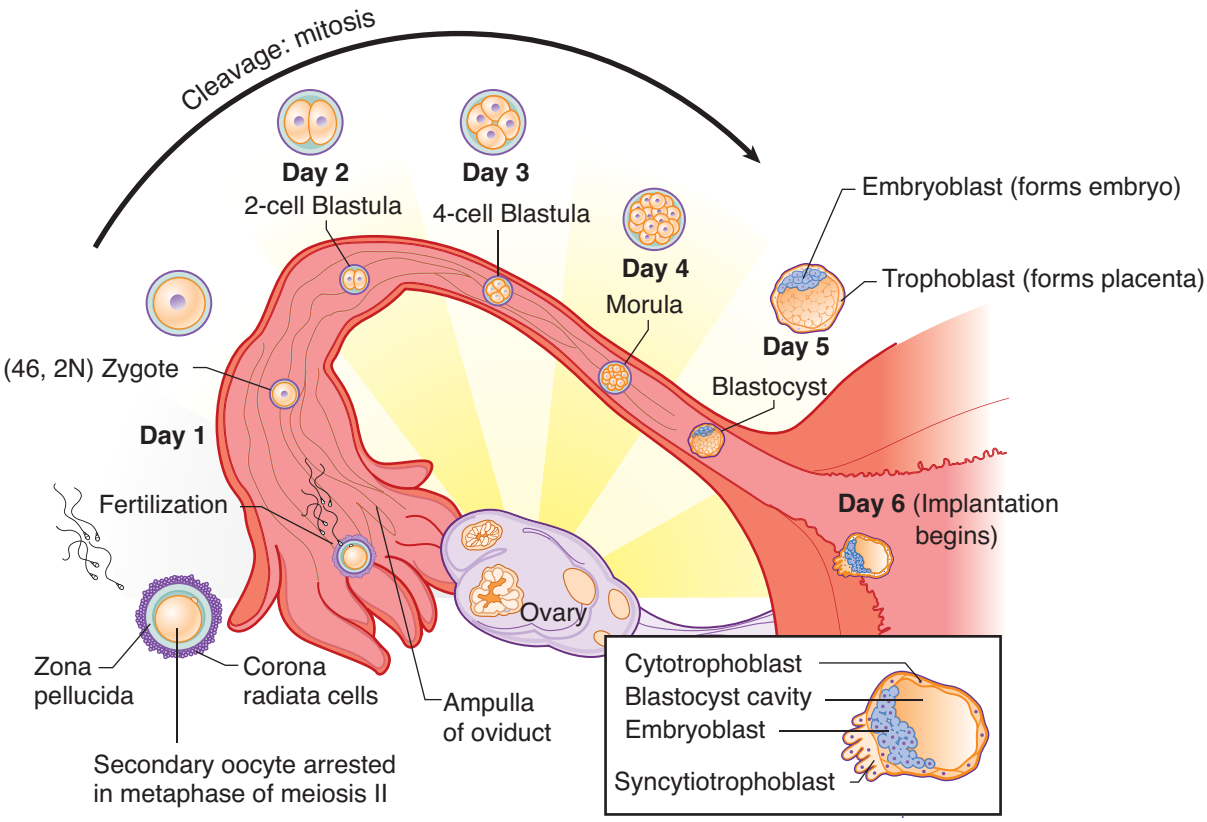

Figure I-2-1. Week 1

Prior to fertilization, spermatozoa undergo 2 changes in the female genital tract:

- **Capacitation** consists of the removal of several proteins from the plasma membrane of the acrosome of the spermatozoa. It occurs over about 7 hours in the female reproductive tract.
- Hydrolytic enzymes are released from the acrosome used by the sperm to penetrate the zona pellucida. This results in a **cortical reaction** that prevents other spermatozoa penetrating the zona pellucida thus preventing polyspermy.

During the first 4–5 days of week 1, the zygote undergoes rapid mitotic division (**cleavage**) in the oviduct to form a **blastula**, consisting of increasingly smaller **blastomeres**. This becomes the **morula** (32-cell stage).

A **blastocyst** forms as fluid develops in the morula. The blastocyst consists of an inner cell mass known as the **embryoblas**t, and the outer cell mass known as the **trophoblast**, which becomes the placenta.

At the end of week 1, the trophoblast differentiates into the **cytotrophoblast** and **syncytiotrophoblast** and then implantation begins.

Clinical Correlate

Ectopic Pregnancy

Tubal (most common form) usually occurs when the blastocyst **implants within the ampulla** of the uterine tube because of delayed transport. Risk factors include endometriosis, pelvic inflammatory disease, tubular pelvic surgery, and exposure to diethylstilbestrol (DES.) Clinical signs include abnormal or brisk uterine bleeding, sudden onset of abdominal pain that may be confused with appendicitis, missed menstrual period (e.g., LMP 60 days ago), positive human chorionic gonadotropin test, culdocentesis showing intraperitoneal blood, and positive sonogram.

Abdominal form usually occurs in the **rectouterine pouch** (pouch of Douglas).

Implantation

For implantation to occur, the **zona pellucida** must degenerate. The blastocyst usually implants within the **posterior wall of the uterus.** The embryonic pole of blastocyst implants first. The blastocyst implants within the **functional layer** of the endometrium during the **progestational phase** of the menstrual cycle.

WEEK 2: FORMATION OF THE BILAMINAR EMBRYO

In week 2, the embryoblast differentiates into the **epiblast** and **hypoblast**, forming a **bilaminar embryonic disk**. The epiblast forms the **amniotic cavity** and hypoblast cells migrate to form the **primary yolk sac**. The **prechordal plate**, formed from fusion of epiblast and hypoblast cells, is the site of the future **mouth**.

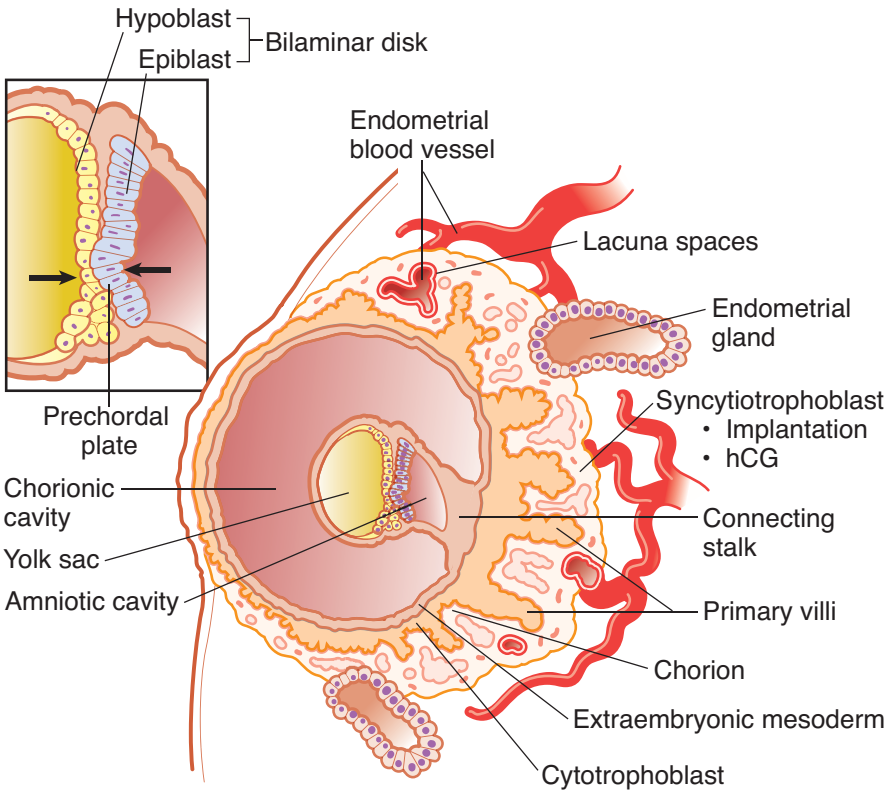

Figure I-2-2. Week 2

Extraembryonic mesoderm is derived from the epiblast. **Extraembryonic somatic mesoderm** lines the cytotrophoblast, forms the connecting stalk, and covers the amnion. **Extraembryonic visceral mesoderm** covers the yolk sac.

The connecting stalk suspends the conceptus within the chorionic cavity. The wall of the chorionic cavity is called the **chorion**, consisting of extraembryonic somatic mesoderm, the cytotrophoblast, and the syncytiotrophoblast.

The **syncytiotrophoblast** continues its growth into the endometrium to make contact with endometrial blood vessels and glands. **No mitosis occurs in the syncytiotrophoblast.** The cytotrophoblast is mitotically active.

Hematopoiesis occurs initially in the mesoderm surrounding the yolk sac (up to 6 weeks) and later in the fetal liver, spleen, thymus (6 weeks to third trimester), and bone marrow.

Clinical Correlate

Human chorionic gonadotropin (hCG), a glycoprotein produced by the syncytiotrophoblast, stimulates progesterone production by the corpus luteum. hCG can be assayed in maternal blood or urine and is the basis for early pregnancy testing. hCG is detectable throughout pregnancy.

- Low hCG level may predict a spontaneous abortion or ectopic pregnancy.
- High hCG level may predict a multiple pregnancy, hydatidiform mole, or gestational trophoblastic disease.

WEEKS 3–8: EMBRYONIC PERIOD

All major organ systems begin to develop during the **weeks 3–8**. By the end of this period, the embryo begins to look human, and the nervous and cardiovascular systems start to develop. Week 3 corresponds to the first missed menstrual period.

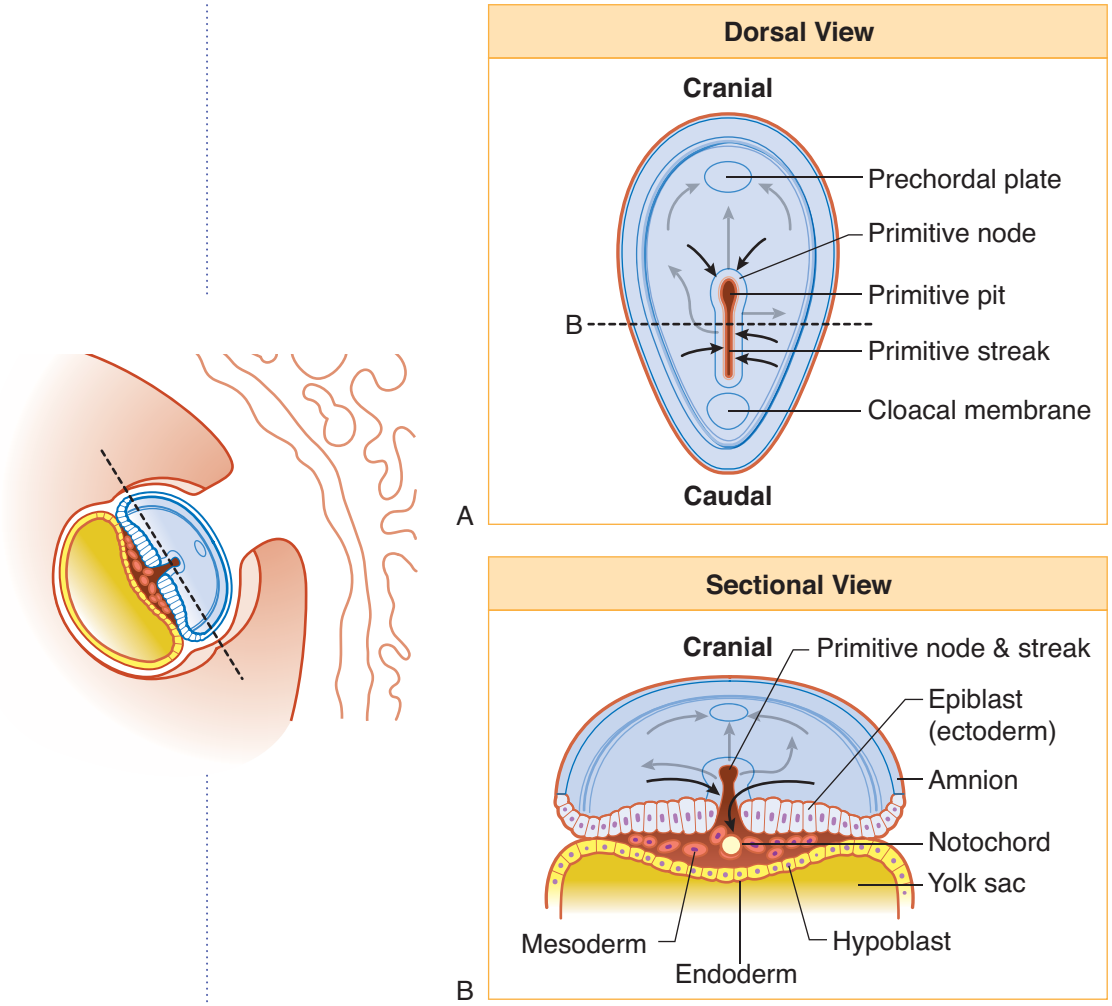

Figure I-2-3. Week 3

During this time **gastrulation** also takes place; this is the process by which the 3 primary germ layers are produced: **ectoderm, mesoderm**, and **endoderm**. It begins with the formation of the **primitive streak** within the epiblast.

- Ectoderm forms **neuroectoderm** and **neural crest cells.**
- Mesoderm forms **paraxial mesoderm** (35 pairs of somites), **intermediate mesoderm**, and **lateral mesoderm.**

Clinical Correlate

Sacrococcygeal teratoma: a tumor that arises from remnants of the primitive streak; often contains various types of tissue (bone, nerve, hair, etc)

Chordoma: a tumor that arises from remnants of the notochord, found either intracranially or in the sacral region

Hydatidiform mole: results from the partial or complete replacement of the trophoblast by dilated villi

- In a **complete mole, there is no embryo;** a haploid sperm fertilizes a blighted ovum and reduplicates so that the karyotype is 46,XX, with all chromosomes of paternal origin. In a **partial mole,** there is a haploid set of maternal chromosomes and usually 2 sets of paternal chromosomes so that the typical karyotype is 69,XXY.
- **Molar pregnancies have high levels of hCG, and 20% develop into a malignant trophoblastic disease, including choriocarcinoma.**

Table I-2-1. Germ Layer Derivatives

Ectoderm	Mesoderm	Endoderm
Surface ectoderm Epidermis Hair Nails Inner ear, external ear Enamel of teeth Lens of eye Anterior pituitary (Rathke's pouch) Parotid gland Anal canal below pectinate line **Neuroectoderm** Neural tube Central nervous system Retina and optic nerve Pineal gland Neurohypophysis Astrocytes Oligodendrocytes **Neural crest ectoderm** Adrenal medulla Ganglia Sensory—Pseudounipolar Neurons Autonomic—Postganglionic Neurons Pigment cells Schwann cells Meninges Pia and arachnoid mater Pharyngeal arch cartilage Odontoblasts Parafollicular (C) cells Aorticopulmonary septum Endocardial cushions	**Muscle** Smooth Cardiac Skeletal Connective tissue All serous membranes Bone and cartilage Blood, lymph, cardiovascular organs Adrenal cortex Gonads and internal reproductive organs Spleen Kidney and ureter Dura mater **Notochord** Nucleus pulposus	**Forms epithelial lining of:** GI track: foregut, midgut, and hindgut Lower respiratory system: larynx, trachea, bronchi, and lung Genitourinary system: urinary bladder, urethra, and lower vagina Pharyngeal pouches: • Auditory tube and middle ear • Palatine tonsils • Parathyroid glands • Thymus **Forms parenchyma of:** • Liver • Pancreas • Submandibular and sublingual glands • Follicles of thyroid gland
		Extra embryonic structures Yolk sac derivatives: Primordial germ cells Early blood cells and blood vessels

Histology: Epithelia 3

Learning Objectives

- ❑ Demonstrate understanding of epithelial cells
- ❑ Use knowledge of epithelium
- ❑ Interpret scenarios on cytoskeletal elements
- ❑ Explain information related to cell adhesion molecules
- ❑ Answer questions about cell surface specializations

Histology is the study of normal tissues. Groups of cells make up tissues, tissues form organs, organs form organ systems, and systems make up the organism. Each organ consists of 4 types of tissue: epithelial, connective, nervous, and muscular.

Only certain aspects of epithelia will be reviewed here; other aspects of histology are reviewed elsewhere in this book.

EPITHELIAL CELLS

Epithelial cells are often polarized: the structure, composition, and function of the apical surface membrane differ from those of the basolateral surfaces. The polarity is established by the presence of tight junctions that separate these 2 regions. Internal organelles are situated symmetrically in the cell. Membrane polarity and tight junctions are essential for the transport functions of epithelia.

Many simple epithelia transport substances from one side to the other (kidney epithelia transport salts and sugars; intestinal epithelia transport nutrients, antibodies, etc.). There are 2 basic mechanisms used for these transports:

- Transcellular pathway through which larger molecules and a combination of diffusion and pumping in the case of ions that pass through the cell
- Paracellular pathway that permits movement between cells

Tight junctions regulate the paracellular pathway, because they prevent backflow of transported material and keep basolateral and apical membrane components separate.

Epithelial polarity is essential to the proper functioning of epithelial cells; when polarity is disrupted, disease can develop. For example, epithelia lining the trachea, bronchi, intestine, and pancreatic ducts transport chloride from basolateral surface to lumen via pumps in the basolateral surface and channels in

the apical surface. The transport provides a driving force for Na by producing electrical polarization of the epithelium. Thus NaCl moves across, and water follows. In cystic fibrosis the apical Cl channels do not open. Failure of water transport results in thickening of the mucous layer covering the epithelia.

Transformed cells may lose their polarized organization, and this change can be easily detected by using antibodies against proteins specific for either the apical or basolateral surfaces. Loss of polarity in the distribution of membrane proteins may eventually become useful as an early index of neoplasticity.

Epithelia are always lined on the basal side by connective tissue containing blood vessels. Since epithelia are avascular, interstitial tissue fluids provide epithelia with oxygen and nutrients.

Epithelia modify the 2 compartments that they separate. The epithelial cells may either secrete into or absorb from each compartment, and may selectively transport solutes from one side of the barrier to the other.

Epithelia renew themselves continuously, some very rapidly (skin and intestinal linings), some at a slower rate. This means that the tissue contains stem cells that continuously proliferate. The daughter cells resulting from each cell division either remain in the pool of dividing cells or differentiate.

The epithelial subtypes are as follows:

- Simple cuboidal epithelium (e.g., renal tubules, salivary gland acini)
- Simple columnar epithelium (e.g., small intestine)
- Simple squamous epithelium (e.g., endothelium, mesothelium, epithelium lining the inside of the renal glomerular capsule)
- Stratified squamous epithelium: nonkeratinized (e.g., esophagus) and keratinizing (e.g., skin)
- Pseudostratified columnar epithelium (e.g., trachea, epididymis)
- Transitional epithelium (urothelium) (e.g., ureter and bladder)
- Stratified cuboidal epithelium (e.g., salivary gland ducts)

EPITHELIUM

Hematoxylin-and-Eosin Staining

The most common way to stain tissues for viewing in the light microscope is to utilize hematoxylin-and-eosin (H&E) staining.

Hematoxylin is a blue dye which stains basophilic substrates that are the acidic cellular components such as DNA and RNA. Hematoxylin stains nuclei blue, and may tint the cytoplasm of cells with extensive mRNA in their cytoplasm.

Copyright McGraw-Hill Companies. Used with permission.

Figure I-3-1. Kidney tubule simple cuboidal epithelium (arrow) stained with H&E, L-lumen

Eosin is a pink-to-orange dye which stains acidophilic substrates such as basic components of most proteins. Eosin stains the cytoplasm of most cells and many extracellular proteins, such as collagen, pink.

Epithelial Subtypes

Simple columnar epithelium is found in the small and large intestine.

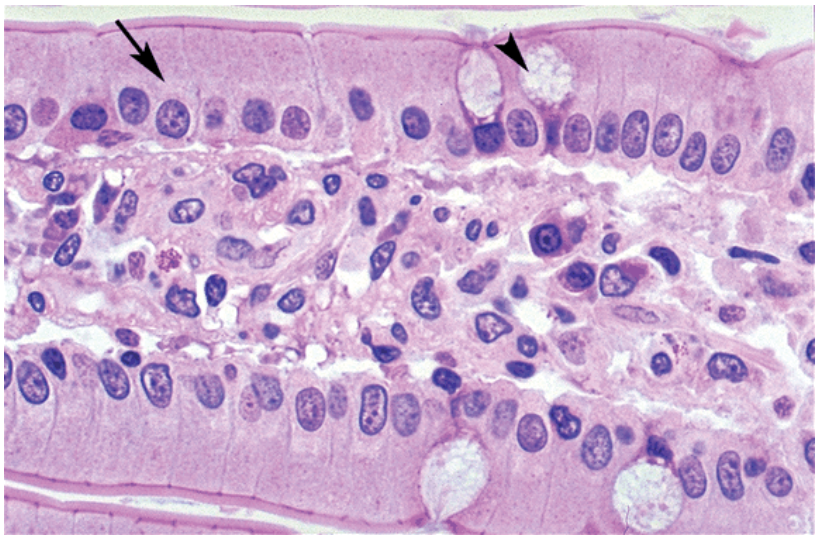

Copyright McGraw-Hill Companies. Used with permission.

Figure I-3-2. Small Intestine Simple Columnar Epithelium Enterocytes (arrow), Goblet cells (arrowhead)

Simple squamous epithelium forms an endothelium that lines blood vessels, a mesothelium that forms part of a serous membrane or forms the epithelium lining of the inside of the renal glomerular capsule.

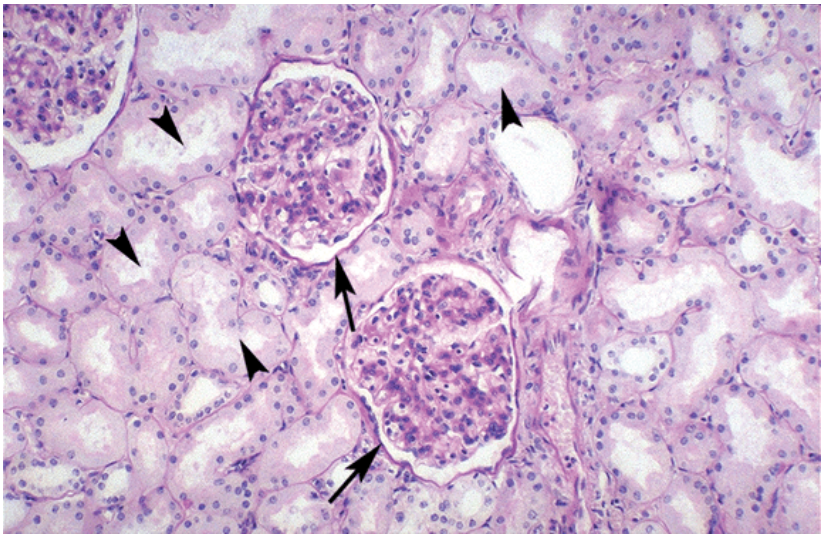

Copyright McGraw-Hill Companies. Used .with permission.

Figure I-3-3. Kidney simple squamous epithelium (arrows), simple cuboidal epithelium (arrowheads)

Pseudostratified columnar epithelium is found in the nasal cavity, trachea, bronchi, and epididymis.

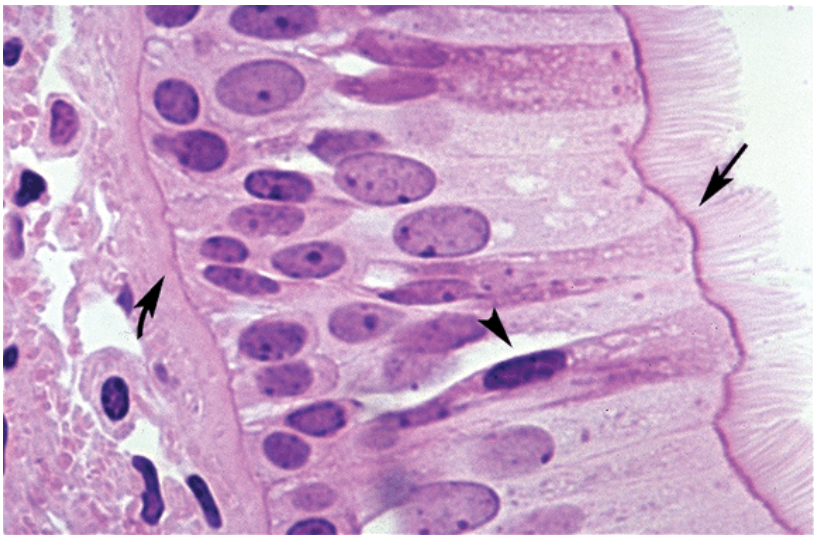

Copyright McGraw-Hill Companies. Used with permission.

Figure I-3-4. Trachea pseudostratified columnar epithelium with true cilia (arrow) and goblet cells (arrowhead), basement membrane (curved arrow)

Transitional epithelium is found in the ureter and bladder.

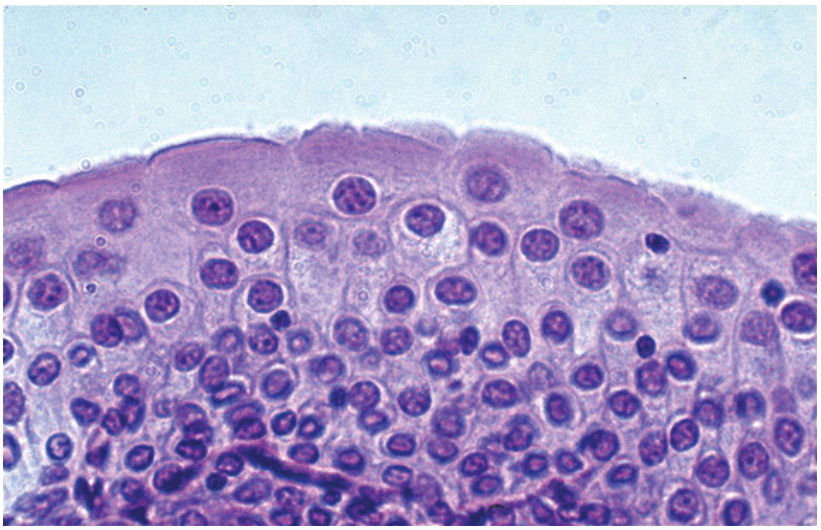

Copyright McGraw-Hill Companies. Used with permission.

Figure I-3-5. Bladder Transitional Epithelium

Stratified squamous epithelium is found in the oral cavity, pharynx, and esophagus (non-keratinized) and in the skin (keratinizing).

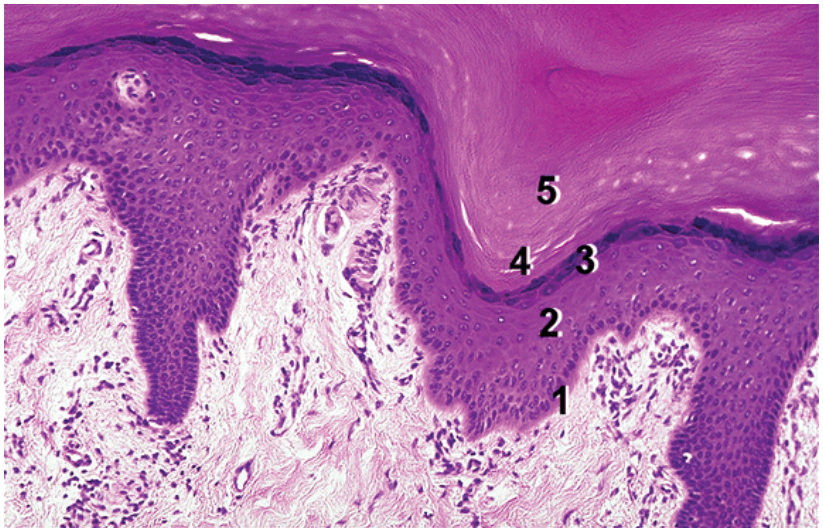

Copyright McGraw-Hill Companies. Used with permission.

Figure I-3-6. Stratified Squamous Epithelium (Thick Skin)
(1) stratum basale (2) stratum spinosum (3) stratum granulosum
(4) stratum lucidum (5) stratum corneum

Simple cuboidal epithelium is the epithelium of the renal tubules and the secretory cells of salivary gland acini.

Stratified cuboidal epithelium is found in the ducts of salivary glands.

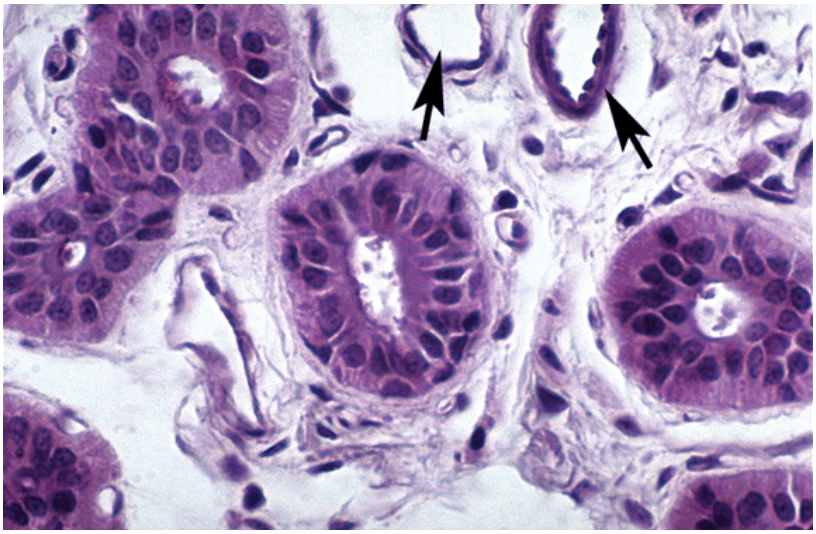

Copyright McGraw-Hill Companies. Used with permission.

Figure I-3-7. Ducts of salivary gland with stratified cuboidal epithelium small blood vessels with endothelium and smooth muscle (arrows)

Glands

Unicellular glands are goblet cells found in the respiratory and GI epithelium. **Multicellular glands** may be exocrine (salivary gland) or endocrine (thyroid gland), but all have tubules or acini formed mainly by a simple cuboidal epithelium. Only exocrine glands have ducts, which serve as conduits for glandular secretions to a body surface or to a lumen.

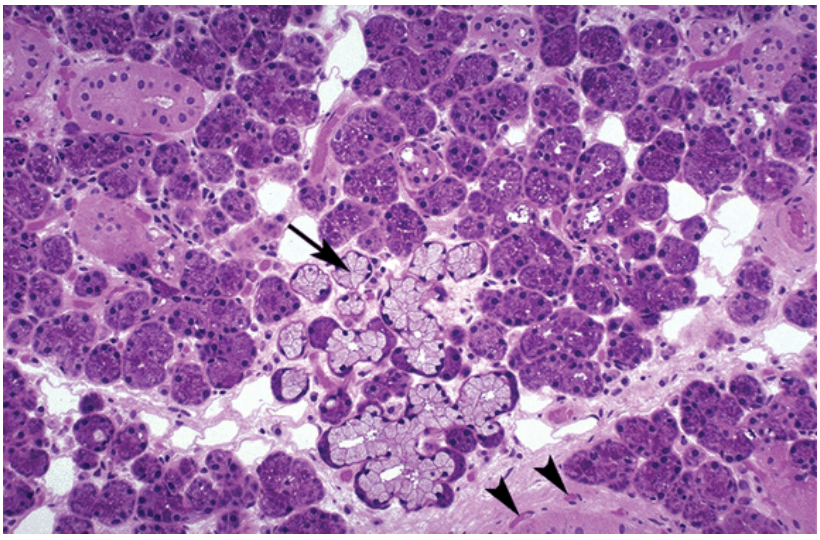

Copyright McGraw-Hill Companies. Used with permission.

Figure I-3-8. Submandibular Gland

Mixed salivary gland with mucous acini (arrow) and darker staining serous acini; small blood vessels (arrowheads)

CYTOSKELETAL ELEMENTS

Microfilaments

Microfilaments are actin proteins. They are composed of globular monomers of G-actin that polymerize to form helical filaments of F-actin. Actin polymerization is ATP dependent. The F-actin filaments are 7-nm-diameter filaments that are constantly ongoing assembly and disassembly. F-actin has a distinct polarity. The barbed end (the plus end) is the site of polymerization and the pointed end is the site of depolymerization. Tread milling is the balance in the activity at the 2 ends.

In conjunction with myosin, actin microfilaments provide contractile and motile forces of cells including the formation of a contractile ring that provides a basis for cytokinesis during mitosis and meiosis. Actin filaments are linked to cell membranes at tight junctions and at the zonula adherens, and form the core of microvilli.

Intermediate Filaments

Intermediate filaments are 10-nm-diameter filaments that are usually stable once formed. These filaments provide structural stability to cells. There are 4 types:

- **Type I:** keratins (keratins are found in all epithelial cells)
- **Type II:** intermediate filaments comprising a diverse group
  - Desmin is found in skeletal, cardiac, and GI tract smooth muscle cells.
  - Vimentin is found in most fibroblasts, fibrocytes, endothelial cells, and vascular smooth muscle.
  - Glial fibrillary acidic protein is found in astrocytes and some Schwann cells.
  - Peripherin is found in peripheral nerve axons.
- **Type III:** intermediate filaments forming neurofilaments in neurons
- **Type IV:** 3 types of lamins forming a meshwork rather than individual filaments inside the nuclear envelope of all cells

Microtubules

Microtubules consist of 25-nm-diameter hollow tubes. Like actin, microtubules undergo continuous assembly and disassembly. They provide "tracks" for intracellular transport of vesicles and molecules. Such transport exists in all cells but is particularly important in axons. Transport requires specific ATPase motor molecules; **dynein** drives retrograde transport and **kinesin** drives anterograde transport.

Microtubules are found in **true cilia and flagella**, and utilize dynein to convey motility to these structures. Microtubules form the mitotic spindle during mitosis and meiosis.

Clinical Correlate

A first step in the invasion of malignant cells through an epithelium results from a loss of expression of cadherins that weakens the epithelium.

Clinical Correlate

Changes in intermediate filaments are evident in neurons in Alzheimer's disease and in cirrhotic liver diseases.

Clinical Correlate

Colchicine prevents microtubule polymerization and is used to prevent neutrophil migration in gout. Vinblastine and vincristine are used in cancer therapy because they inhibit the formation of the mitotic spindle.

CELL ADHESION MOLECULES

Cell adhesion molecules are surface molecules that allow cells to adhere to one another or to components of the extracellular matrix. The expression of adhesion molecules on the surface of a given cell may change with time, altering its interaction with adjacent cells or the extracellular matrix.

Cadherin and selectin are adhesion molecules that are **calcium ion-dependent**. The extracellular portion binds to a cadherin dimer on another cell (trans binding). The cytoplasmic portions of cadherins are linked to cytoplasmic actin filaments by the catenin complex of proteins.

Integrins are adhesion molecules that are **calcium-independent**. They are transmembrane surface molecules with extracellular domains that bind to fibronectin and laminin, which are components of extracellular basement membrane. The cytoplasmic portions of integrins bind to actin filaments. Integrins form a portion of hemidesmosomes but are also important in interactions between leukocytes and endothelial cells.

CELL SURFACE SPECIALIZATIONS

Cell Adhesion

A cell must physically interact via cell surface molecules with its external environment, whether it be the extracellular matrix or **basement membrane.** The basement membrane is a sheet-like structure underlying virtually all epithelia, which consists of **basal lamina** (made of type IV collagen, glycoproteins [e.g., laminin], and proteoglycans [e.g., heparin sulfate]), and **reticular lamina** (composed of reticular fibers). Cell junctions anchor cells to each other, seal boundaries between cells, and form channels for direct transport and communication between cells. The 3 types of junctional complex include **anchoring, tight,** and **gap junctions**.

Cell Junctions

Tight junctions (zonula occludens) function as barriers to diffusion and determine cell polarity. They form a series of punctate contacts of adjacent epithelial cells near the apical end or luminal surface of epithelial cells. The major components of tight junctions are occludens (ZO-1,2,3) and claudin proteins. These proteins span between the adjacent cell membranes and their cytoplasmic parts bind to actin microfilaments.

Zonula adherens forms a belt around the entire apicolateral circumference of the cell, immediately below the tight junction of epithelium. Cadherins span between the cell membranes. Like the tight junctions immediately above them, the cytoplasmic parts of cadherins are associated with actin filaments.

Desmosomes (macula adherens) function as anchoring junctions. Desmosomes provide a structural and mechanical link between cells. Cadherins span between the cell membranes of desmosomes and internally desmosomes are anchored to intermediate filaments in large bundles called tonofilaments.

Hemidesmosomes adhere epithelial cells to the basement membrane. The basement membrane is a structure that consists of the basal membrane of a cell

Clinical Correlate

Pemphigus Vulgaris

- Autoantibodies against desmosomal proteins in skin cells
- Painful flaccid bullae (blisters) in oropharynx and skin that rupture easily
- Postinflammatory hyperpigmentation
- Treatment: corticosteroids

Bullous Pemphigoid

- Autoantibodies against basement-membrane hemidesmosomal proteins
- Widespread blistering with pruritus
- Less severe than pemphigus vulgaris
- Rarely affects oral mucosa
- Can be drug-induced (e.g., middle-aged or elderly patient on multiple medications)
- Treatment: corticosteroids

and 2 underlying extracellular components, the basal lamina and the reticular lamina. The basal lamina is a thin felt-like extracellular layer composed of predominantly of type IV collagen associated with laminin, proteoglycans, and fibronectin that are secreted by epithelial cells. Fibronectin binds to integrins on the cell membrane, and fibronectin and laminin in turn bind to collagen in the basal lamina. Internally, like a desmosome, the hemidesmosomes are linked to intermediate filaments. Below the basal lamina is the reticular lamina, composed of reticular fibers.

Through the binding of extracellular components of hemidesmosomes to integrins, and thus to fibronectin and laminin, the cell is attached to the basement membrane and therefore to the extracellular matrix components outside the basement membrane. These interactions between the cell cytoplasm and the extracellular matrix have implications for permeability, cell motility during embryogenesis, and cell invasion by malignant neoplasms.

Gap junctions (communicating junctions) function in cell-to-cell communication between the cytoplasm of adjacent cells by providing a passageway for ions such as calcium and small molecules such as cyclic adenosine monophosphate (cAMP). The transcellular channels that make up a gap junction consist of connexons, which are hollow channels spanning the plasma membrane. Each connexon consists of 6 connexin molecules. Unlike other intercellular junctions, gap junctions are not associated with any cytoskeletal filament.

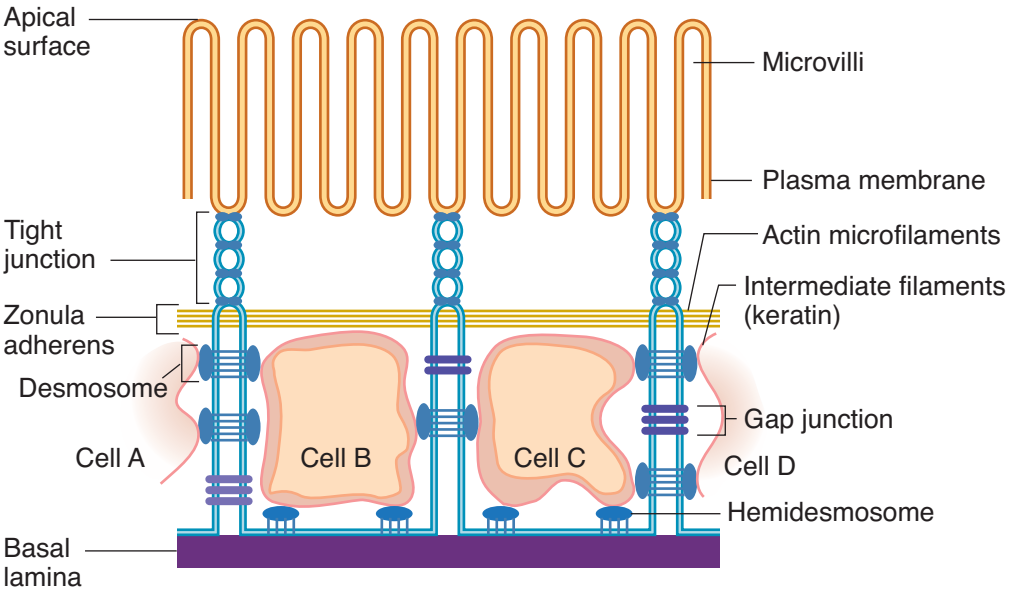

Figure I-3-9. Junctions

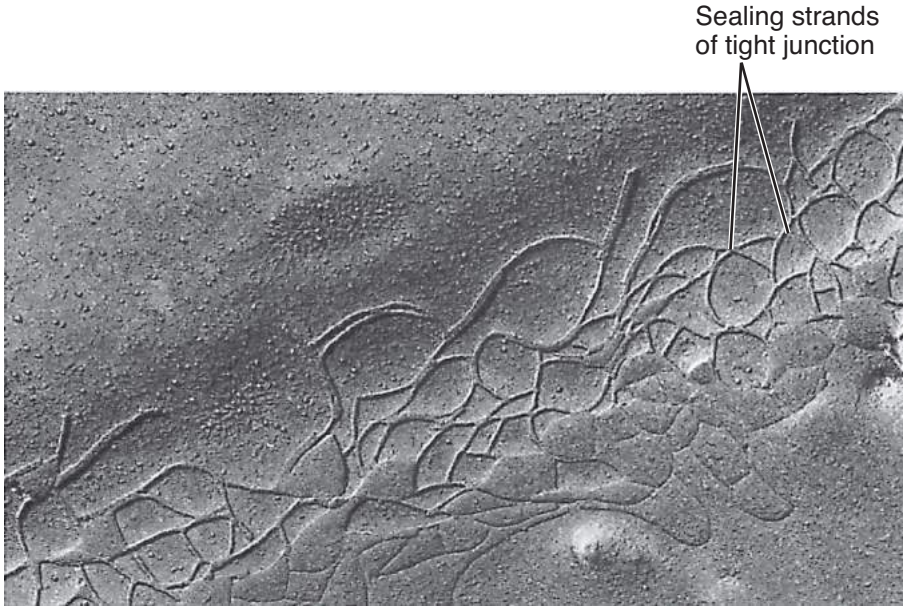

Copyright Lippincott Williams & Wilkins. Used with permission.

Figure I-3-10. Freeze-fracture of Tight Junction

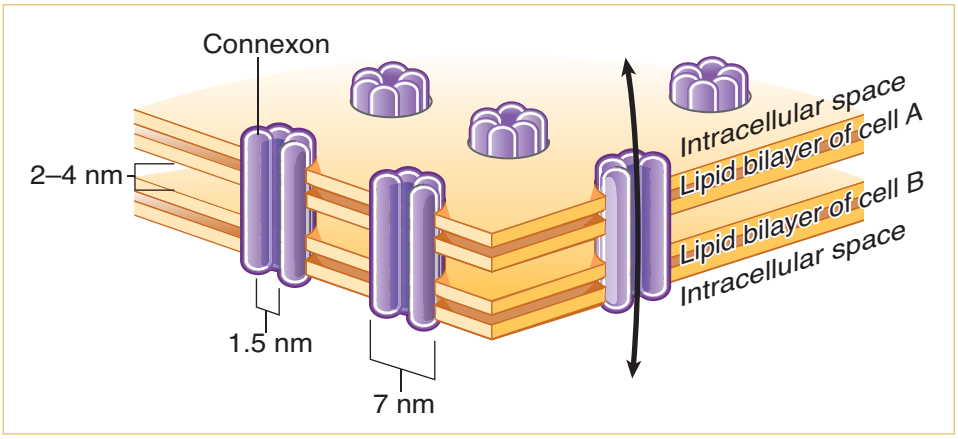

Figure I-3-11. Gap Junction

Microvilli

Microvilli contain a core of actin microfilaments and function to increase the absorptive surface area of an epithelial cell. They are found in columnar epithelial cells of the small and large intestine, cells of the proximal tubule of the kidney and on columnar epithelial respiratory cells.

Stereocilia are long, branched microvilli that are found in the male reproductive tract (e.g., epididymis). Short stereocilia cap all sensory cells in the inner ear.

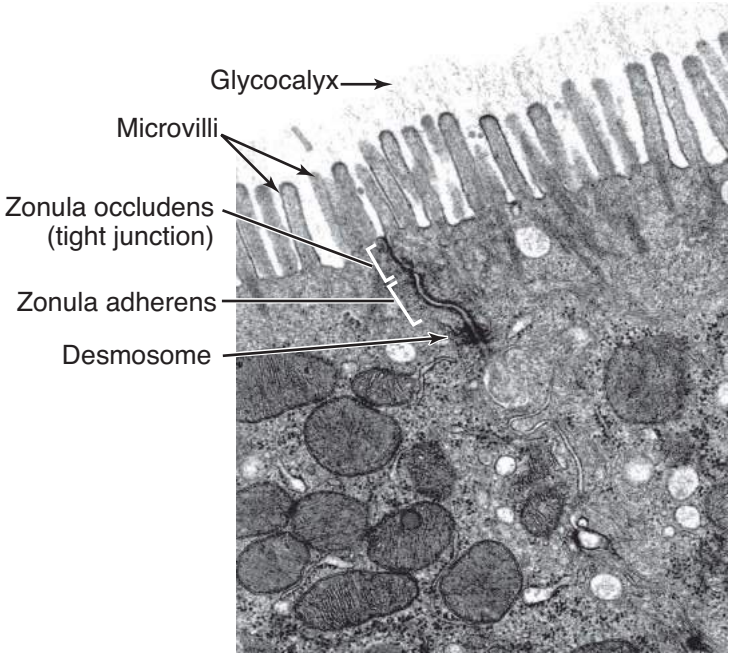

Figure I-3-12. Apical Cell Surface/Cell Junctions

Cilia

Cilia contain 9 peripheral pairs of microtubules and 2 central microtubules. The microtubules convey motility to cilia through the ATPase dynein. Cilia bend and beat on the cell surface of pseudostratified ciliated columnar respiratory epithelial cells to propel overlying mucous. They also form the core of the flagella, the motile tail of sperm cells.

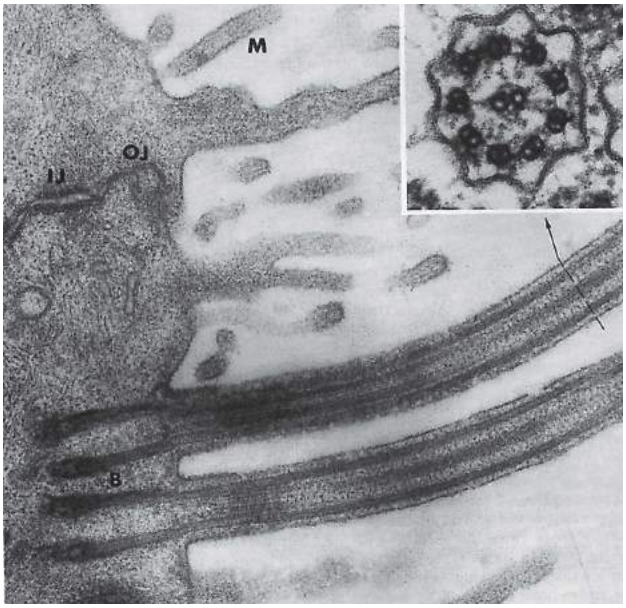

Copyright Lippincott Williams & Wilkins. Used with permission.

Figure I-3-13. Cilia

B: basal body
IJ: intermediate junction
M: microvillus
OJ: occluding junction

Clinical Correlate

Kartagener syndrome is characterized by immotile spermatozoa and infertility. It is due to an absence of dynein that is required for flagellar motility. It is usually associated with chronic respiratory infections because of similar defects in cilia of respiratory epithelium.

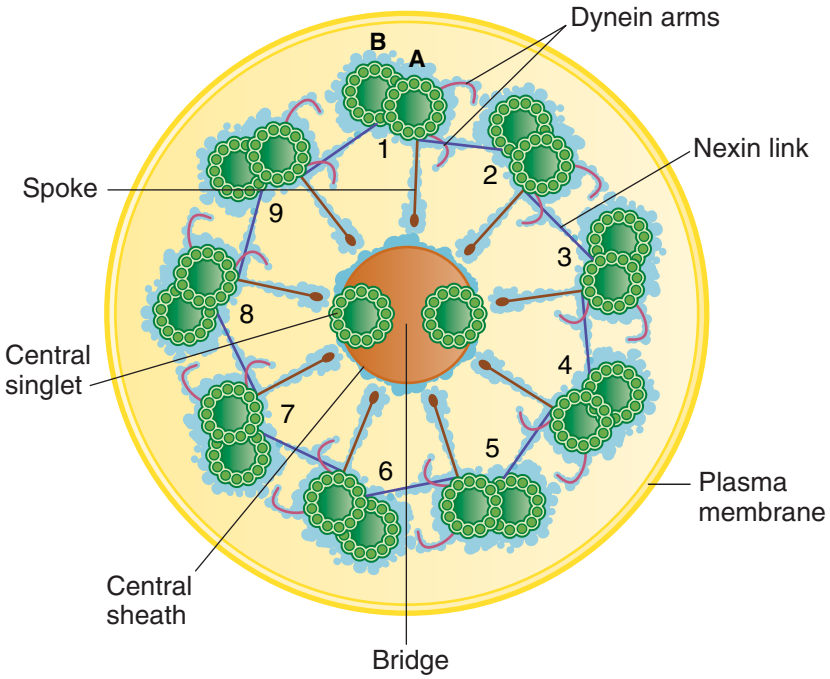

Figure I-3-14. Structure of the Axoneme of a Cilium

PART II

Gross Anatomy

Back and Autonomic Nervous System 1

Learning Objectives

- ❑ Solve problems concerning vertebral column
- ❑ Demonstrate understanding of spinal meninges
- ❑ Use knowledge of spinal nerves
- ❑ Use knowledge of autonomic nervous system

VERTEBRAL COLUMN

Embryology

During week 4, **sclerotome** cells of the somites (mesoderm) migrate medially to surround the spinal cord and notochord. After proliferation of the caudal portion of the sclerotomes, the vertebrae are formed, each consisting of the caudal part of one sclerotome and the cephalic part of the next.

Vertebrae

The vertebral column is the central component of the axial skeleton which functions in muscle attachments, movements, and articulations of the head and trunk.

- The vertebrae provide a flexible support system that transfers the weight of the body to the lower limbs and also provides protection for the spinal cord.
- The vertebral column is composed of 32–33 vertebrae (7 cervical, 12 thoracic, 5 lumbar, and the fused 5 sacral, and 3–4 coccygeal), intervertebral disks, synovial articulations (zygapophyseal joints) and ligaments.

~33 vertebrae

31 spinal nerves

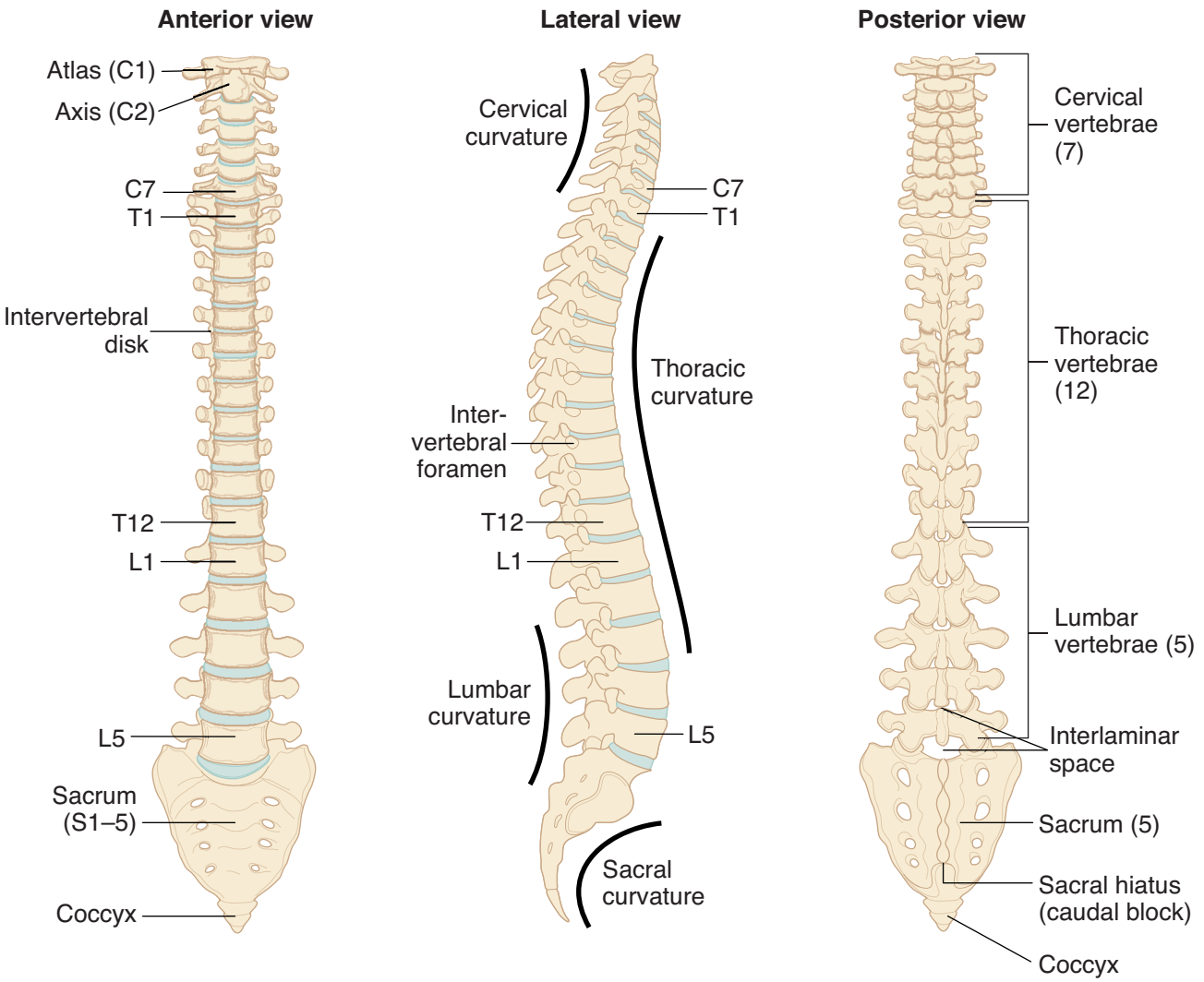

Figure II-1-1. Vertebral Column

A **typical vertebra** consists of an anterior **body** and a posterior **vertebral arch** consisting of 2 **pedicles** and 2 **laminae**. The vertebral arch encloses the **vertebral (foramen) canal** that houses the spinal cord. **Vertebral notches** of adjacent pedicles form **intervertebral foramina** that provide for the exit of the spinal nerves. The dorsal projecting **spines** and the lateral projecting **transverse processes** provide attachment sites for muscles and ligaments.

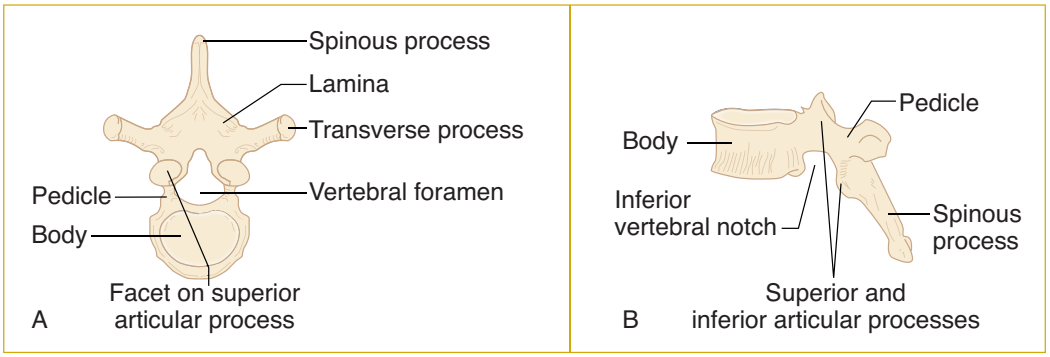

Figure II-1-2. Typical Vertebra

Intervertebral Disks

The **intervertebral disks** contribute to about 25% of the length of the vertebral column. They form the cartilaginous joints between the vertebral bodies and provide limited movements between the individual vertebrae.

- Each intervertebral disk is numbered by the vertebral body **above** the disk.
- Each intervertebral disk is composed of the following:
  - **Anulus fibrosus** consists of the outer concentric rings of fibrocartilage and fibrous connective tissue. The anuli connect the adjacent bodies and provide limited movement between the individual vertebrae.
  - **Nucleus pulposus** is an inner soft, elastic, compressible material that functions as a shock absorber for external forces placed on the vertebral column. The nucleus pulposus is the postnatal remnant of the **notochord.**

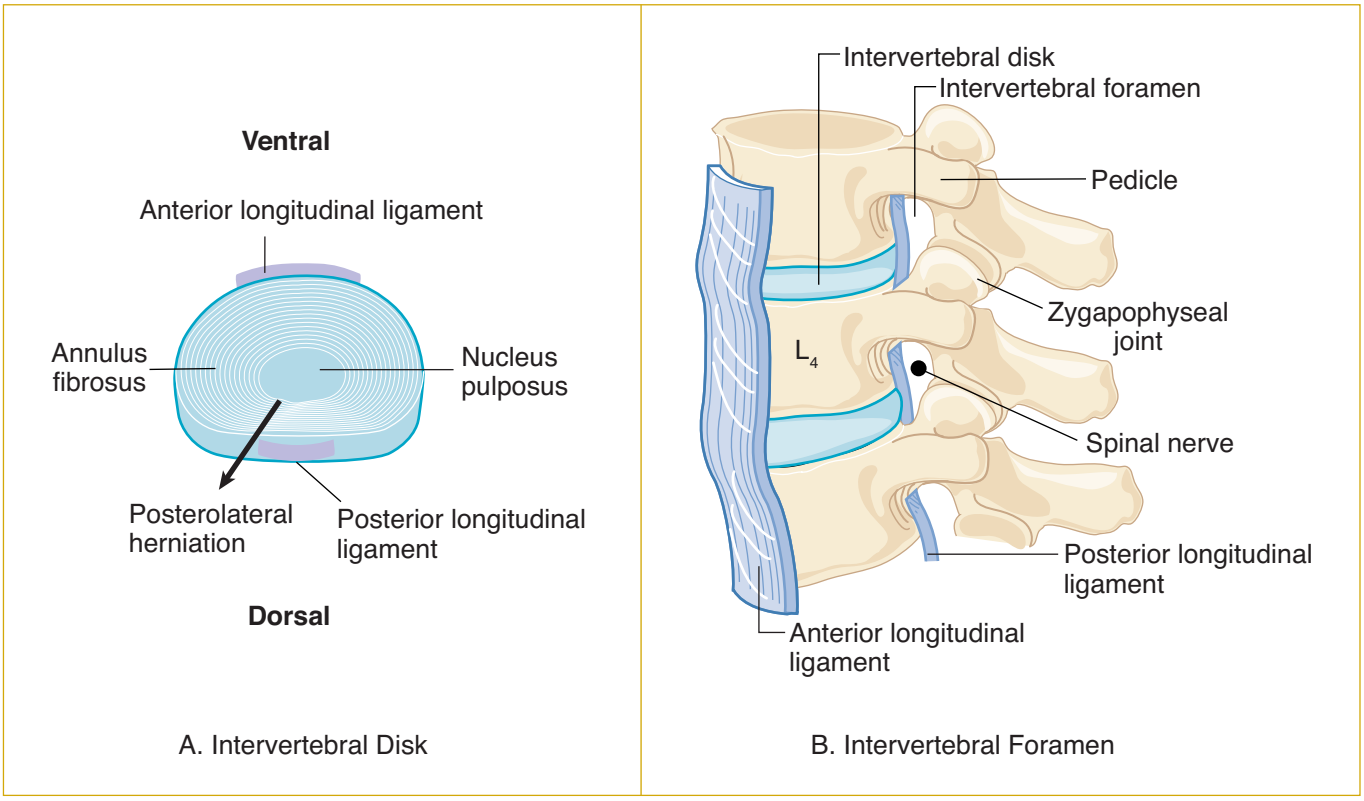

Figure II-1-3. Intervertebral Disks

Clinical Correlate

The herniation of a nucleus pulposus is most commonly in a **posterolateral** direction due to the strength and position of the posterior longitudinal ligament (Figure II-1-3-A).

Ligaments of the Vertebral Column

The vertebral bodies are strongly supported by 2 longitudinal ligaments. Both ligaments are firmly attached to the intervertebral disks and to the bodies of the vertebrae.

- **Anterior longitudinal ligament** forms a broad band of fibers that connects the anterior surfaces of the bodies of the vertebrae between the cervical and sacral regions. It prevents **hyperextension** of the vertebrae and is often involved in "whiplash" accidents.
- **Posterior longitudinal ligament** connects the posterior surfaces of the vertebral bodies and is located in the vertebral canal. It limits **flexion** of the vertebral column. This ligament causes the herniation of a disk to be positioned **posterolaterally**.

Herniated Disk

The **nucleus pulposus** may herniate through the **anulus fibrosus**. The herniated nucleus pulposus may compress the spinal nerve roots, resulting in pain along the involved spinal nerve (sciatica).

- Herniation usually occurs in the lower lumbar (L4/L5 or L5/S1) or lower cervical (C5/C6 or C6/C7) parts of the vertebral column.
- The herniated disk will usually compress the spinal nerve roots **one number below** the involved disk (e.g., the herniation of the L4 disk will compress the L5 roots, or herniation of the C7 disk will compress the C8 nerve roots).

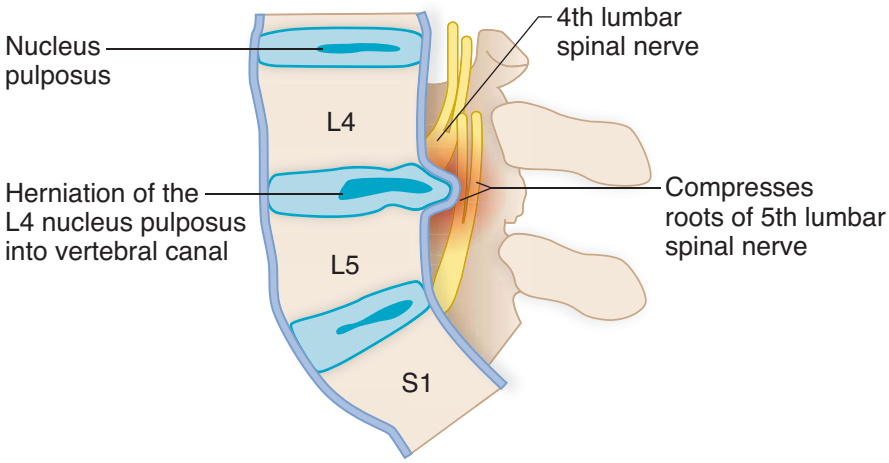

Figure II-1-4. Herniated Intervertebral Disk

Intervertebral Foramen

The intervertebral foramina are formed by successive intervertebral notches and provide for the passage of the **spinal nerve**. The boundaries of the foramina are:

- **Anterior: bodies** of the vertebrae and **intervertebral disks**
- **Posterior: zygapophyseal joint** and **articular processes**
- **Superior and inferior: pedicles** of the vertebrae

SPINAL MENINGES

The spinal cord is protected and covered by 3 connective tissue layers within the vertebral canal: the dura mater, arachnoid, and pia mater.

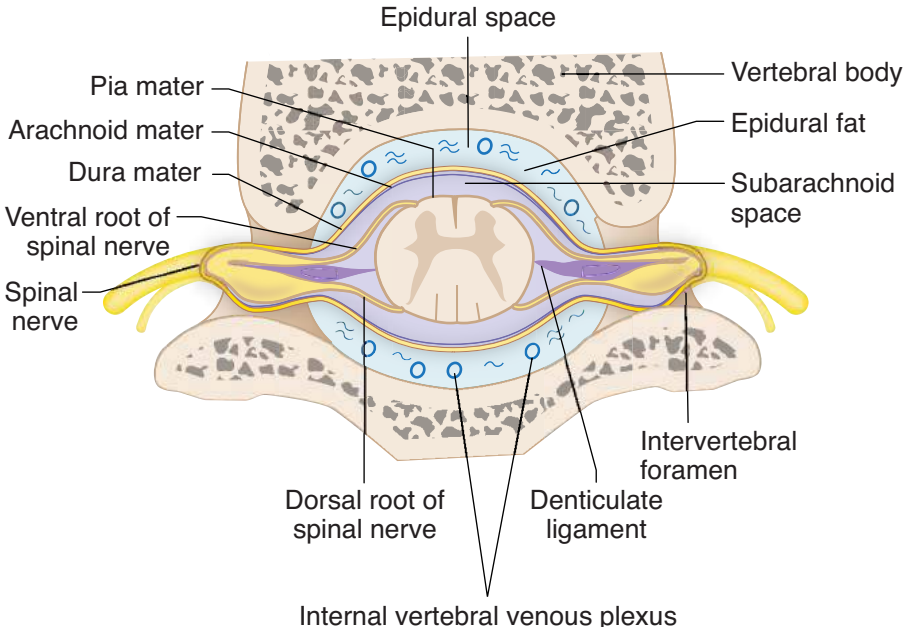

Figure II-1-5. Cross-Section of Vertebral Canal

Dura Mater

The **dura mater** is a tough, cylindrical covering of connective tissue forming a **dural sac** which envelops the entire spinal cord and cauda equina.

- The dura mater and dural sac terminate inferiorly at the **second sacral vertebra level**.
- Superiorly, the dura mater continues through the foramen magnum and is continuous with the meningeal layer of the cranial dura.

Arachnoid

The **arachnoid** is a delicate membrane which completely lines the inner surface of the dura mater and dural sac. It continues inferiorly and terminates at the **second sacral vertebra**.

Pia Mater

The **pia mater** is tightly attached to the surface of the spinal cord and provides a delicate covering of the cord.

- The spinal cord, with its covering of pia mater, terminates at the **L1 or L2 vertebral levels** in the adult.
- There are 2 specializations of the pia mater that are attached to the spinal cord:
  - The **denticulate ligaments** are bilateral thickenings of pia mater that run continuously on the lateral sides of the midpoint of the cord. They separate the ventral and dorsal roots of the spinal nerves and anchor to the dura mater.

– The **filum terminale** is a continuation of the pia mater distal to the lower end of the spinal cord. The filum terminale is part of the **cauda equina** which is composed of ventral and dorsal roots of lumbar and sacral nerves that extend below the inferior limit of the spinal cord.

There are 2 spaces related to the meninges. The **epidural space** is located between the inner walls of the vertebral canal and the dura mater. It contains fat and the **internal vertebral venous plexus.** The venous plexus runs the entire length of the epidural space and continues superiorly through the foramen magnum to connect with dural venous sinuses in the cranial cavity.

The **subarachnoid space** is a pressurized space located between the arachnoid and pia mater layers. It contains **cerebrospinal fluid (CSF)**, which bathes the spinal cord and spinal nerve roots within the dural sac, and terminates at the **second sacral vertebral level**.

There are 2 important vertebral levels. The **L1** or **L2 vertebrae** is the inferior limit of the **spinal cord** in adults (**conus medullaris**). **S2** vertebra is the inferior limit of the **dural sac** and the **subarachnoid** space (cerebrospinal fluid).

Clinical Correlate

The internal vertebral venous plexus is valveless and connects with veins of the pelvis, abdomen, and thorax. It provides a route of metastasis of cancer cells to the vertebral column and the cranial cavity.

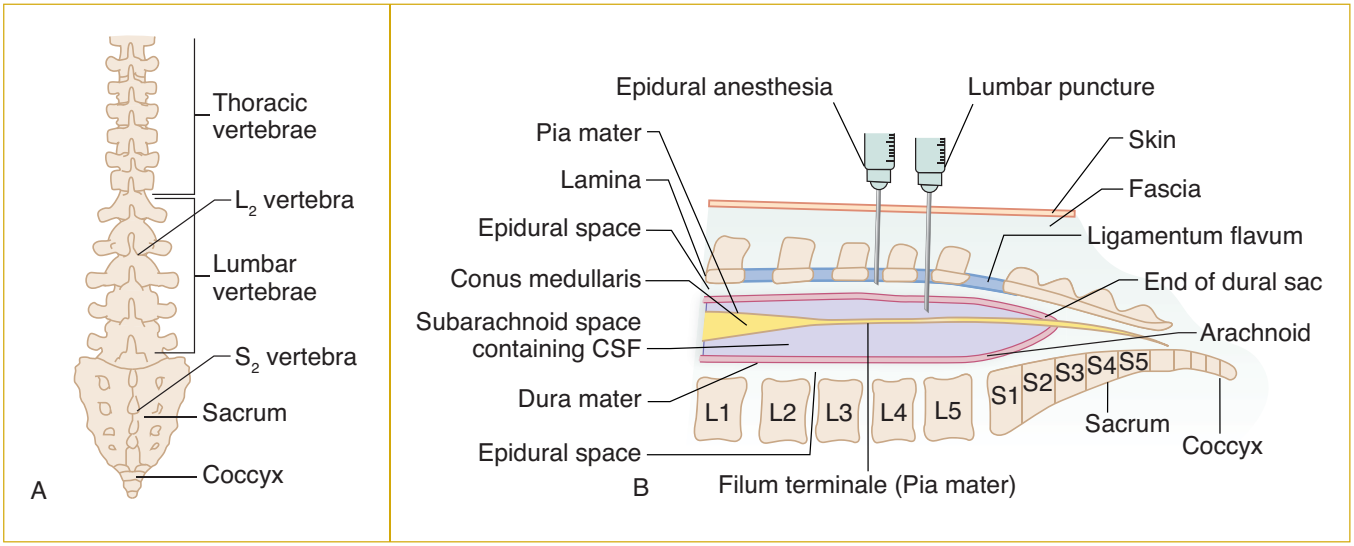

Figure II-1-6. Important Vertebral Levels

SPINAL NERVES

There are 31 pairs of **spinal nerves** attached to each segment of the spinal cord: 8 cervical, 12 thoracic, 5 lumbar, 5 sacral, and 1 coccygeal. The spinal nerves with the cranial nerves form part of the **peripheral nervous system**.

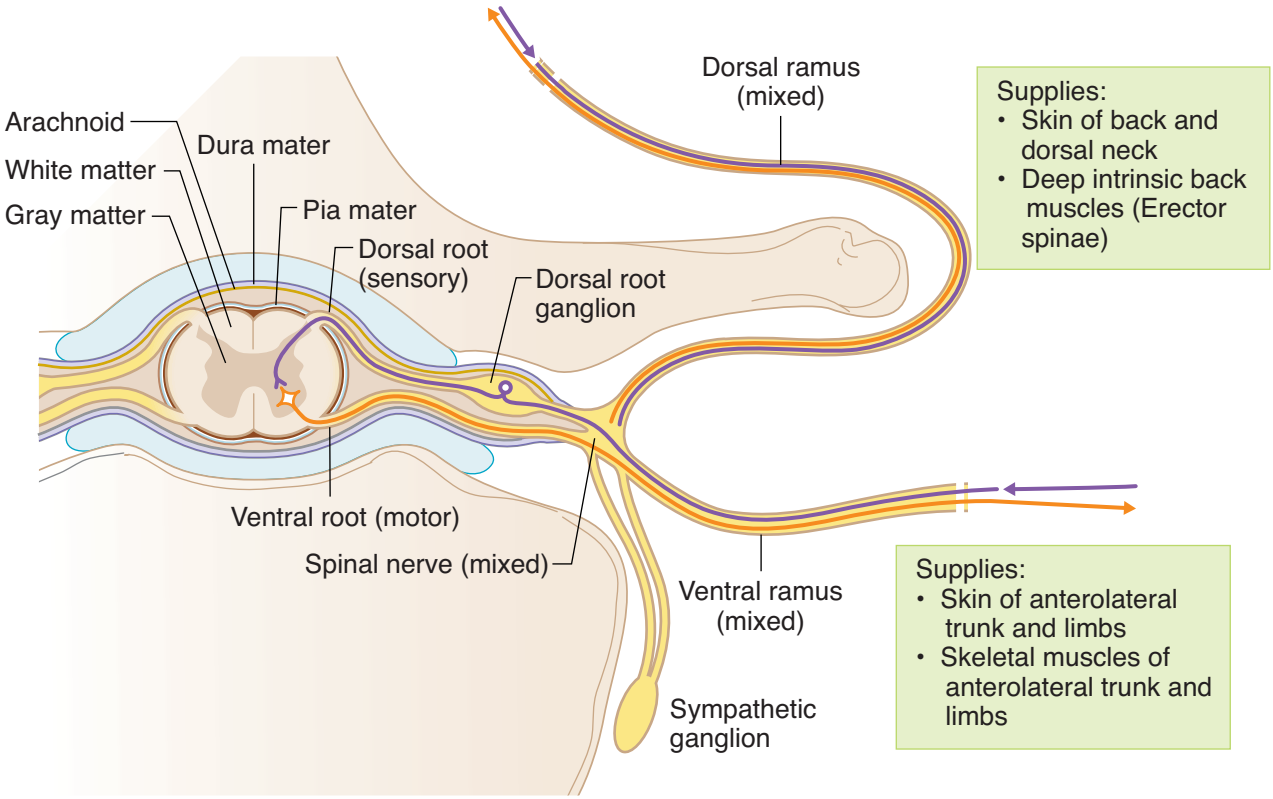

Figure II-1-7. Cross Section of Spinal Cord and Parts of Spinal Nerve

Each spinal nerve is formed by the following components:

- **Dorsal root** carries **sensory** fibers from the periphery into the dorsal aspect of the spinal cord; on each dorsal root there is a **dorsal root ganglion** (sensory) containing the pseudounipolar cell bodies of the nerve fibers that are found in the dorsal root
- **Ventral root** arises from the ventral aspect of the spinal cord and carries axons of **motor** neurons from the spinal cord to the periphery; the cell bodies of the axons in the ventral root are located in the ventral or lateral horns of the spinal cord gray matter
- **Spinal nerve** is formed by the union of the ventral and dorsal roots; it exits the vertebral column by passing through the intervertebral foramen
- **Dorsal rami** innervate the skin of the dorsal surface of the back, neck, zygapophyseal joints, and intrinsic skeletal muscles of the deep back
- **Ventral rami** innervate the skin of the anterolateral trunk and limbs, and the skeletal muscles of the anterolateral trunk and limbs (ventral rami form the brachial and lumbosacral plexuses)

The spinal nerves exit the vertebral column by a **specific relationship to the vertebrae**. The cervical nerves C1–C7 exit the intervertebral foramina **superior** to the pedicles of the same-numbered vertebrae. The C8 nerve exits the intervertebral foramen **inferior** to the C7 pedicle. This is the **transition point**. All nerves beginning with T1 and below will exit the intervertebral foramina **inferior** to the pedicle of the same-numbered vertebrae.

Lumbar Puncture

A **lumbar puncture** is used to inject anesthetic material in the epidural space or to withdraw CSF from the subarachnoid space.

- A spinal tap is typically performed at the **L4-L5 interspace**.
- A horizontal line drawn at the **top of the iliac crest** marks the level of the L4 vertebra.
- When a lumbar puncture is performed in the midline, the needle passes through the **interlaminar space** of the vertebral column found between the laminae of the lumbar vertebrae.
- The interlaminar spaces are covered by the highly elastic **ligamenta flava**.

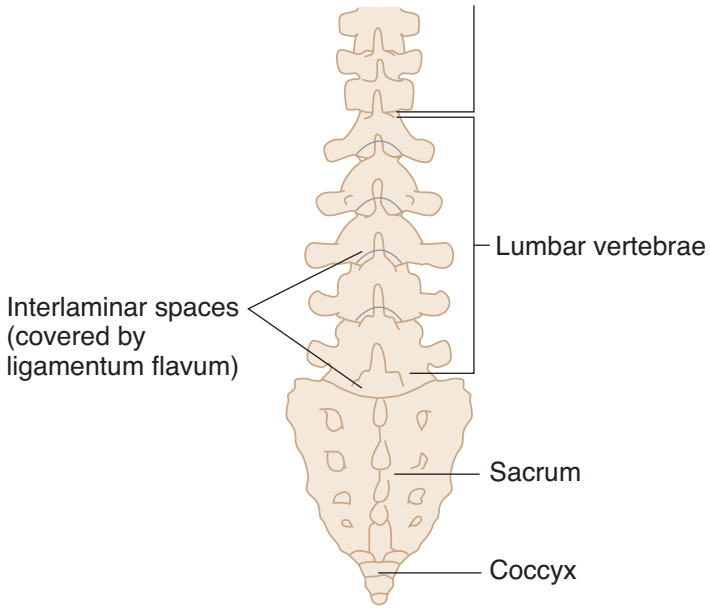

Figure II-1-8. Interlaminar Spaces

Clinical Correlate

During a lumbar puncture, a needle is passed through the interlaminar space while the vertebral column is flexed. The needle passes through the following layers:

- Skin
- Superficial fascia
- Deep fascia
- Supraspinous ligament
- Interspinous ligament
- Interlaminar space
- Epidural space
- Dura
- Arachnoid
- Subarachnoid space

AUTONOMIC NERVOUS SYSTEM

The autonomic nervous system (ANS) is concerned with the motor innervation of smooth muscle, cardiac muscle, and glands of the body. Anatomically and functionally, it is composed of 2 motor divisions: **sympathetic** and **parasympathetic**. In both divisions, 2 neurons form an autonomic pathway.

- **Preganglionic neurons have** their neuronal cell bodies in the **CNS** (formed by neuroectoderm); their axons exit in cranial and spinal nerves.
- **Postganglionic neurons have** cell bodies in **autonomic ganglia** in the **peripheral nervous system** (PNS) (formed by neural crest cells)

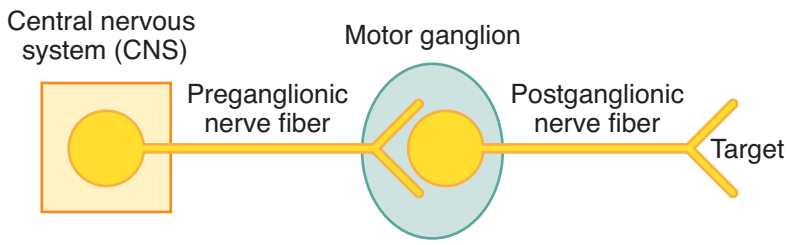

Figure II-1-9. Autonomic Nervous System

Sympathetic Nervous System

The **preganglionic cell bodies** of the sympathetic nervous system are found in the **lateral horn** gray matter of spinal cord segments **T1–L2** (14 segments).

The **postganglionic cell bodies** of the sympathetic system are found in one of 2 types of motor ganglia in the PNS:

- **Chain or paravertebral**
- **Collateral or prevertebral** (found only in abdomen or pelvis)

Table II-1-1. Sympathetic = Thoracolumbar Outflow

Origin (Preganglionic)	Site of Synapse (Postganglionic)	Innervation (Target)
Spinal cord levels T1–L2	Sympathetic chain ganglia (paravertebral ganglia)	Smooth muscle, cardiac muscle and glands of **body wall** and **limbs** (T1–L2), **head** (T1–2) and **thoracic viscera** (T1–5).
Thoracic splanchnic nerves T5–T12	Prevertebral ganglia (collateral) (e.g., celiac, aorticorenal, superior mesenteric ganglia)	Smooth muscle and glands of the **foregut** and **midgut**
Lumbar splanchnic nerves L1–L2	Prevertebral ganglia (collateral) (e.g., inferior mesenteric and pelvic ganglia)	Smooth muscle and glands of the **pelvic viscera** and **hindgut**

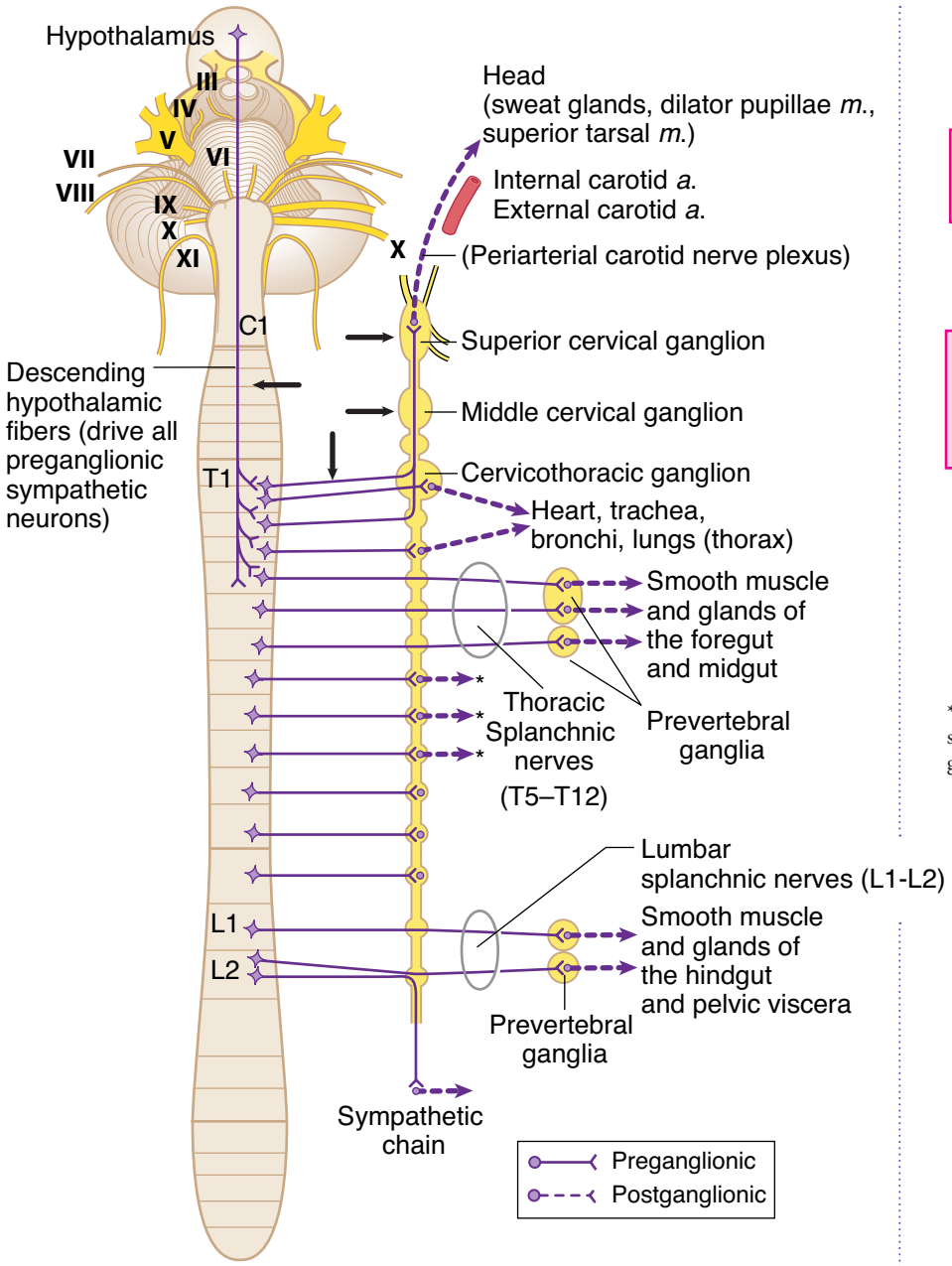

Figure II-1-10. Overview of Sympathetic Outflow

m: muscle
a: artery

Lesions at arrows result in ipsilateral Horner syndrome (ptosis, miosis, and anhydrosis).

*Gray rami carry postganglionic sympathetic axons from the sympathetic ganglion to the spinal nerve.

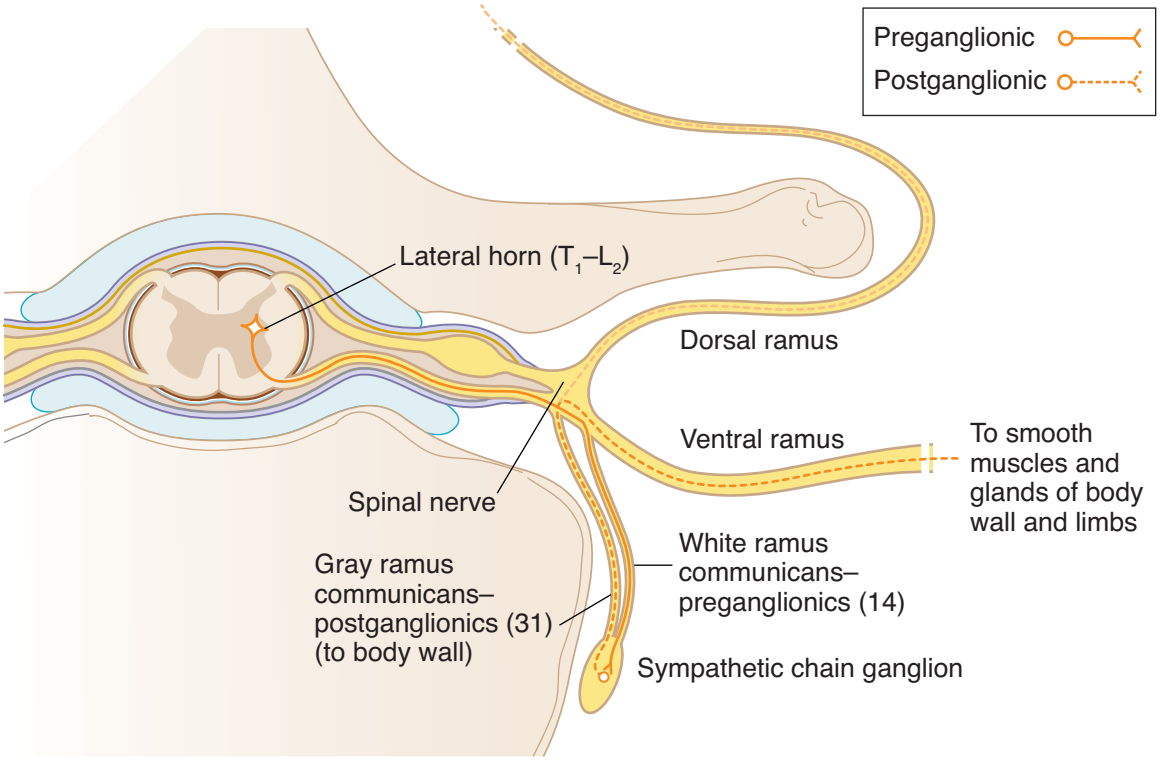

Figure II-1-11. Cross Section of Spinal Cord Showing Sympathetic Outflow

Note

White rami are preganglionic sympathetics that all enter the sympathetic trunk of ganglia. They may synapse with ganglion at point of entry or go up or down and synapse above or below point of entry. If a white ramus does not synapse, it passes through ganglion and becomes a root of a thoracic or lumbar splanchnic nerve.

Parasympathetic Nervous System

The **preganglionic cell bodies** of the parasympathetic nervous system are found in the **CNS** in one of 2 places:

- Gray matter of brain stem associated with **cranial nerves III, VII, IX, and X,** or
- Spinal cord gray in **sacral segments S2 3, and 4 (pelvic splanchnics)**

The **postganglionic cell bodies** of the parasympathetic nervous system are found in **terminal ganglia** in the PNS that are usually located near the organ innervated or in the wall of the organ.

Table II-1-2. Parasympathetic = Craniosacral Outflow

Origin (Preganglionic)	Site of Synapse (Postganglionic)	Innervation (Target)
Cranial nerves III, VII, IX	4 cranial ganglia	Glands and smooth muscle of the **head**
Cranial nerve X	Terminal ganglia (in or near the walls of viscera)	Viscera of the neck, **thorax, foregut,** and **midgut**
Pelvic splanchnic nerves S 2, 3, 4	Terminal ganglia (in or near the walls of viscera)	**Hindgut** and **pelvic viscera** (including the bladder, rectum, and erectile tissue)

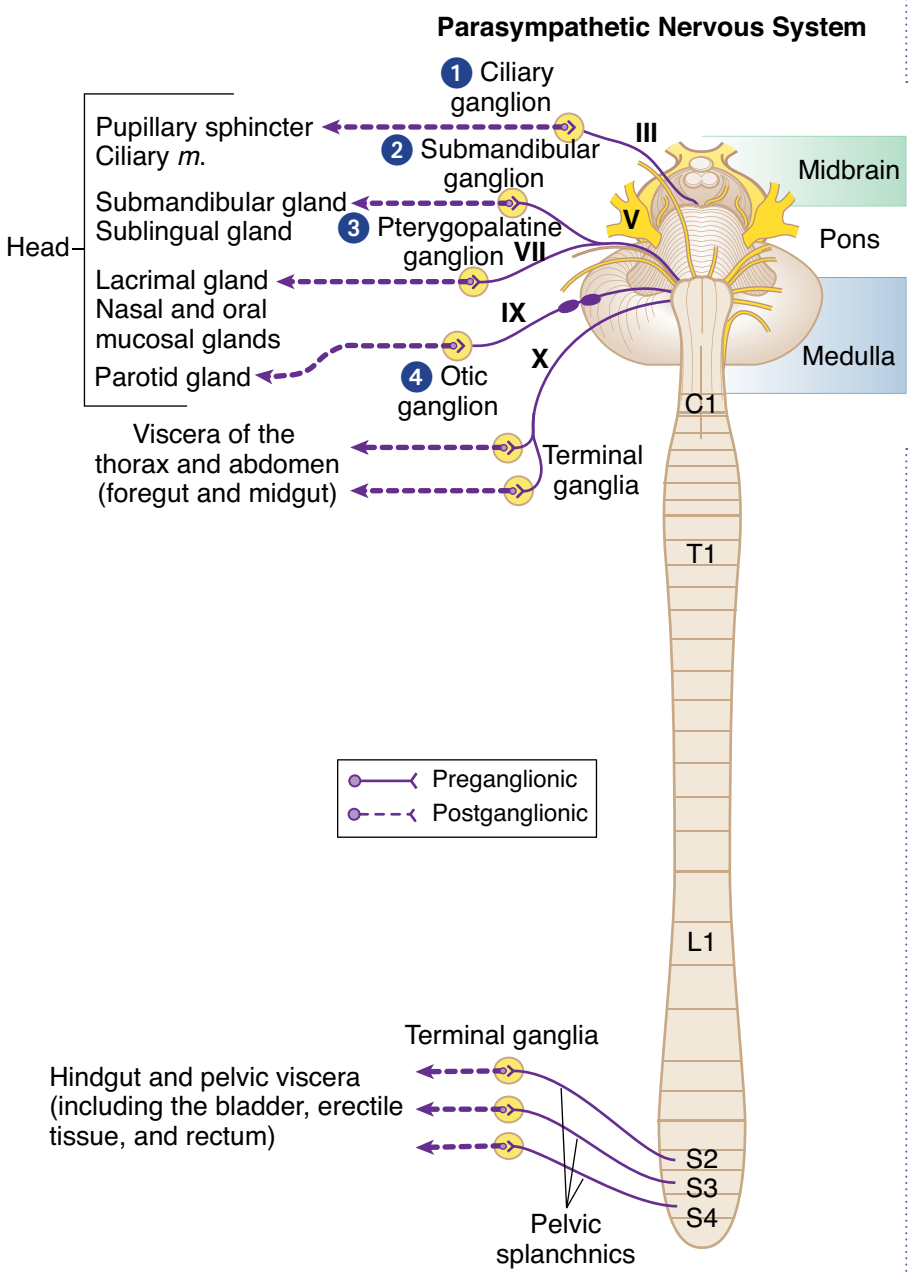

Figure II-1-12. Overview of Parasympathetic Outflow

Thorax 2

Learning Objectives

- ❑ Solve problems concerning the chest wall
- ❑ Use knowledge of embryology of lower respiratory system
- ❑ Use knowledge of pleura and pleural cavity
- ❑ Interpret scenarios on respiratory histology
- ❑ Use knowledge of alveolar ducts, alveolar sacs, and the alveoli
- ❑ Answer questions about embryology of the heart
- ❑ Solve problems concerning the mediastinum
- ❑ Interpret scenarios on heart histology
- ❑ Solve problems concerning the diaphragm

CHEST WALL

Breast

The breast (mammary gland) is a subcutaneous glandular organ of the superficial pectoral region. It is a modified sweat gland, specialized in women for the production and secretion of milk. A variable amount of fat surrounds the glandular tissue and duct system and is responsible for the shape and size of the female breast.

- **Cooper ligaments** are suspensory ligaments that attach the mammary gland to the skin and run from the skin to the deep fascia.
- There is an extensive **blood supply** to the mammary tissues. The 2 prominent blood supplies are:
  - **Internal thoracic artery (internal mammary)**, a branch of the subclavian artery which supplies medial aspect of the gland
  - **Lateral thoracic artery**, a branch of the axillary artery which contributes to the blood supply to lateral part of the gland; lateral aspect of the chest wall, the lateral thoracic artery courses with the **long thoracic nerve**, superficial to serratus anterior muscle

Clinical Correlate

The presence of a tumor within the breast can distort Cooper ligaments, which results in dimpling of the skin (orange-peel appearance).

Clinical Correlate

During a radical mastectomy, **the long thoracic nerve** (serratus anterior muscle) may be lesioned during ligation of the lateral thoracic artery.
A few weeks after surgery, the patient may present with a **winged scapula** and weakness in abduction of the arm above 90°. The **thoracodorsal nerve** supplying the latissimus dorsi muscle may also be damaged during mastectomy, resulting in weakness in extension and medial rotation of the arm.

- The **lymphatic drainage** of the breast is critical due to its important role in metastasis of breast cancer. The lymphatic drainage of the breast follows 2 primary routes:
  - Laterally, most of the lymphatic flow (75%) drains from the nipple and the superior, lateral, and inferior quadrants of the breast to the **axillary nodes**, initially to the **pectoral group**.
  - From the medial quadrant, most lymph drains to the **parasternal nodes**, which accompany the internal thoracic vessels. It is also through this medial route that cancer can spread to the **opposite breast**.

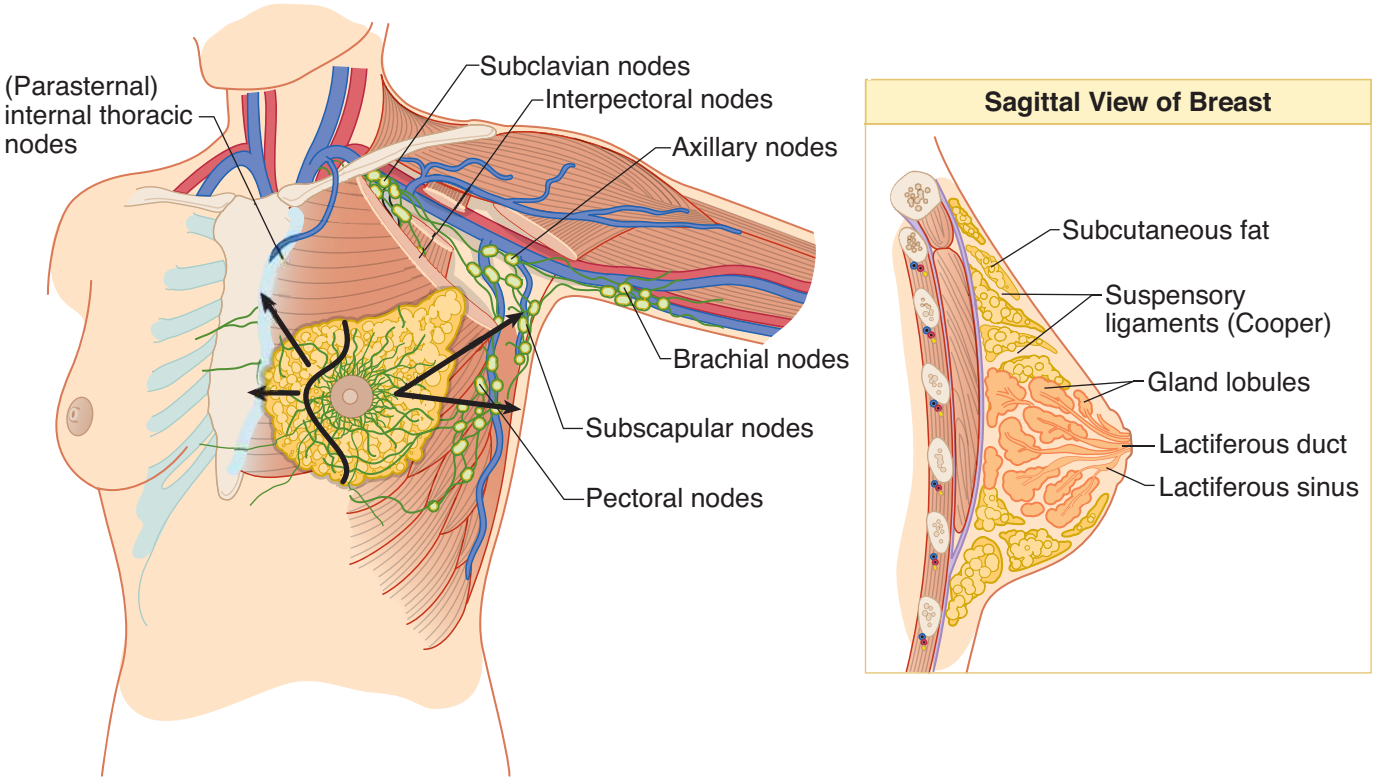

Figure II-2-1. Breast

EMBRYOLOGY OF LOWER RESPIRATORY SYSTEM

During week 4 of development, the lower respiratory system (trachea, bronchi, and lungs) begins to develop as a single **respiratory (laryngotracheal) diverticulum** of endoderm from the ventral wall of the **foregut**. The respiratory epithelium develops from **endoderm** while the muscles, connective tissues, and cartilages develop from **mesoderm**.

- The respiratory diverticulum enlarges distally to form the **lung bud.**
- The diverticulum and lung bud then bifurcate into the 2 **bronchial buds**, which then undergo a series of divisions to form the major part of the bronchial tree (main, secondary, and tertiary bronchi) by month 6.
- The tertiary segmental bronchi are related to the bronchopulmonary segments of the lungs.

- To separate the initial communication with foregut, the **tracheoesophageal septum** forms to separate the esophagus from the trachea.
- A critical time in lung development is the **25–28th** weeks. By this time, the Type I and II pneumocytes are present and gas exchange and surfactant production are possible. Premature fetuses born during this time can survive with intensive care. The amount of surfactant production is critical.

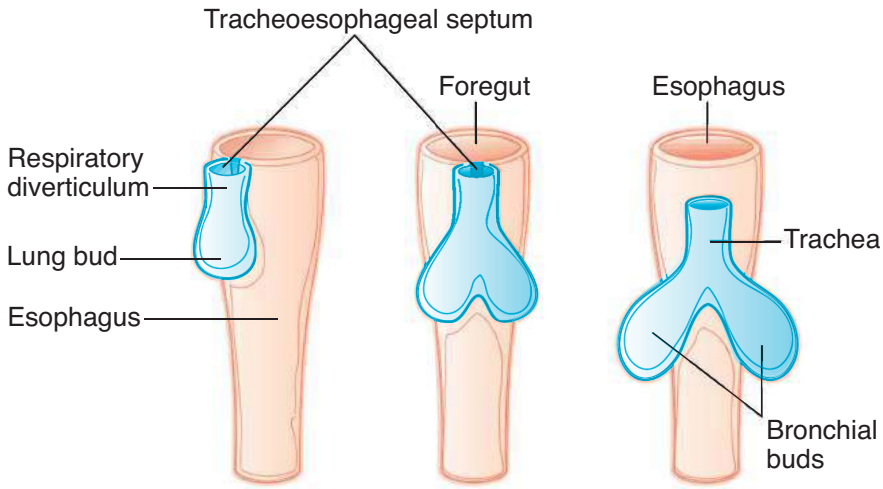

Figure II-2-2. Development of the Lower Respiratory System

A **tracheoesophageal fistula** is an abnormal communication between the trachea and esophagus caused by a malformation of the tracheoesophageal septum. It is generally associated with the following:

- **Esophageal atresia** and **polyhydramnios** (increased volume of amniotic fluid)
- Regurgitation of milk
- Gagging and cyanosis after feeding
- Abdominal distention after crying
- **Reflux** of gastric contents into lungs causing pneumonitis

The fistula is most commonly (90% of cases) located between the esophagus and **distal third of the trachea**.

Clinical Correlate

Pulmonary hypoplasia occurs when lung development is stunted. This condition has 2 congenital causes: (1) **congenital diaphragmatic hernia** (a herniation of abdominal contents into the thorax, which affects the development of the left lung), or (2) **bilateral renal agenesis** (this causes **oligohydramnios**, which increases the pressure on the fetal thorax and Potter's sequence). One of the features of Potter's sequence is bilateral pulmonary hypoplasia.

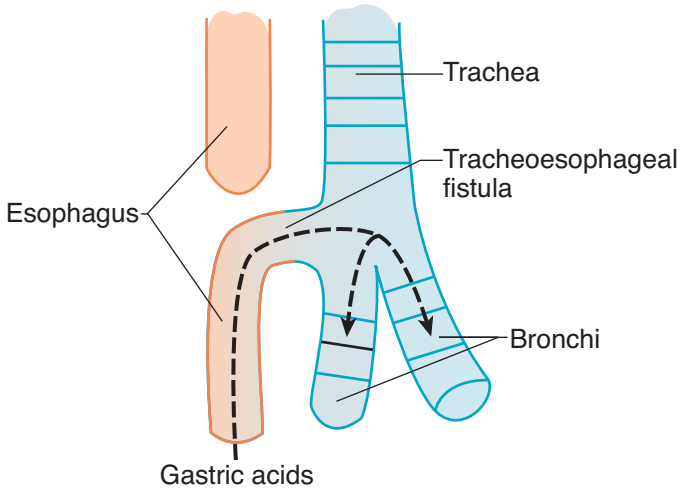

Figure II-2-3. Tracheoesophageal Fistula (Most Common Type)

ADULT THORACIC CAVITY

The **thoracic cavity** is kidney-shaped on cross section and is bounded anterolaterally by the bony thorax (sternum, ribs, and intercostal spaces) and posteriorly by the thoracic vertebrae. Superiorly, the thoracic cavity communicates through the **thoracic inlet** with the base of the neck. (Note, however, that clinically this region is usually called the thoracic outlet.) Inferiorly, the **thoracic outlet** is closed by the diaphragm which separates the thoracic from the abdominal cavity.

The thoracic cavity is divided into 2 **lateral compartments:** the lungs and their covering of serous membranes, and a **central compartment** called the **mediastinum** which contains most of the viscera of the thorax.

Clinical Correlate

Passage of instruments through the intercostal space is done in the **lower part** of the space to avoid the intercostal neurovascular structures (as during a thoracentesis).

An intercostal nerve block is done in the **upper portion** of the intercostal space.

Intercostal Spaces

- There are 11 **intercostal spaces** within the thoracic wall (Figure II-2-4A). The spaces are filled in by 3 layers of intercostal muscles and their related fasciae and are bounded superiorly and inferiorly by the adjacent ribs.
- The **costal groove** is located along the inferior border of each rib (upper aspect of the intercostal space) and provides protection for the intercostal nerve, artery, and vein which are located in the groove. The vein is most superior and the nerve is inferior in the groove (VAN).
- The intercostal arteries are contributed to anteriorly from branches of the internal thoracic artery (branch of the subclavian artery) and posteriorly from branches of the thoracic aorta. Thus, the intercostal arteries can provide a potential collateral circulation between the subclavian artery and the thoracic aorta.

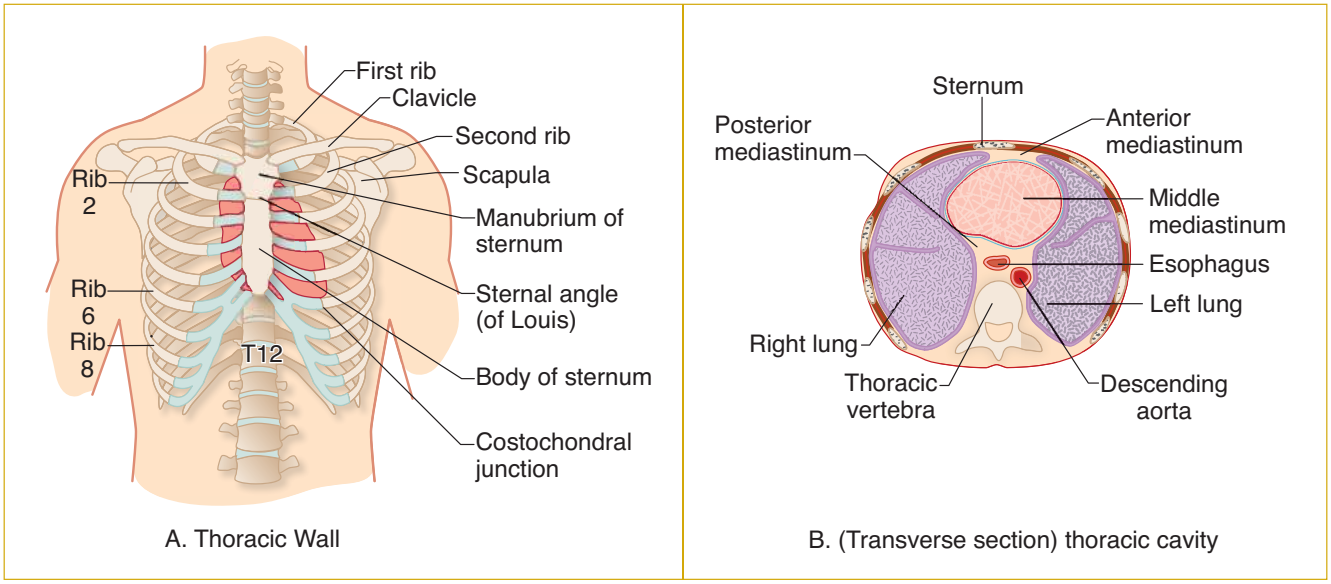

Figure II-2-4. Thoracic Cavity

PLEURA AND PLEURAL CAVITY

Within the thoracic and abdominal cavities there are 3 serous mesodermal-derived membranes which form a covering for the lungs (**pleura**), heart (**pericardium**), and abdominal viscera (**peritoneum**).

Each of these double-layered membranes permits friction-reducing movements of the viscera against adjacent structures.

The outer layer of the serous membranes is referred to as the **parietal layer;** and the inner layer which is applied directly to the surface of the organ is called the **visceral layer**. The 2 layers are continuous and there is a potential space (pleural cavity) between the parietal and visceral layers containing a thin layer of serous fluid.

Pleura

The **pleura** is the serous membrane that invests the lungs in the lateral compartments of the thoracic cavity (Figure II-2-5). The external **parietal pleura** lines and attaches to the inner surfaces of the chest wall, diaphragm, and mediastinum. The innermost **visceral** layer reflects from the parietal layer at the hilum of the lungs and is firmly attached to and follows the contours of the lung. Visceral and parietal pleura are continuous at the root of the lung.

The **parietal pleura** is regionally named by its relationship to the thoracic wall and mediastinum (Figure II-2-5):

- **Costal parietal pleura** is lateral and lines the inner surfaces of the ribs and intercostal spaces
- **Diaphragmatic parietal pleura** lines the thoracic surface of the diaphragm

Clinical Correlate

Respiratory distress syndrome is caused by a deficiency of surfactant (type II pneumocytes). This condition is associated with premature infants, infants of diabetic mothers, and prolonged intrauterine asphyxia. Thyroxine and cortisol treatment increase the production of surfactant.

Surfactant deficiency may lead to **hyaline membrane disease**, whereby repeated gasping inhalations damage the alveolar lining. Hyaline membrane disease is characterized histologically by collapsed alveoli (atelectasis) and eosinophilic (pink) fluid covering the alveoli.

- **Mediastinal parietal pleura** is medial and lines the mediastinum. The mediastinal pleura reflects and becomes continuous with the visceral pleura at the hilum.
- **Cervical parietal pleura** extends into the neck above the first rib where it covers the apex of the lung.

The **visceral pleura** tightly invests the surface of the lungs, following all of the fissures and lobes of the lung.

Clinical Correlate

Inflammation of the parietal pleural layers (**pleurisy**) produces sharp pain upon respiration. Costal inflammation produces local dermatome pain of the chest wall via the intercostal nerves; whereby mediastinal irritation produces referred pain via the phrenic nerve to the shoulder dermatomes of C3–5.

Innervation of Pleura

The **parietal pleura** has extensive **somatic** sensory innervation provided by nerves closely related to different aspects of the pleura.

- The **intercostal nerves** supply the **costal** and peripheral portions of the **diaphragmatic** pleura.
- The **phrenic nerve** supplies the central portion of the **diaphragmatic** pleura and the **mediastinal** pleura.

The **visceral pleura** is supplied by visceral sensory nerves that course with the autonomic nerves.

Clinical Correlate

Open pneumothorax occurs when air enters the pleural cavity following a penetrating wound of the chest cavity. Air moves freely through the wound during inspiration and expiration. During inspiration, air enters the chest wall and the mediastinum will shift toward other side and compress the opposite lung. During expiration, air exits the wound and the mediastinum moves back toward the affected side.

Tension pneumothorax occurs when a piece of tissue covers and forms a flap over the wound. During inspiration, air enters the chest cavity, which results in a shift of the mediastinum toward the other side, compressing the opposite lung. During expiration, the piece of tissue prevents the air from escaping the wound, which increases the pressure and the shift toward the opposite side is enhanced. This severely reduces the opposite lung function and venous return to the heart and can be life-threatening.

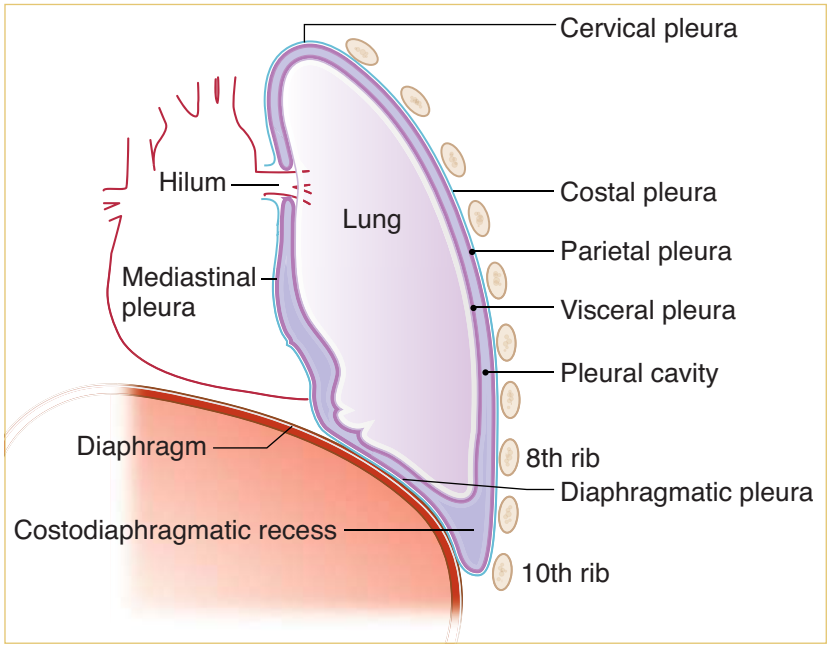

Figure II-2-5. Layers of the Pleura

The **pleural cavity** is the potential space between the parietal and visceral layers of the pleura. It is a closed space which contains a small amount of serous fluid that lubricates the opposing parietal and visceral layers.

The introduction of air into the pleural cavity may cause the lung to collapse, resulting in a **pneumothorax** which causes shortness of breath and painful respiration. The lung collapses due to the loss of the negative pressure of the pleural cavity during a pneumothorax.

Pleural Reflections

Pleural reflections are the areas where the parietal pleura abruptly changes direction from one wall to the other, outlining the extent of the pleural cavities.

- The sternal line of reflection is where the costal pleura is continuous with the mediastinal pleura posterior to the sternum (from costal cartilages 2–4). The pleural margin then passes inferiorly to the level of the sixth costal cartilage.
- Around the chest wall, there are **2 rib interspaces** separating the inferior limit of parietal pleural reflections from the inferior border of the lungs and visceral pleura: between ribs 6–8 in the **midclavicular line**, ribs 8–10 in the **midaxillary line**, and ribs 10–12 at the vertebral column (**paravertebral line**), respectively.

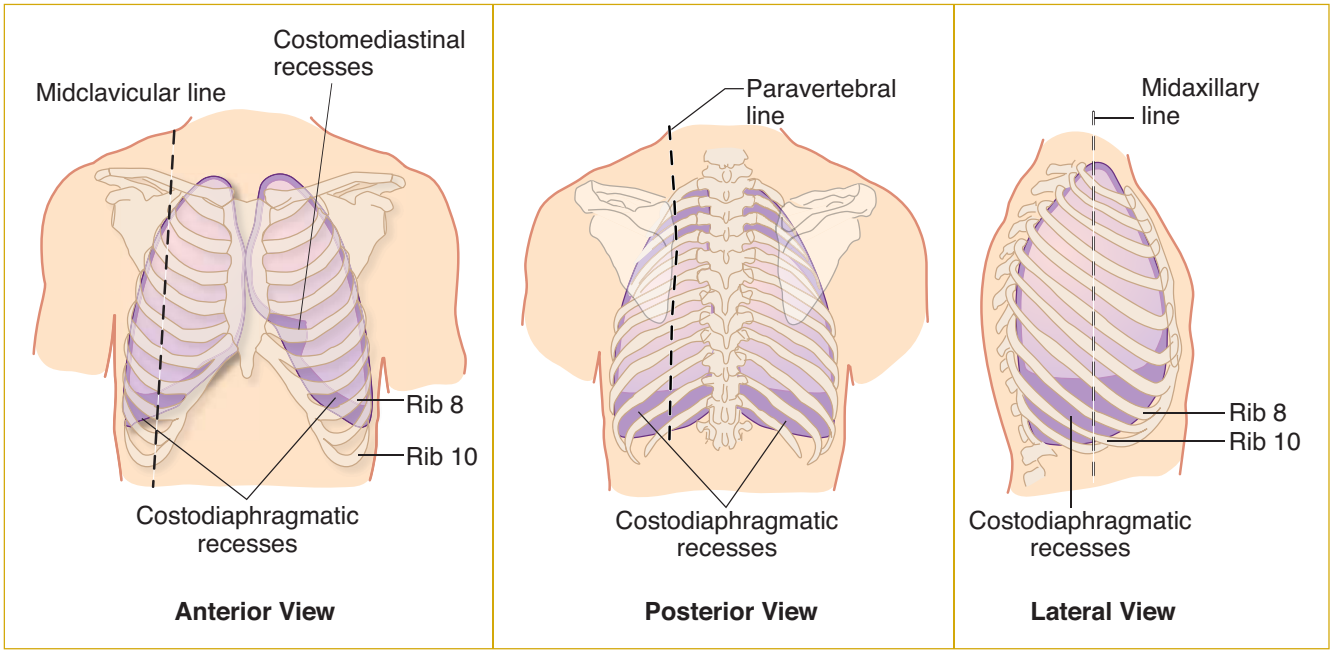

Figure II-2-6. Pleural Reflections and Recesses

Pleural Recesses

Pleural recesses are potential spaces not occupied by lung tissue except during deep inspiration.

- **Costodiaphragmatic recesses** are spaces below the inferior borders of the lungs where costal and diaphragmatic pleura are in contact.
- The **costomediastinal recess** is a space where the left costal and mediastinal parietal pleura meet, leaving a space caused by the cardiac notch of the left lung. This space is occupied by the lingula of the left lung during inspiration.

Note

	Visceral Pleura	Parietal Pleura
Midclavicular line	6th rib	8th rib
Midaxillary line	8th rib	10th rib
Paravertebral line	10th rib	12th rib

LUNGS

The lungs and the pleural membranes are located in the lateral compartment of the thoracic cavity. The lungs are separated from each other in the midline by the mediastinum. The **hilum** of the lung is on the medial surface and serves for passage of structures in the root of the lung: the pulmonary vessels, primary bronchi, nerves, and lymphatics.

Surfaces and Regions

Each lung has 3 surfaces:

- The **costal surface** is smooth and convex and is related laterally to the ribs and tissues of the chest wall.
- The **mediastinal surface** is concave and is related medially to the middle mediastinum and the heart. The mediastinal surfaces contain the **root** of the lung and a deep **cardiac impression**, more pronounced on the left lung.
- The **diaphragmatic surface** (base) is concave and rests on the superior surface of the diaphragm. It is more superior on the right owing to the presence of the liver.

Clinical Correlate

A tumor at the apex of the lung (Pancoast tumor) may result in thoracic outlet syndrome.

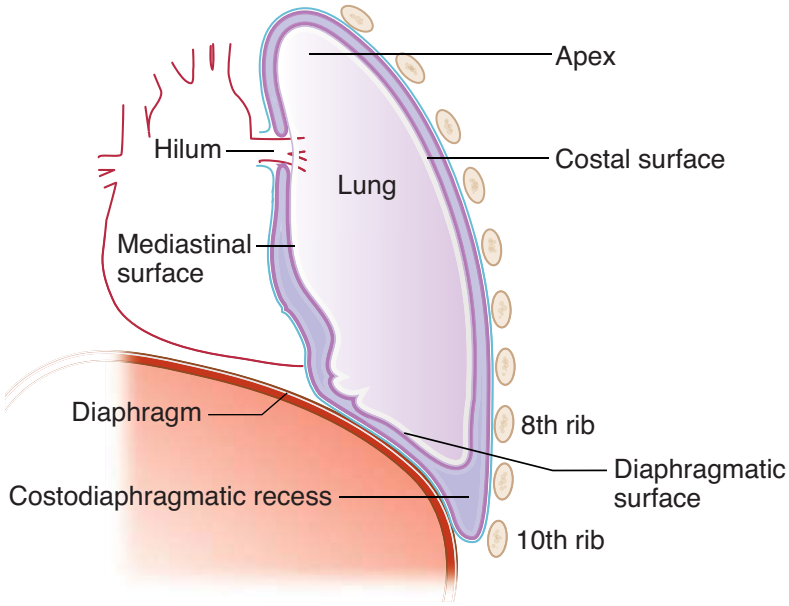

Figure II-2-7. Surfaces of the Lung

The **apex** (cupola) of the lung projects superiorly into the root of the neck above the level of the first rib and is crossed anteriorly by the subclavian artery and vein.

Lobes and Fissures

The **right lung** is divided into 3 lobes (**superior, middle, inferior**) separated by 2 fissures, the **horizontal** and **oblique fissures**. The horizontal fissure separates the superior from the middle lobe and the oblique fissure separates the middle from the inferior lobe.

The **left lung** is divided into 2 lobes (**superior, inferior**) separated by an **oblique fissure**. The **lingula** of the upper lobe of the left lung corresponds to the middle lobe of the right lung.

- The **oblique fissure** of both lungs projects anteriorly at approximately the **5th intercostal space** in the midclavicular line, ending medially deep to the 6th costal cartilage.
- The **horizontal fissure** runs horizontally from the oblique fissure in the **right 5th intercostal space** to the **right 4th costal cartilage**.

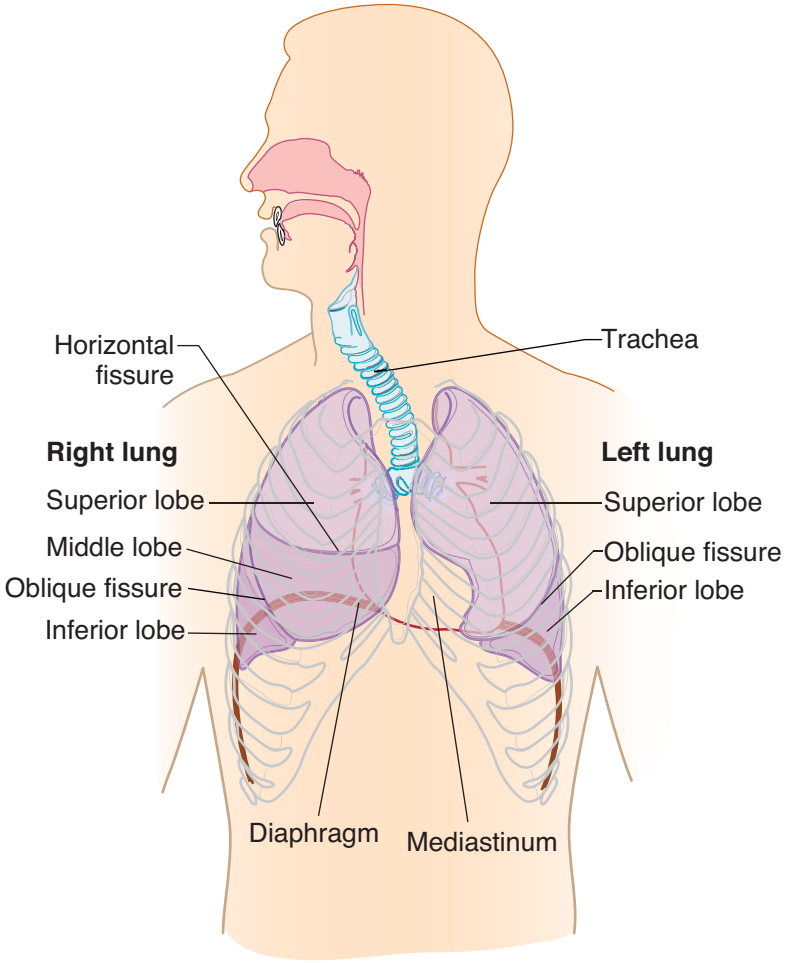

Figure II-2-8. Lobes and Fissures of Lungs

Lymphatic System

The **lymphatic system** consists of an extensive network of lymph capillaries, vessels, and nodes that drain extracellular fluid from most of the body tissues and organs. The lymph flow will return to the blood venous system by 2 major lymphatic vessels, the **right lymphatic duct** and the **thoracic duct** on the left (Figure II-2-10A). These 2 vessels drain into the junction of the internal jugular and the subclavian veins on their respective sides.

Clinical Correlate

The superior lobe of the **right lung** projects anteriorly on the chest wall **above** the **4th rib** and the middle lobe projects anteriorly **below** the 4th rib.

A small portion of the inferior lobe of both lungs projects **below** the 6th rib anteriorly but primarily projects to the **posterior chest** wall.

Clinical Correlate

- To listen to **breath sounds** of the **superior lobes** of the right and left lungs, the stethoscope is placed on the superior area of the anterior chest wall (**above the 4th rib** for the right lung).
- For **breath sounds** from the **middle lobe of the right lung**, the stethoscope is placed on the anterior chest wall **inferior to the 4th rib** and medially toward the sternum.
- For **the inferior lobes** of both lungs**, breath sounds** are primarily heard on the **posterior** chest wall.

Clinical Correlate

Aspiration of a foreign body will more often enter the **right primary bronchus**, which is shorter, wider, and more vertical than the left primary bronchus. When the individual is vertical, the foreign body usually falls into the **posterior basal segment** of the **right inferior lobe**.

- The **thoracic duct** carries all lymphatic drainage from the body below the diaphragm and on the left side of the trunk and head above the diaphragm (Figure II-2-10B).
- **The right lymphatic duct** drains lymph flow from the right head and neck and the right side of the trunk above the diaphragm (Figure II-2-10B).

Lymphatic Drainage

The lymphatic drainage of the lungs is extensive and drains by way of **superficial** and **deep** lymphatic plexuses. The superficial plexus is immediately deep to the visceral pleura. The deep plexus begins deeply in the lungs and drains through **pulmonary nodes** which follow the bronchial tree toward the hilum.

The major nodes involved in the lymphatic drainage of these 2 plexuses are:

- **Bronchopulmonary (hilar) nodes** are located at the hilum of the lungs. They receive lymph drainage from both superficial and deep lymphatic plexuses, and they drain into the tracheobronchial nodes.
- **Tracheobronchial nodes** are located at the bifurcation of the trachea, and they drain into the right and left bronchomediastinal nodes and trunk.
- **Bronchomediastinal nodes** and trunk are located on the right and left sides of the trachea, and they drain superiorly into either the right lymphatic duct or the thoracic duct on the left.

Clinical Correlate

The lymphatic drainage from the **lower lobe of the left lung** also drains across the midline into the **right bronchomediastinal** lymphatic trunk and nodes, then continues along the right pathway to the right lymphatic duct. This is important to consider with metastasis of lung cancer.

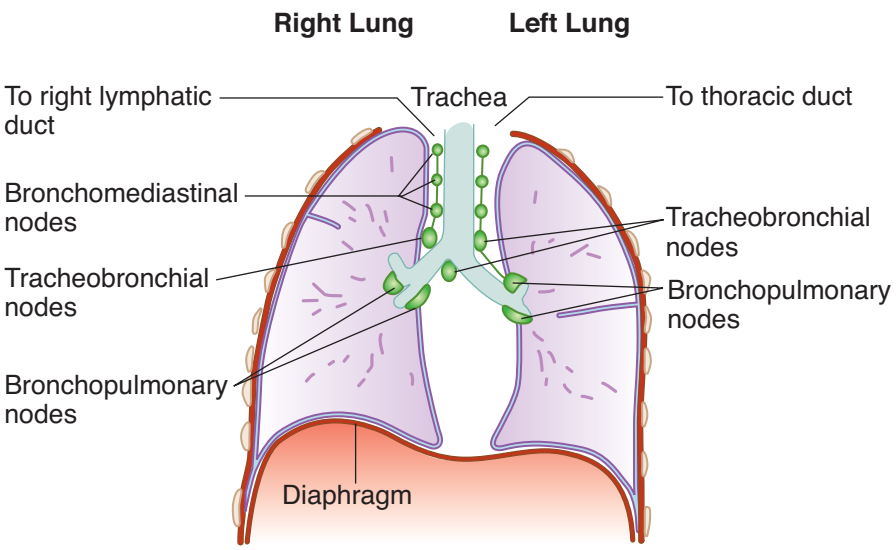

Figure II-2-9. Lymphatics of the Lungs

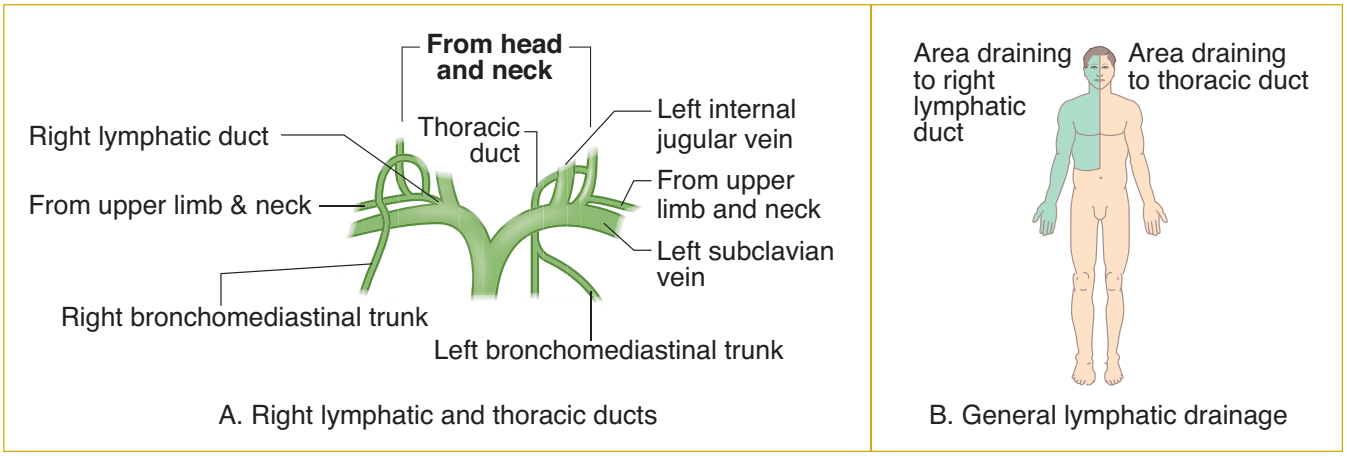

Figure II-2-10. Lymphatic Drainage

RESPIRATORY HISTOLOGY

The lung is an organ that functions in the intake of oxygen and exhaling of CO_2. Approximately 14 times each minute, we take in about 500 mL of air per breath. Inspired air will be spread over 120 square meters of the surface area of the lungs. The air–blood barrier has to be thin enough for air to pass across but tough enough to keep the blood cells inside their capillaries.

Because lungs are opened to the outside world, they are susceptible to environmental insults in the form of pollution and infectious bacteria.

The lungs receive the entire cardiac output and are positioned to modify various blood components. The pulmonary endothelium plays an active role in the metabolic transformation of lipoproteins and prostaglandins. **The enzyme that converts angiotensin I to angiotensin II is produced by the lung endothelial cells.**

Clinical Correlate

Any disease that affects capillaries also affects the extensive capillary bed of the lungs. Bacteria which colonize the lungs may damage the barriers between the alveoli and the capillaries, gaining access to the bloodstream (a common complication of bacterial pneumonia).

- With allergies, smooth-muscle constriction reduces the diameter of air tubes and results in reduced air intake.
- Lung cancers commonly develop from bronchi (smoking, asbestos, and excessive radiation are the main causes).
- Mesothelioma is a malignant tumor of the pleura (causative agent: asbestos dust).

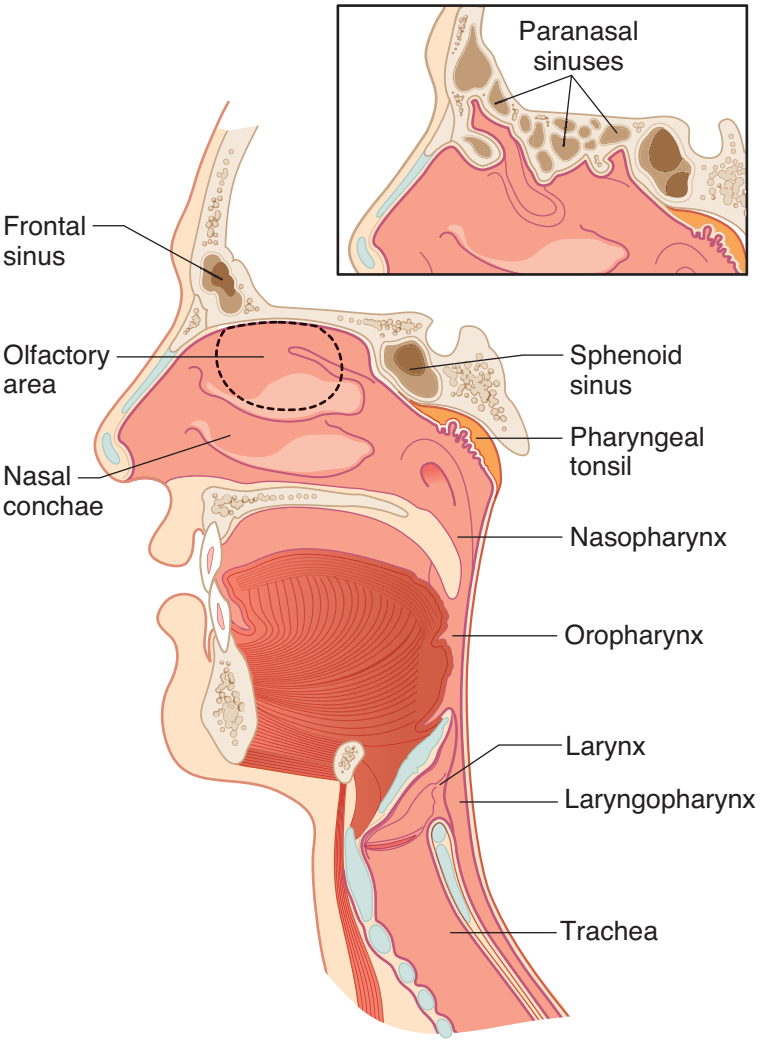

Figure II-2-11. Respiratory Pathways

Table II-2-1. Histologic Features of Trachea, Bronchi, and Bronchioles

	Trachea	Bronchi	Bronchioles
Epithelia	Pseudostratified ciliated columnar (PCC) cells, goblet cells	PCC to simple columnar cells	Ciliated, some goblet cells, Clara cells in terminal bronchioles
Cartilage	16–20 C-shaped cartilaginous rings	Irregular plates	None
Glands	Seromucous glands	Fewer seromucous glands	None
Smooth muscle	Between open ends of C-shaped cartilage	Prominent	Highest proportion of smooth muscle in the bronchial tree
Elastic fibers	Present	Abundant	Abundant

TRACHEA

The **trachea** is a hollow tube, about 10 cm in length (and about 2 cm in diameter), extending from the larynx to its bifurcation at the carina to form a primary bronchus for each lung. The most striking structures of the trachea are the C-shaped hyaline cartilage rings. In the human there are 16–20 of them distributed along the length of the trachea. The rings overlap in the anterior part of the trachea. The free posterior ends of the C-shaped cartilages are interconnected by smooth-muscle cells.

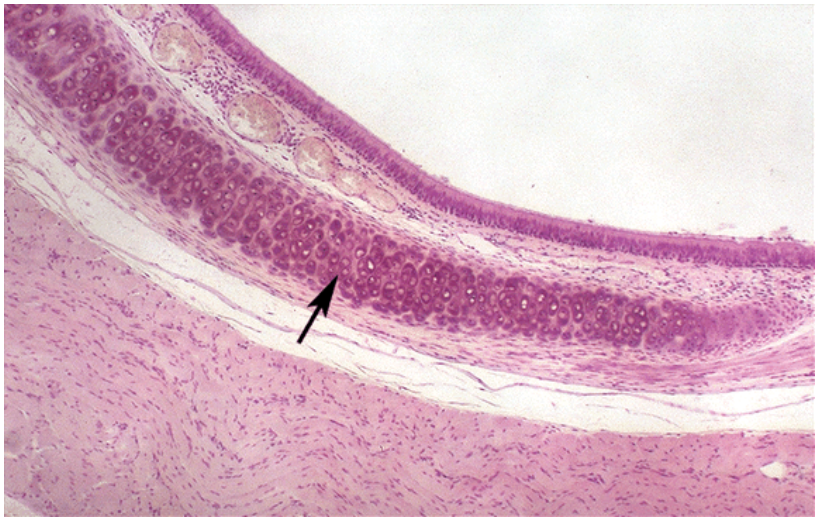

Copyright McGraw-Hill Companies. Used with permission.

Figure II-2-12. Trachea with a hyaline cartilage ring (arrow) and pseudostratified columnar epithelium

The trachea is composed of concentric rings of mucosa, submucosa, an incomplete muscularis, and an complete adventitia.

- The mucosa has 3 components: a pseudostratified epithelium, an underlying vascularized loose connective tissue (lamina propria) that contains immune cells, and a thin layer of smooth-muscle cells (muscularis mucosa).
- The submucosa is a vascular service area containing large blood vessels. Collagen fibers, lymphatic vessels and nerves are also present in this layer.
- The outside covering of the trachea, the adventitia, is composed of several layers of loose connective tissue.

The epithelial lining of the trachea and bronchi is pseudostratified columnar in which all cells lie on the same basal membrane but only some reach the luminal surface. The only other place in the body with this epithelium is the male reproductive tract.

Clinical Correlate

If mucosal clearance is ineffective, or the mechanism overwhelmed, infection (pathogenic bacteria) or pneumoconiosis (dust-related disease) may follow.

In cystic fibrosis, the secreted mucous is thick or viscous and the cilia have a difficult time moving it toward the pharynx. Patients with this disease have frequent infections of the respiratory system.

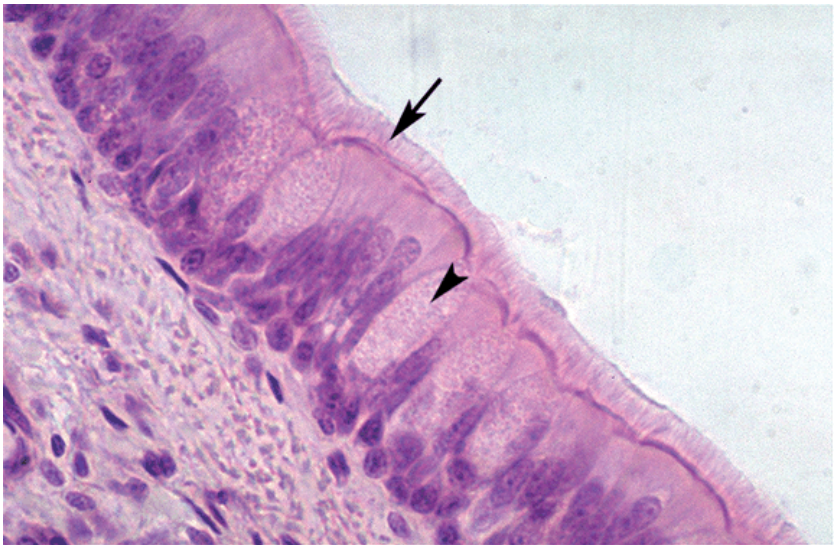

Copyright McGraw-Hill Companies. Used with permission.

Figure II-2-13. Pseudostratified Columnar Epithelium with Goblet Cells (arrowhead) Surrounded by Ciliated Cells (arrow)

Clinical Correlate

Patients lacking dynein have immotile cilia or **Kartagener syndrome**.

With immotile cilia, patients are subject to many respiratory problems because their cilia cannot move this mucous layer with its trapped bacteria. Males also possess immotile sperm.

Tracheal Epithelial Cell Types

Columnar cells extend from the basal membrane to the luminal surface. These cells contain 200–300 apical cilia per cell that are intermingled with microvilli. The cilia are motile and beat to help move the secreted mucous layer over the lining of the trachea and out of the respiratory system.

Goblet cells secrete a polysaccharide mucous material into the lumen of trachea. Mucous production is supplemented by secretions of the submucosal mixed glands. The mucous layer of the respiratory system traps particulate substances (dust, bacteria, and viruses) and absorbs noxious water-soluble gases such as ozone and sulfur dioxide. The mucous sticky layer is moved by the beating cilia toward the pharynx where it is swallowed. This movement is known as the mucociliary escalator system. Most material (dust and bacteria) is trapped in the mucous layer, and is removed and digested.

Pulmonary neuroendocrine (PNE) cells are comparable to the endocrine cells in the gut. These epithelial neuroendocrine cells have been given various names:

- **APUD cells** (**A**mino-**P**recursor-**U**ptake-Decarboxylase), **DNES cells** (**D**iffuse **N**euro **E**ndocrine **S**ystem) and **K** (Kulchitsky) **cells.** These cells occur in clusters and are often located at airway branch points.
- **Brush cells** may represent goblet cells that have secreted their products or intermediate stages in the formation of goblet or the tall ciliated cells. They have short microvilli on their apical surfaces. Some of these cells have synapses with intraepithelial nerves, suggesting that these cells may be sensory receptors.

Basal cells are stem cells for the ciliated and goblet cells. The stem cells lie on the basal membrane but do not extend to the lumen of the trachea. These cells, along with the epithelial neuroendocrine cells, are responsible for the pseudostratified appearance of the trachea.

Clinical Correlate

The columnar and goblet cells are sensitive to irritation. The ciliated cells become taller, and there is an increase in the number of goblet cells and submucosal glands.

Intensive irritation from smoking leads to a squamous metaplasia where the ciliated epithelium becomes a squamous epithelium. This process is reversible.

BRONCHI

The **bronchial tree** forms a branching airway from the trachea to the bronchioles. When the primary bronchi enter the lung, they give rise to 5 secondary or lobar bronchi—3 for the right lung and 2 for the left. The 5 lobes are further subdivided into 10 tertiary or segmental bronchi in each lung, which form bronchopulmonary segments.

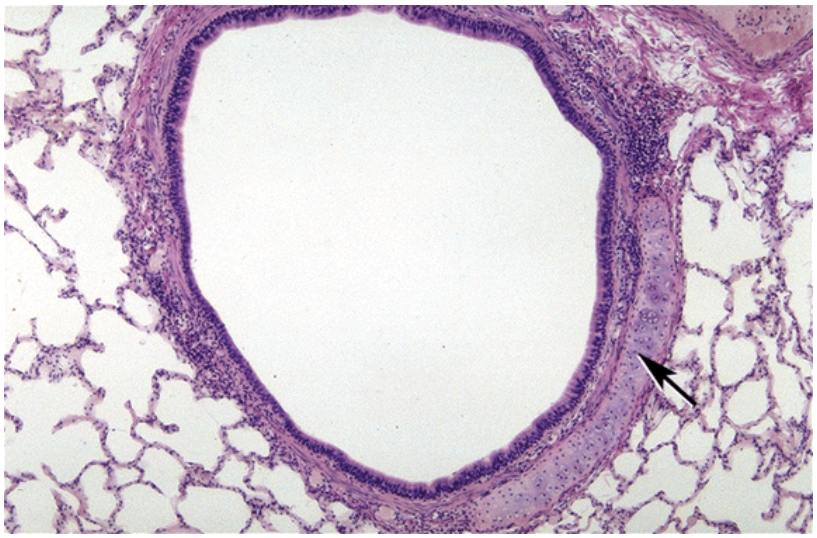

Copyright McGraw-Hill Companies. Used with permission.

Figure II-2-14. Bronchus with a Plate of Cartilage (arrow)

Clinical Correlate

Bronchial metastatic tumors arise from Kulchitsky cells.

The epithelial lining of the bronchi is also pseudostratified. It consists of **ciliated columnar cells, basal cells, mucous cells, brush cells and neuroendocrine** (APUD, DNES, or K) **cells**. There are also seromucous glands in the submucosa that empty onto the epithelial surface via ducts. The walls of bronchi contain irregular plates of cartilage and circular smooth-muscle fascicles bound together by elastic fibers. The number of goblet cells and submucosa glands decreases from the trachea to the small bronchi.

BRONCHIOLES

The **wall of a bronchiole** does not contain cartilage or glands. The smooth-muscle fascicles are bound together by elastic fibers. The epithelium is still ciliated, but is a simple cuboidal or columnar epithelium rather than pseudostratified. The epithelial lining of the airway is composed of **ciliated cells** (goblet and basal cells are absent in the terminal bronchioles) and an additional type called the **Clara cell.**

Clinical Correlate

Cystic fibrosis can result in abnormally thick mucous, in part due to defective chloride transport by Clara cells.

Clara cells (also called bronchiolar secretory cells) are nonciliated and **secrete a serous solution similar to surfactant**. They aid in the **detoxification of airborne toxins**, and serve as a **stem cell for the ciliated cells** and for themselves. The number of Clara cells increases in response to increased levels of pollutants like cigarette smoke. **Clara cells are most abundant in the terminal bronchioles, where they make up about 80% of the epithelial cell lining;** they are also involved with chloride ion transport into the lumens of the terminal bronchioles.

Clinical Correlate

Chronic obstructive pulmonary disease (COPD) affects the bronchioles and includes emphysema and asthma.

- Emphysema is caused by a loss of elastic fibers and results in chronic airflow obstruction.
- Asthma is a chronic process characterized by a reversible narrowing of airways.
- Asthma is reversible; emphysema is not.

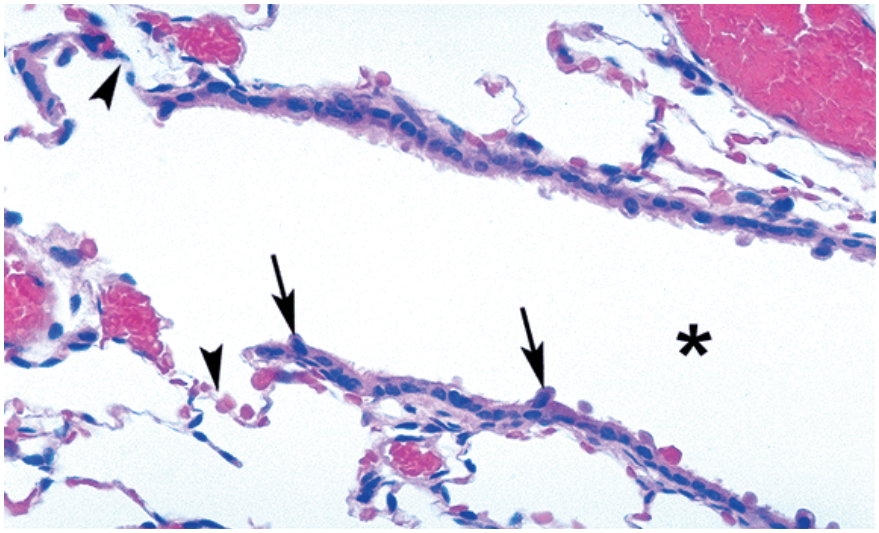

Copyright McGraw-Hill Companies. Used with permission.

Figure II-2-15. Terminal bronchiole lumen (asterisk) with epithelium containing ciliated cells and Clara cells (arrows)

The **terminal bronchiole** is the last conducting bronchiole. This bronchiole is followed by **respiratory bronchioles** which are periodically interrupted by alveoli in their walls. The goblet cells are absent from the epithelial lining of the respiratory bronchioles; however, this epithelium is still lined with a sparse ciliated cuboidal epithelium which prevents the movement of mucous into the alveoli. After the last respiratory bronchiole, the wall of the airway disappears and air enters the alveoli.

ALVEOLAR DUCTS, ALVEOLAR SACS, AND THE ALVEOLI

The **alveolar ducts and sacs** have little or no walls and consist almost entirely of alveoli. The alveoli constitute 80–85% of the volume of the normal lung. There are 300 million alveoli in the lungs, each ~200 microns in diameter. The cuboidal epithelium of the respiratory bronchioles and the alveolar ducts are continuous with the squamous cells lining the alveoli.

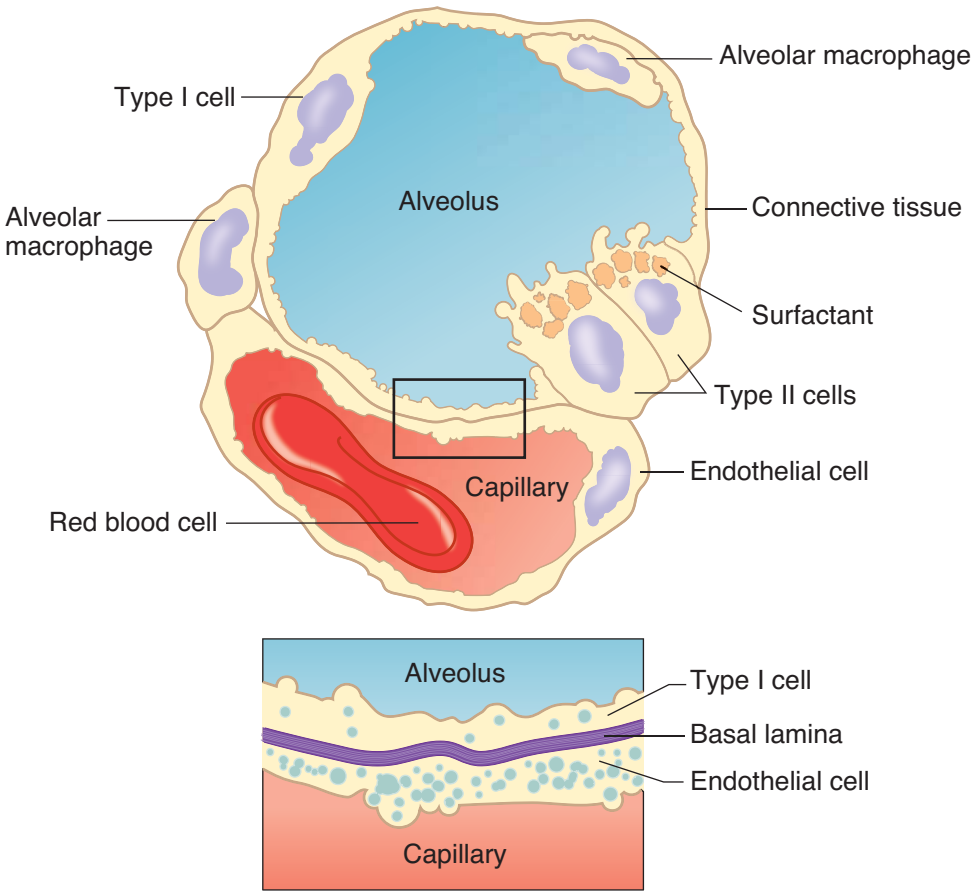

Figure II-2-16. Alveolus and Blood–Air Barrier

The **type I pneumocyte** is the major cell lining cell of the alveolar surfaces (also called small alveolar cell or alveolar type I cell).

- Represent only 40% of the alveolar lining cells, but are spread so thinly they cover 90–95% of the surface
- Primarily involved in gas exchange
- Post-mitotic

The **type II pneumocyte** is the other major alveolar cell (also called great alveolar cell [because of its size], granular pneumocyte, septal cell, corner cell, niche cell, or alveolar type II).

- Constitute 60% of the cell lining the alveoli, but form only 5–10% of the surface
- Produce and secrete surfactant
- Large, round cells with "myelin figures" in their apical cytoplasm which represent the remnants of surfactant after histological processing
- Serve as stem cells for themselves and the type I cell

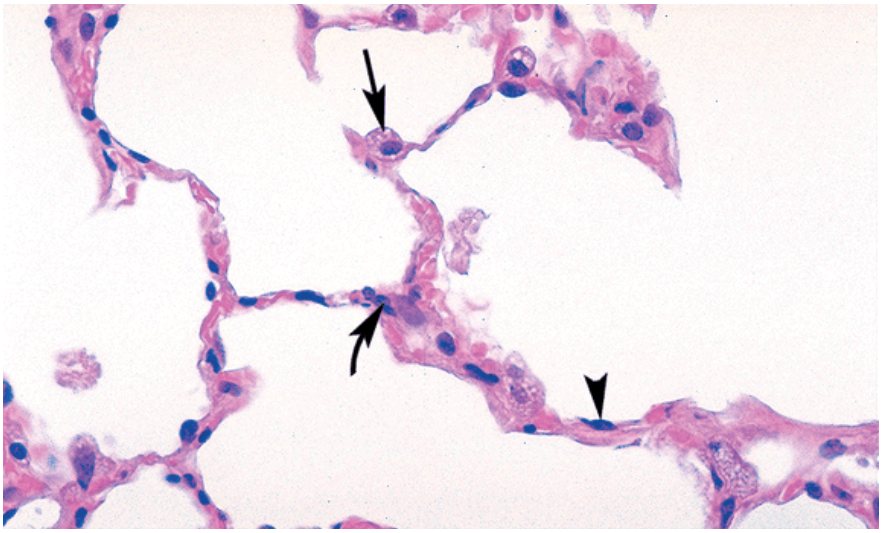

Copyright McGraw-Hill Companies. Used with permission.

Figure II-2-17. Alveoli with Type I Pneumocytes (arrowhead), Type II Pneumocytes (arrow), and Alveolar Macrophage (curved arrow) in the Alveolar Wall

Surfactant

Surfactant is essential to maintain the normal respiratory mechanics of the alveoli. Production of surfactant in the fetus is essential for the survival of the neonate as it takes its first breath. Surfactant is composed of a mixture of phospholipids and surfactant proteins whose function is to aid in the spreading of the surfactant at the alveolar air–water interface. The phospholipids act as a detergent which lowers the surface tension of the alveoli and prevents alveolar collapse during expiration.

Most surfactant is recycled back to Type II cells for reutilization; some of it undergoes phagocytosis by macrophages.

Clinical Correlate

Corticosteroids induce the fetal synthesis of surfactant. High insulin levels in diabetic mothers antagonize the effects of corticosteroids.

Infants of diabetic mothers have a higher incidence of respiratory distress syndrome.

Alveolar Wall

In the **alveolar wall** under the alveolar epithelium is a rich network of capillaries arising from pulmonary arteries. The alveolar wall contains a variety of cells and extracellular fibers. The cells include fibroblasts, macrophages, myofibroblasts, smooth-muscle cells, and occasional mast cells. Type I and II collagens, as well as elastic fibers, are in the septa. Type I collagen is present primarily in the walls of the bronchi and bronchioles. Twenty percent of the mass of the lung consists of collagen and elastic fibers. Elastic fibers are responsible for the stretching and recoiling activities of the alveoli during respiration. These microscopic elements are responsible for the recoil of the lungs during expiration.

Gas exchange occurs between capillary blood and alveolar air across the blood–gas barrier. This barrier consists of surfactant, the squamous Type I pneumocytes, a shared basal lamina, and capillary endothelium. The distance between the lumen of the capillary and the lumen of the alveolus can be as thin as 0.1 microns. There are openings in the wall of most alveoli that form the **pores of Kohn**. These pores are thought to be important in collateral ventilation. The diameter of these alveolar pores can be as large as 10 to 15 microns.

Alveolar Macrophages

The **alveolar macrophages** are derived from monocytes that exit the blood vessels in the lungs. The resident alveolar macrophages can undergo limited mitoses to form additional macrophages. These cells can reside in the interalveolar septa as well as in the alveoli. Alveolar macrophages that patrol the alveolar surfaces may pass through the pores of Kohn.

There are ~1–3 macrophages per alveolus. Alveolar macrophages vary in size, 15–40 microns in diameter. These macrophages represent the last defense mechanism of the lung. Macrophages can pass out of the alveoli to the bronchioles and enter the lymphatics or become trapped in the moving mucous layer and propelled toward the pharynx to be swallowed and digested.

Clinical Correlate

Alveolar macrophages have several other names: **dust cells** because they have phagocytosed dust or cigarette particles, and **heart failure cells** because they have phagocytosed blood cells that have escaped into the alveolar space during congestive heart failure.

EMBRYOLOGY OF THE HEART

Formation of Heart Tube

The heart begins to develop from splanchnic **mesoderm** in the latter half of week 3 within the cardiogenic area of the cranial end of the embryo. **Neural crest cells** migrate into the developing heart and play an important role in cardiac development. The cardiogenic cells condense to form a pair of primordial heart tubes which will fuse into a single **heart tube** during body folding.

- The heart tube undergoes dextral looping (bends to the right) and rotation.
- The upper truncus arteriosus (ventricular) end of the tube grows more rapidly and folds downward and **ventrally** and to the right.
- The atria and sinus venosus lower part of the tube fold upward and **dorsally** and to the left. These foldings begin to place the chambers of the heart in their postnatal anatomic positions.

The **primitive heart tube forms 4 dilatations and a cranial outflow tract**, the truncus arteriosus. The fates of these are shown below.

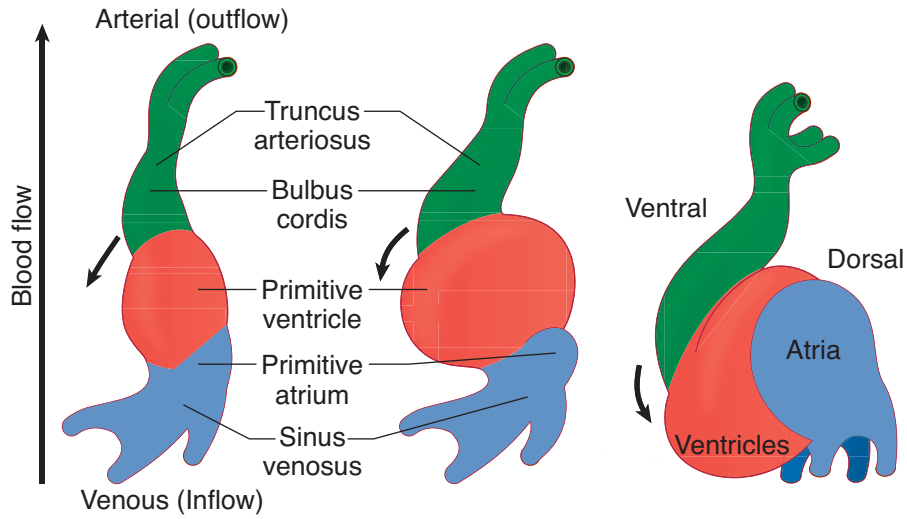

Figure II-2-18. Development of the Heart Tube

Table II-2-2. Adult Structures Derived From the Dilatations of the Primitive Heart

Embryonic Dilatation	Adult Structure
Truncus arteriosus (neural crest)	Aorta; Pulmonary trunk; Semilunar values
Bulbus cordis	Smooth part of right ventricle (**conus arteriosus**) Smooth part of left ventricle (**aortic vestibule**)
Primitive ventricle	Trabeculated part of right ventricle Trabeculated part of left ventricle
Primitive atrium*	Trabeculated part of right atrium (pectinate muscles) Trabeculated part of left atrium (pectinate muscles)
Sinus venosus (the only dilation that does not become subdivided by a septum)	Right—Smooth part of right atrium (**sinus venarum**) Left—Coronary sinus and oblique vein of left atrium

*The **smooth-walled** part of the **left atrium** is formed by incorporation of parts of the **pulmonary veins** into its wall. The **smooth-walled part** of the **right atrium** is formed by the incorporation of the **right sinus venosus.**

Fetal Circulation

There are **3 major venous systems** that flow into the sinus venosus end of the heart tube:

- **Vitelline (omphalomesenteric) veins** drain deoxygenated blood from the yolk stalk; they will coalesce and form the veins of the liver (sinusoids, hepatic portal vein, hepatic vein) and part of the inferior vena cava.
- **Umbilical vein** carries oxygenated blood from the placenta.
- **Cardinal veins** carry deoxygenated blood from the body of the embryo; they will coalesce and contribute to some of the major veins of the body (brachiocephalic, superior vena cava, inferior vena cava, azygos, renal).

During fetal circulation, **oxygenated blood flood** from the placenta to the fetus passes through the **umbilical vein**. Three **vascular shunts** develop in the fetal circulation to bypass blood flow around the liver and lungs:

- The **ductus venosus** allows oxygenated blood in the umbilical vein to bypass the sinusoids of the liver into the inferior vena cava and to the right atrium. From the right atrium, oxygenated blood flows mostly through the foramen ovale into the left atrium then left ventricle and into the systemic circulation.
- The **foramen ovale** develops during atrial septation to allow oxygenated blood to bypass the pulmonary circulation. Note that this is a **right-to-left** shunting of blood during fetal life.

- During fetal circulation, the superior vena cava drains deoxygenated blood from the upper limbs and head into the right atrium. Most of this blood flow is directed into the right ventricle and into the pulmonary trunk. The **ductus arteriosus** opens into the underside of the aorta just **distal** to the origin of the left subclavian artery and shunts this deoxygenated blood from the pulmonary trunk to the aorta to bypass the pulmonary circulation.

The shunting of blood through the foramen ovale and through the ductus arteriosus (right to left) during fetal life occurs because of a **right-to-left pressure gradient**.

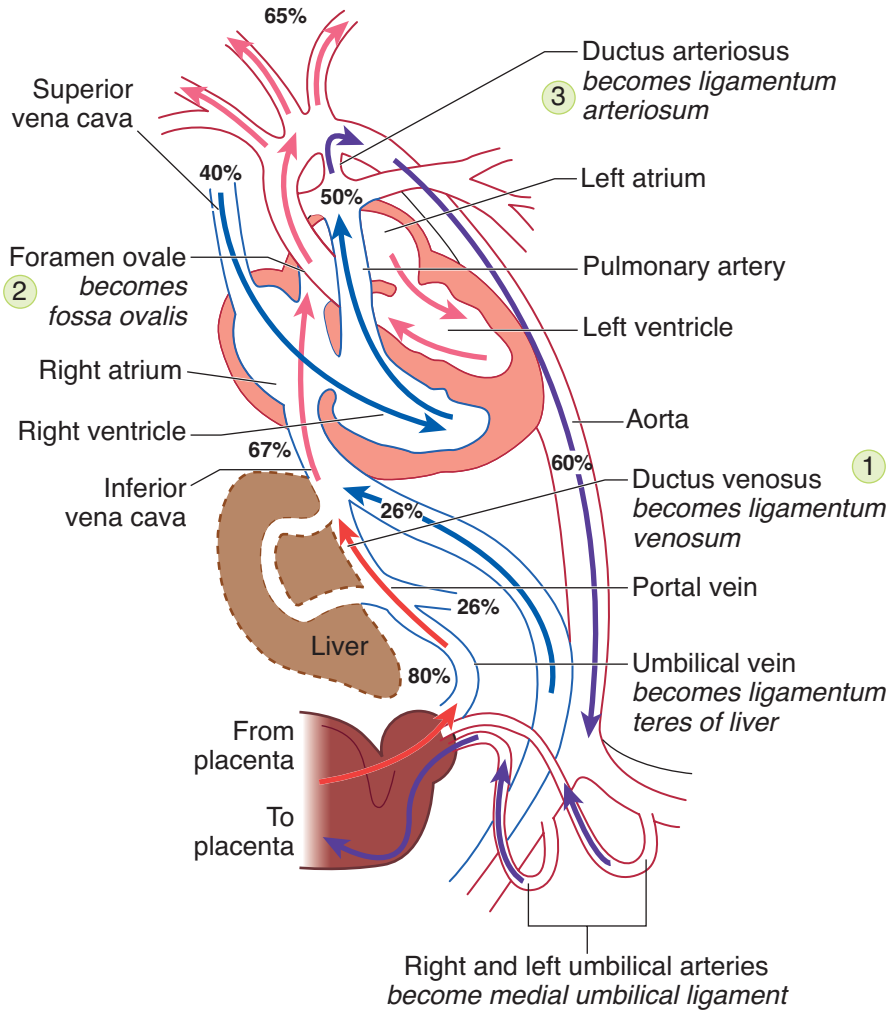

Figure II-2-19. Fetal Circulation and Shunts

Following birth, these 3 shunts, labelled **1**, **2**, and **3**, will close because of changes in the pressure gradients and in oxygen tensions. The umbilical vein closes and reduces blood flow into the right atrium. The ductus venosus also closes. Lung expansion reduces pulmonary resistance and results in increased flow to the lungs and increased venous return to the left atrium.

Pressure Gradients

Fetal

R → L

Postnatal

L → R

- Closure of the foramen ovale occurs as a result of the increase in left atrial pressure and reduction in right atrial pressure.
- Closure of the ductus venosus and ductus arteriosus occurs over the next several hours as a result of the contraction of smooth muscles in its wall and increased oxygen tension.
- The release of bradykinin and the immediate drop of prostaglandin E at birth also facilitate the closure of the ductus arteriosus.

The changes which occur between pre- and postnatal circulation are summarized below.

Table II-2-3. Adult Vestiges Derived from the Fetal Circulatory System

Changes After Birth	Remnant in Adult
Closure of right and left umbilical arteries	Medial umbilical ligaments
Closure of the umbilical vein	Ligamentum teres of liver
Closure of ductus venosus	Ligamentum venosum
Closure of foramen ovale	Fossa ovalis
Closure of ductus arteriosus	Ligamentum arteriosum

SEPTATION OF THE HEART TUBE

Except for the **sinus venosus** of the embryonic heart tube that initially develops into right and left horns, the ventricular, atrial, and truncus parts of the heart tube, which are originally a common chamber, will undergo septation into a right and left heart structure. The septation of the atria and ventricles occurs simultaneously beginning in week 4 and is mostly finished in week 8. Most of the common congenital cardiac anomalies result from defects in the formation of these septa.

Atrial Septation

During fetal life, blood is shunted from the right to the left atrium via the foramen ovale (FO). Note that during fetal circulation, right atrial pressure is higher than left due to the large bolus of blood directed into the right atrium from the placenta and to high pulmonary resistance.

The FO has to remain open and functional during the entire fetal life to shunt oxygenated blood from the right atrium into the left atrium.

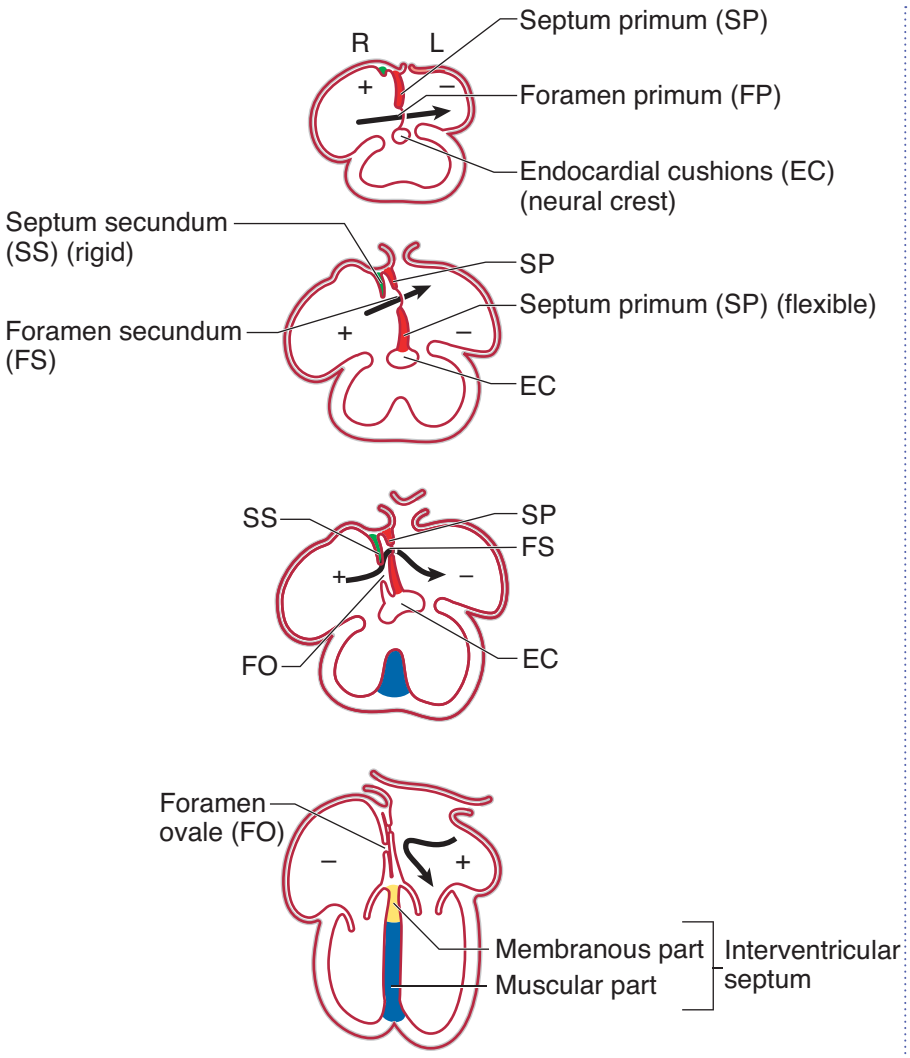

Figure II-2-20. Formation of Atrial Septum

Beginning week 4, the **common atrium** is divided into right and left atria by a series of events involving 2 septa and 2 foramina.

- The flexible **septum primum** (SP) grows inferiorly from the roof of the common atrium toward the **endocardial cushions**, a centrally located mass of mesoderm in the developing heart. Initially, the SP does not reach and fuse with the endocardial cushions. The endocardial cushions form the right and left atrioventricular canals and contribute to the formation of the atrioventricular valves, membranous part of the interventricular septum, and aorticopulmonary septum. **Neural crest cells** migrate into the cushions and facilitate their development.
- The **foramen primum** (FP) is located between the inferior edge of the SP and the endocardial cushion; it is obliterated when the SP later fuses with the endocardial cushions.
- The **foramen secundum** (FS) forms within the upper part of the SP just before the FP closes to maintain the right-to-left shunting of oxygenated blood that entered the right atrium via the inferior vena cava.

- The rigid **septum secundum** (SS) forms to the right of the SP from the roof of the atrium, descends, and partially covers the FS. It does not fuse with the endocardial cushions.
- The **foramen ovale** (FO) is the opening between SP and SS.

Closure of the FO normally occurs immediately after birth; it is caused by increased left atrial pressure resulting from changes in pulmonary circulation and decreased right atrial pressure due to the closure of the umbilical vein.

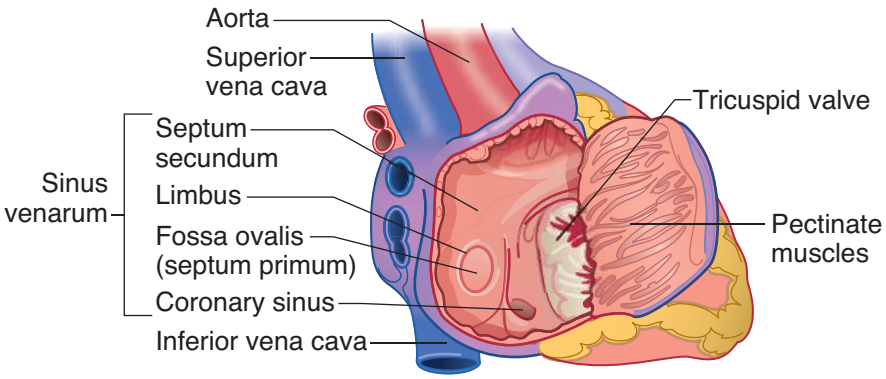

Figure II-2-21. Postnatal Atrial Septum

Atrial Septal Defects

Atrial septal defect (ASD) is one of several congenital heart defects. It is more common in female births than in male. Postnatally, ASDs result **in left-to-right shunting** and are **non-cyanotic conditions**. Two clinically important ASDs are the **secundum** and **primum** types.

- **Secundum-type ASD** is the most common ASD. It is caused by either an excessive resorption of the SP or an underdevelopment and reduced size of the SS or both. This ASD results in variable openings between the right and left atria in the central part of the atrial septum above the limbus. If the ASD is small, clinical symptoms may be delayed as late as age 30.
- **Primum type ASD** is less common than secundum ASD and results from a failure of the septum premium to fuse with the endocardial cushions, and may be combined with defects of the endocardial cushions. Primum ASDs occur in the lower aspect of the atrial wall, usually with a normal formed fossa ovalis. If the endocardial cushion is involved, a primum ASD can also be associated with a defect of the membranous interventricular septum and the atrioventricular valves.

Note

Postnatal Shunts

Right-to-left shunts are **cyanotic conditions**. **Left-to-right** shunts are **non-cyanotic conditions**.

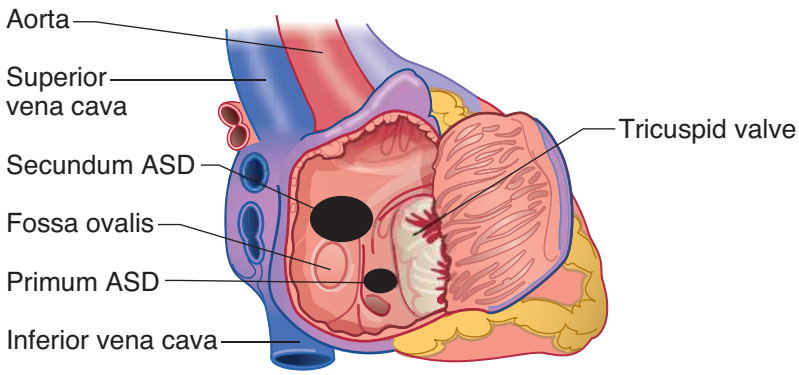

Figure II-2-22. Secundum and Primum Atrial Septal Defect

Ventricular Septation

The development of the **interventricular (IV) septum** begins in week 4 and is usually completed by the end of week 7. Unlike atrial septation, the IV septum will develop and close completely by week 8 without any shunting between the ventricles.

The adult IV septum consists of 2 parts: a large, **muscular component** forming most of the septum and a thin, **membranous part** forming a small component at the superior aspect of the septum.

- The **muscular IV septum** develops in the floor of the ventricle, ascends, and partially separates the right and left ventricles, leaving the **IV foramen**.
- The **membranous IV septum** closes the IV foramen. It forms by the fusion of the right conotruncal ridge, the left conotruncal ridge, endocardial cushion (**neural crest cells** are associated with the endocardial cushion and conotruncal ridges).

Clinical Correlate

Ventricular septal defect (VSD) is the most common of the congenital heart defects, being more common in males than in females. The most common form is a **membranous VSD**, associated with the failure of **neural crest** cells to migrate into the endocardial cushions. A membranous VSD is caused by the failure of the membranous interventricular (IV) septum to develop, and it results in **left-to-right shunting** of blood through the IV foramen.

Patients with left-to-right shunting complain of **excessive fatigue upon exertion**. Left-to-right shunting of blood is **noncyanotic** but causes increased blood flow and pressure to the lungs (pulmonary hypertension). Pulmonary hypertension causes marked proliferation of the tunica intima and media of pulmonary muscular arteries and arterioles. Ultimately, the pulmonary resistance becomes higher than systemic resistance and causes **right-to-left shunting** of blood and late **cyanosis**. At this stage, the condition is called **Eisenmenger complex**.

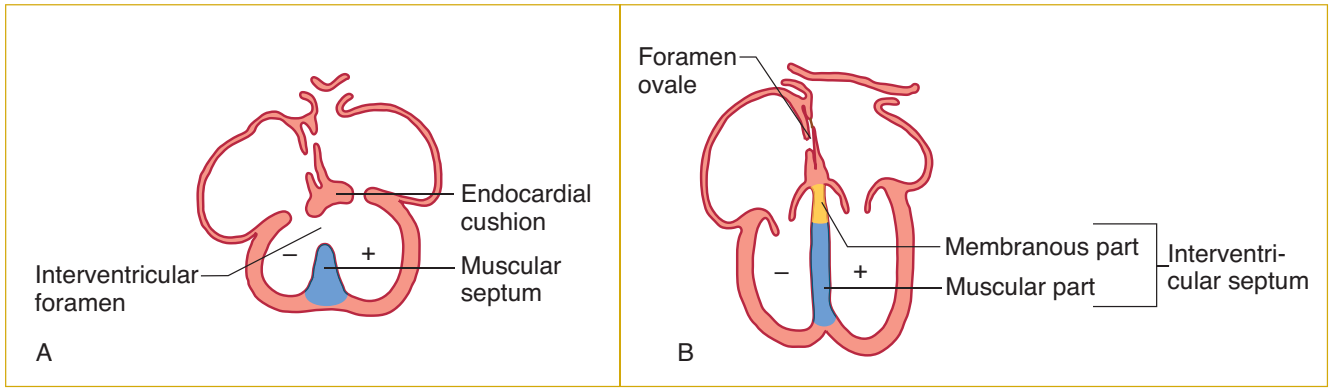

Figure II-2-23. Interventricular Septum

Patent Ductus Arteriosus

A **patent ductus arteriosus** (PDA) occurs when the ductus arteriosus (a connection between the pulmonary trunk and aorta) fails to close after birth. PDA is common in premature infants and in cases of maternal rubella infection.

- Postnatally, a PDA causes a **left-to-right** shunt (from aorta to pulmonary trunk) and is **non-cyanotic**. The newborn presents with a machine-like murmur.
- Normally, the ductus arteriosus closes within a few hours after birth via smooth-muscle contraction to form the **ligamentum arteriosum**. Prostaglandin E (PGE) and low oxygen tension sustain patency of the ductus arteriosus in the fetal period.
- PGE is used to keep the PDA open in certain heart defects (transposition of great vessels).
- PGE inhibitor (e.g., indomethacin), acetylcholine, histamine, and catecholamines promote closure of the ductus arteriosus in a premature birth.

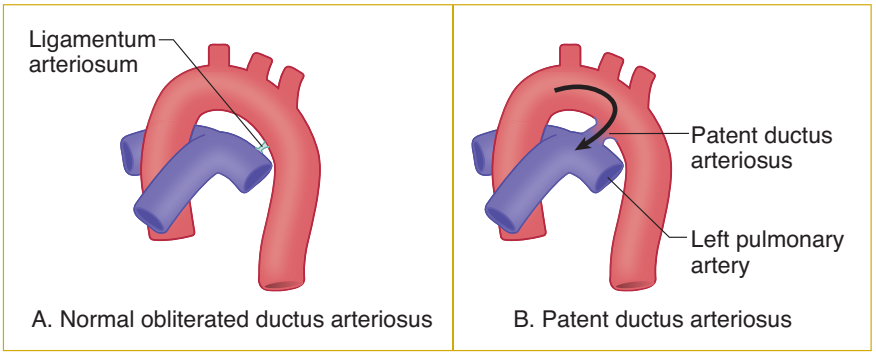

Figure II-2-24. Ductus Arteriosus

Septation of the Truncus Arteriosus

The **septation of the truncus arteriosus** occurs during week 8. **Neural crest cells** migrate into the conotruncal and bulbar ridges of the truncus arteriosus, which grow in a **spiral fashion** and fuse to form the **aorticopulmonary (AP) septum**. The AP septum divides the truncus arteriosus into the **aorta** and **pulmonary trunk**.

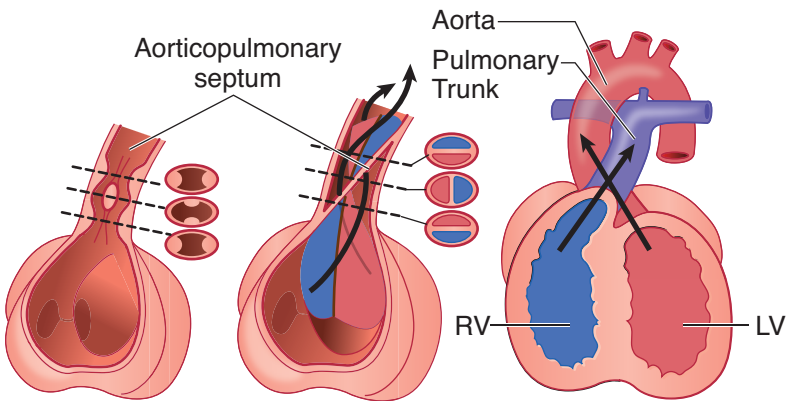

Figure II-2-25. Formation of the Aorticopulmonary Septum

There are 3 classic **cyanotic congenital heart abnormalities** that occur with defects in the development of the aorticopulmonary septum. They are related to the failure of neural crest cells to migrate into the truncus arteriosus:

- **Tetralogy of Fallot (most common)** occurs when the AP septum fails to align properly and shifts anteriorly to the right. This causes **right-to-left** shunting of blood with resultant **cyanosis** that is usually present sometime after birth. Imaging typically shows a boot-shaped heart due to the enlarged right ventricle. There are 4 major defects in tetralogy of Fallot:
  - Pulmonary stenosis (most important)
  - Membranous interventricular septal defect
  - Right ventricular hypertrophy (develops secondarily)
  - Overriding aorta (receives blood from both ventricles)

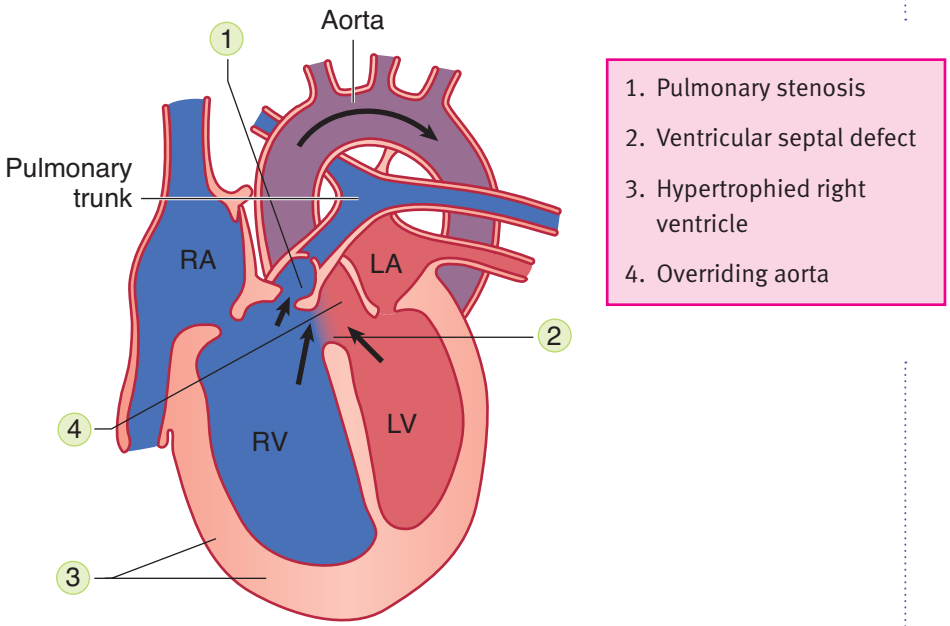

Figure II-2-26. Tetralogy of Fallot

- **Transposition of the great vessels** occurs when the AP septum fails to develop in a spiral fashion and results in the aorta arising from the right ventricle and the pulmonary trunk arising from the left ventricle. This causes **right-to-left s**hunting of blood with resultant cyanosis.
  - Transposition is the most common cause of severe cyanosis that persists immediately at birth. Transposition results in producing 2 closed circulation loops.
  - Infants born alive with this defect usually have other defects (PDA, VSD, ASD) that allow mixing of oxygenated and deoxygenated blood to sustain life.

1. Aorta arises from right ventricle
2. Pulmonary trunk arises from left ventricle
3. Usually associated with a VSD, ASD, or patent ductus arteriosus

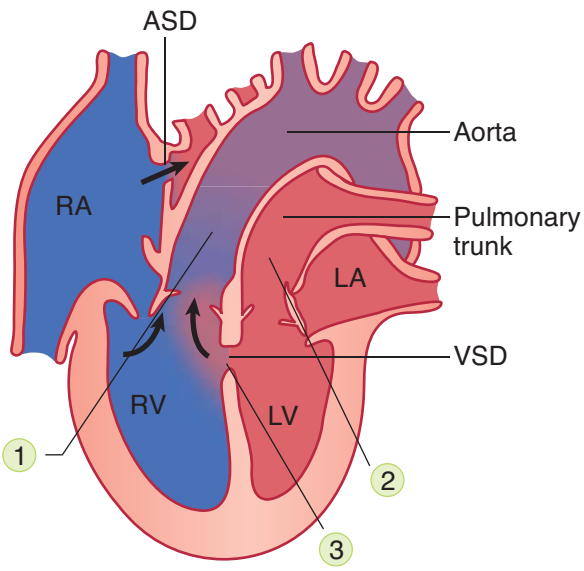

Figure II-2-27. Transposition of the Great Vessels

- Persistent truncus arteriosus occurs when there is only partial development of the AP septum. This results in a condition where only one large vessel leaves the heart that receives blood from both the right and left ventricles**.** This causes **right-to-left** shunting of blood with resultant **cyanosis**. This defect is **always accompanied** by a membranous VSD.

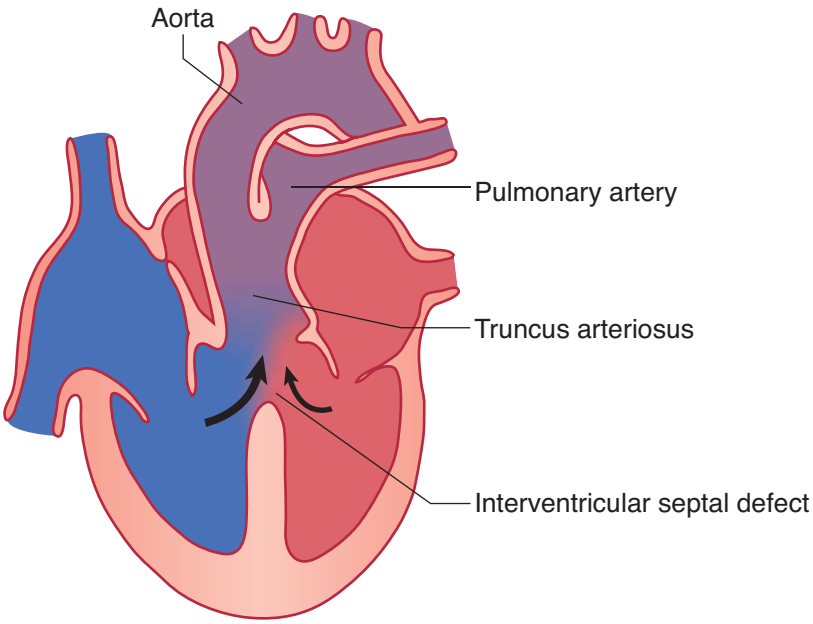

Figure II-2-28. Persistent Truncus Arteriosus

MEDIASTINUM

The **mediastinum** is the central, midline compartment of the thoracic cavity. It is bounded anteriorly by the sternum, posteriorly by the 12 thoracic vertebrae, and laterally by the pleural cavities.

- Superiorly, the mediastinum is continuous with the neck through the **thoracic inlet**; and inferiorly, is closed by the diaphragm. The mediastinum contains most of the viscera of the thoracic cavities except from the lungs (and pleura) and the sympathetic trunk.
- The sympathetic trunks are primarily located paravertebrally, just outside the posterior mediastinum. However, the greater, lesser, and least thoracic splanchnic nerves, which convey preganglionic sympathetic fibers to the collateral (prevertebral) ganglia below the diaphragm, enter the posterior mediastinum after leaving the sympathetic trunks.
- The mediastinum is divided into **superior** and **inferior** mediastina by a plane passing from the **sternal angle (of Louis)** anteriorly to the intervertebral disc between T4 and T5 posteriorly. The sternal angle and plane are **important clinical landmarks**. The inferior mediastinum is classically subdivided into **anterior, middle, and posterior** mediastina.

Note

Non-cyanotic congenital (left-to-right) heart defects at birth:

- Atrial septal defect
- Ventricular septal defects
- Patent ductus arteriosus

Cyanotic congenital (right-to-left) heart defects at birth

- Transposition of great vessels
- Tetralogy of Fallot
- Persistent truncus arteriosus

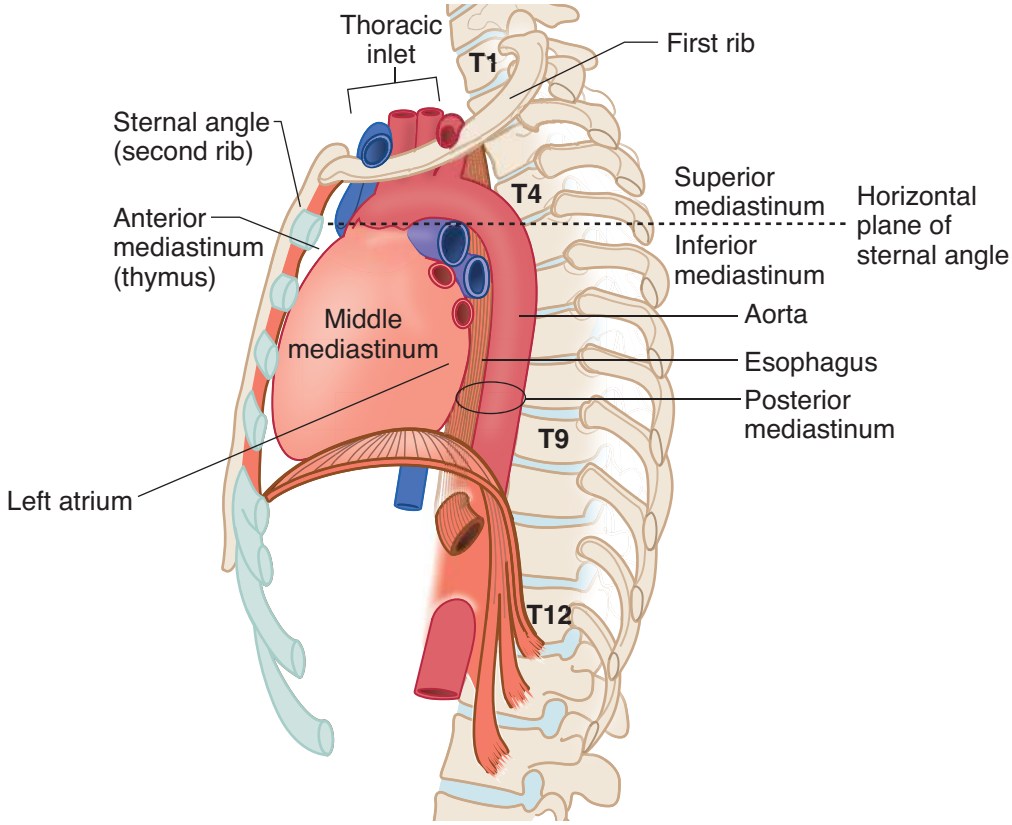

Figure II-2-29. Divisions of the Mediastinum

Anterior Mediastinum

The anterior mediastinum is the small interval between the sternum and the anterior surface of the pericardium. It contains fat and areolar tissue and the inferior part of the **thymus gland**. A tumor of the thymus (**thymoma**) can develop in the anterior or superior mediastinum.

Posterior Mediastinum

The **posterior mediastinum** is located between the posterior surface of the pericardium and the T5-T12 thoracic vertebrae. Inferiorly, it is closed by the diaphragm. There are 4 vertically oriented structures coursing within the posterior mediastinum:

- **Thoracic (descending) aorta**
  - Important branches are the **bronchial, esophageal,** and **posterior intercostal arteries**
  - Passes through the **aortic hiatus** (with the thoracic duct) at the T12 vertebral level to become the abdominal aorta
- **Esophagus**
  - Lies immediately posterior to the left primary bronchus and the **left atrium,** forming an important radiological relationship

  - Covered by the **anterior and posterior esophageal plexuses**, which are derived from the left and right vagus nerves, respectively
  - Passes through the **esophageal hiatus** (with the vagal nerve trunks) at the T10 vertebral level
  - Is constricted (1) at its origin from the pharynx, (2) posterior to the arch of the aorta, (3) posterior to the left primary bronchus, and (4) at the esophageal hiatus of the diaphragm
- **Thoracic duct**
  - Lies posterior to the esophagus and between the thoracic aorta and azygos vein
  - Ascends the posterior and superior mediastina and drains into the junction of the left subclavian and internal jugular veins
  - Arises from the cisterna chyli in the abdomen (at vertebral level L1) and enters the mediastinum through the **aortic hiatus** of the diaphragm
- **Azygos system of veins**
  - Drains the posterior and thoracic lateral wall
  - Communicates with the inferior vena cava in the abdomen and terminates by arching over the root of the right lung to empty into the **superior vena cava** above the pericardium
  - Forms a **collateral venous circulation** between the inferior and superior vena cava

Middle Mediastinum

The middle mediastinum contains the heart and great vessels and pericardium, which will be discussed later.

Superior Mediastinum

The **superior mediastinum** is located between the manubrium of the sternum, anteriorly, and the thoracic vertebrae 1-4, posteriorly. As with all mediastina, the parietal pleura and the lungs form the lateral boundary. The thoracic inlet connects superiorly with the neck and the horizontal plane through the sternal angle forms the inferior boundary.

- The superior mediastinum contains the thymus, great arteries and veins associated with the upper aspect of the heart, trachea, and esophagus.
- The vagus and phrenic nerves and the thoracic duct also course through the mediastinum.
- The pulmonary trunk and arteries are located completely in the middle mediastinum and are not found in the superior mediastinum.

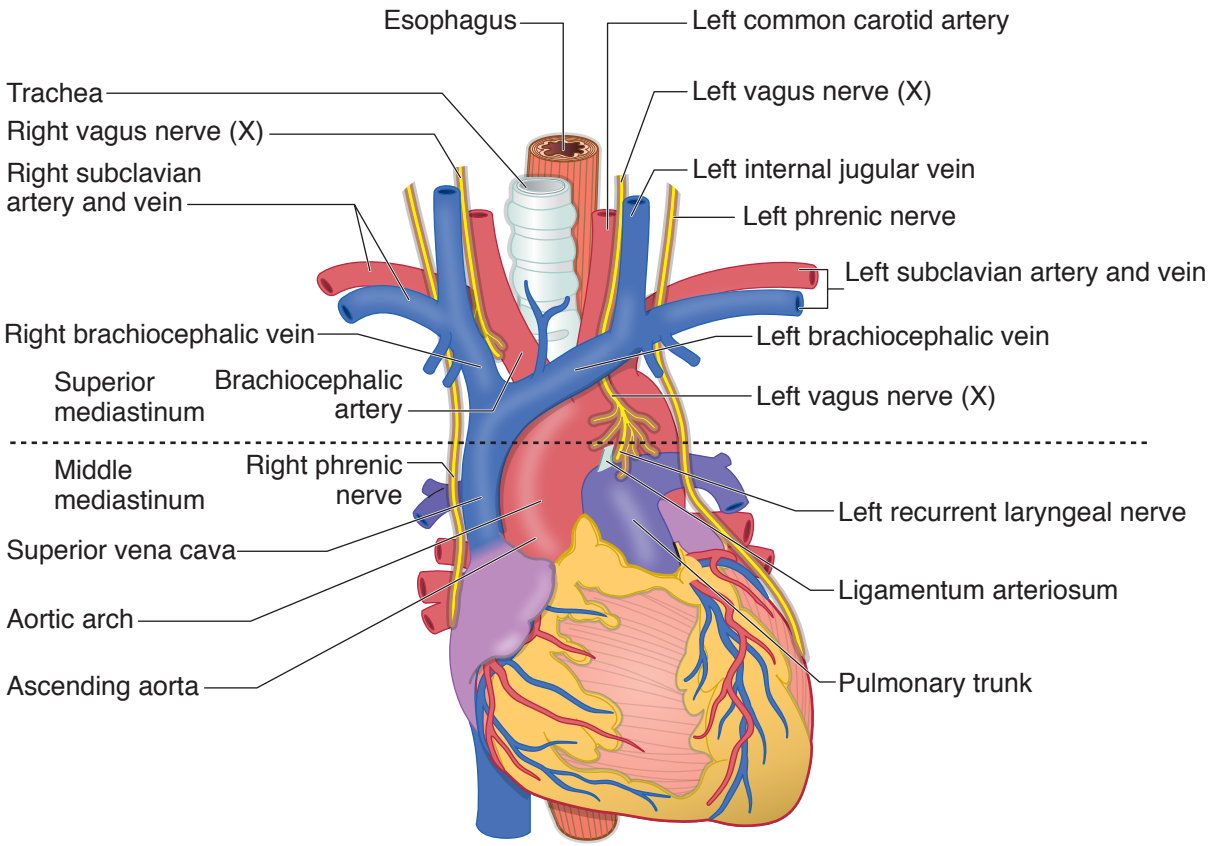

Figure II-2-30. Structures of the Mediastinum

The relationships of these structures in the superior mediastinum are best visualized in **a ventral to dorsal** orientation between the sternum anteriorly and the vertebrae posteriorly:

- **Thymus**: located posterior to the manubrium, usually atrophies in the adult and remains as fatty tissue
- **Right and left brachiocephalic veins**: right vein descends almost vertically and left vein obliquely crosses the superior mediastinum posterior to the thymic remnants
  - The 2 veins join to form the **superior vena cava** posterior to the **right first costal cartilage**.
  - The superior vena cava descends and drains into the right atrium **deep to the right third costal cartilage.**
- **Aortic arch and its 3 branches**: aortic arch begins and ends at the plane of the sternal angle and is located just **inferior** to the left brachiocephalic vein.
  - As a very important radiological landmark, the origins of the 3 branches of the aortic arch (**brachiocephalic, left common carotid, and left subclavian)** are directly **posterior** to the left brachiocephalic vein.

- **Trachea**: lies posterior to the aortic arch and bifurcates at the level of T4 vertebra to form right and left primary bronchi
  - The **carina** is an internal projection of cartilage at the bifurcation.
- **Esophagus**: lies posterior to the trachea and courses posterior to left primary bronchus to enter the posterior mediastinum

ln addition to these structures, the superior mediastinum also contains the **right and left vagus** and **phrenic nerves** and the superior end of the **thoracic duct.**

- Right and left **vagus nerves** contribute to the pulmonary and cardiac plexuses. In the neck, the right vagus nerve gives rise to the **right recurrent laryngeal nerve**, which passes under the right subclavian artery to ascend in the groove between the esophagus and the trachea to reach the larynx. **Note:** The right recurrent laryngeal nerve is not in the mediastinum. The left vagus nerve gives rise to the **left recurrent laryngeal nerve** in the superior mediastinum, which passes under the aortic arch and ligamentum arteriosum to ascend to the larynx.
- The **thoracic duct** is the largest lymphatic channel in the body. It returns lymph to the venous circulation at the junction of the left internal jugular vein and the left subclavian vein.
- **Phrenic nerves** arise from the ventral rami of **cervical nerves 3, 4, and 5.** The nerves are the sole motor supply of the diaphragm and convey sensory information from the central portion of both the superior and inferior portions of the diaphragm and parietal pleura. Both phrenic nerves pass through the middle mediastinum lateral between the fibrous pericardium and pleura, and anterior to the root of the lung.

Coarctation of the Aorta

Coarctation of the aorta is a narrowing of the aorta distal to the origin of the left subclavian artery. Two types are usually identified based on if the constriction is found proximal or distal to the opening of the ductus arteriosus (DA).

- **Preductal coarctation** (infantile type) is less common and occurs proximal to the DA (Figure II-2-31A). The DA usually remains patent and provides blood flow via the DA to the descending aorta and the lower parts of the body.
- **Postductal coarctation** (adult type) is more common and occurs distal to the DA (Figure II-2-31B). The DA usually closes and obliterates.
  - This results in the intercostal arteries providing collateral circulation between the internal thoracic artery and the thoracic aorta to provide blood supply to the lower parts of the body (Figure II-2-31C).
  - Patients will be hypertensive in the upper body (head, neck, and upper limbs) and hypotensive with weak pulses in the lower limbs.
  - Enlargement of the intercostal arteries results in **costal notching** on the lower border of the ribs, evident in imaging.

Clinical Correlate

The **left recurrent laryngeal nerve** (Figure II-2-30) curves under the aortic arch distal to the ligamentum arteriosum where it may be damaged by pathology (e.g., malignancy or aneurysm of the aortic arch), resulting in paralysis of the left vocal folds. The right laryngeal nerve is not affected because it arises from the right vagus nerve in the root of the neck and passes under the subclavian artery.

Either the right or the left recurrent laryngeal nerve may be lesioned with thyroid gland surgery.

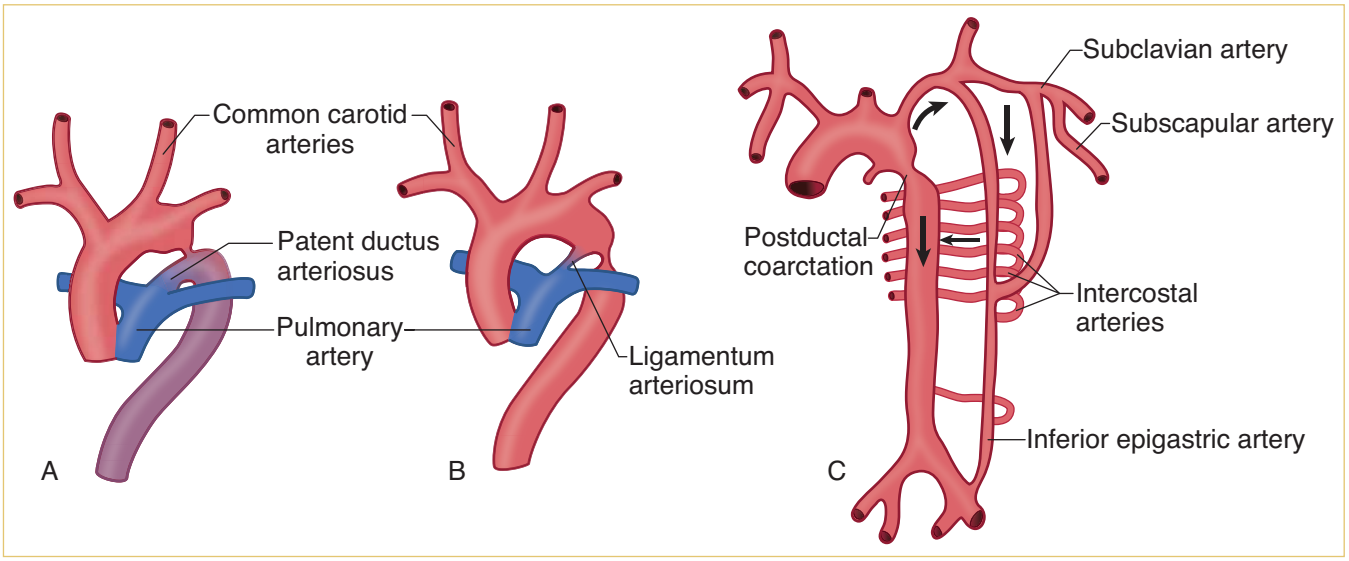

Figure II-2-31. Coarctation of the Aorta: (A) Preductal; (B) Postductal; (C) Collateral Circulation

Middle Mediastinum

The middle mediastinum contains the pericardium, the heart, parts of the great vessels, and the phrenic nerves.

The **pericardium** is the serous sac covering the heart. It is the only one of the serous membranes that has 3 layers: an outer **fibrous layer** and a double-layered **parietal and visceral serous** layers.

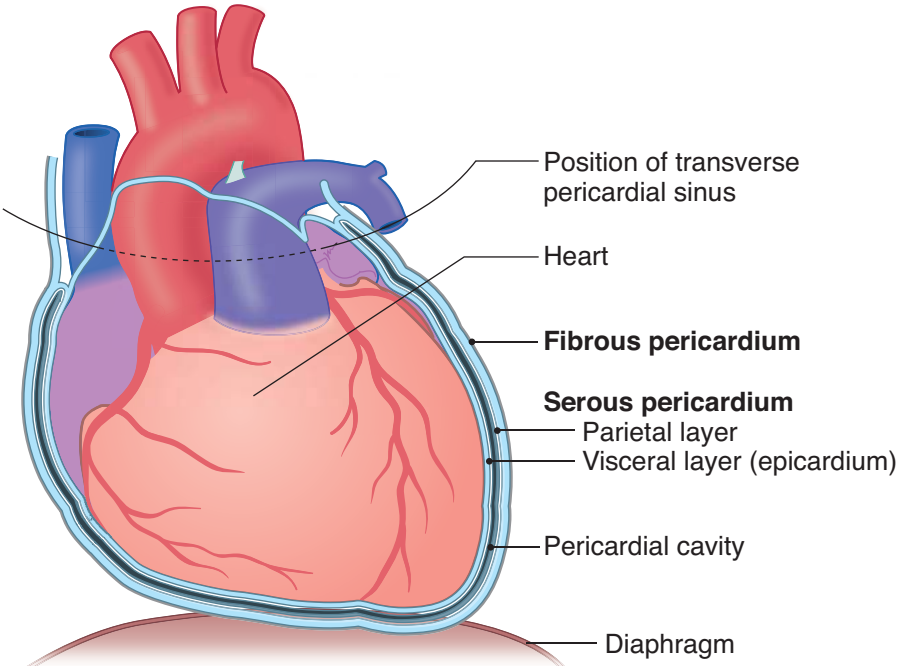

Figure II-2-32. Layers of the Pericardium

The **fibrous pericardium** surrounds the entire heart and the great vessels at the upper aspect of the heart. It is firmly attached below to the central tendon of the diaphragm and superiorly to the adventitia of the great vessels at the plane of the sternal angle (level of the second rib). The fibrous pericardium is very strong and maintains the position of the heart within the middle mediastinum.

The **serous pericardium** is double-layered and formed by the outer **parietal layer** that lines the inner aspect of the fibrous pericardium and the inner **visceral layer** (epicardium) that covers the surface of the heart. The reflection between these 2 serous layers is at the base of the great vessels.

The **pericardial cavity** is the potential space between the parietal and visceral layers containing a small amount of serous fluid that allows free movement of the beating heart. The pericardial cavity is expanded to form 2 sinuses:

- The **transverse pericardial sinus** is a space posterior to the ascending aorta and pulmonary trunk and anterior to the superior vena cava and pulmonary veins. Note that it separates the great arteries from the great veins. The transverse sinus is useful in cardiac surgery to allow isolation of the aorta and pulmonary trunk.
- The **oblique pericardial sinus** is the blind, inverted, U-shaped space posterior to the heart and bounded by reflection of serous pericardium around the 4 pulmonary veins and the inferior vena cava as they enter the heart.

Clinical Correlate

Cardiac tamponade is the pathological accumulation of fluids (serous or blood) within the pericardial cavity. The fluid compresses the heart and restricts venous filling during diastole and reduces cardiac output. To remove the fluid, **pericardiocentesis** is performed with a needle at the **left infrasternal angle** through the cardiac notch of the left lung.

HEART

External Features

The heart lies obliquely within the middle mediastinum, mostly posterior to the sternum. Externally, the heart can be described by its **borders** and **surfaces.**

Borders of the heart

- **The right border** is formed by the **right atrium**.
- The **left border** is mainly formed by the **left ventricle**.
- The **apex** is the tip of the **left ventricle,** and is found in the left fifth intercostal space.
- The superior border is formed by the right and left auricles plus the conus arteriosus of the right ventricle.
- The inferior border is formed at the diaphragm, mostly by the right ventricle.

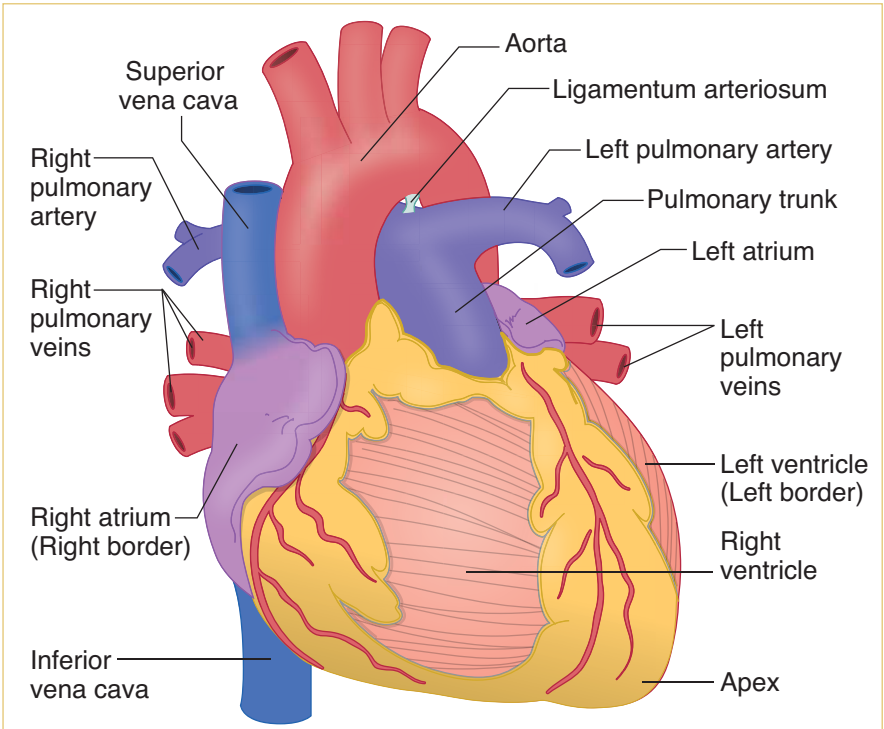

Figure II-2-33. Sternocostal View of the Heart

Surfaces of the heart

- The **anterior (sternocostal) surface** is formed primarily by the **right ventricle**.
- The **posterior surface** is formed primarily by the **left atrium.**
- The **diaphragmatic surface** is formed primarily by the **left ventricle**.

There are 3 main sulci (**coronary** and the **anterior and posterior interventricular**) that course on the surfaces of the heart; they contain the major vessels of the heart and epicardial fat.

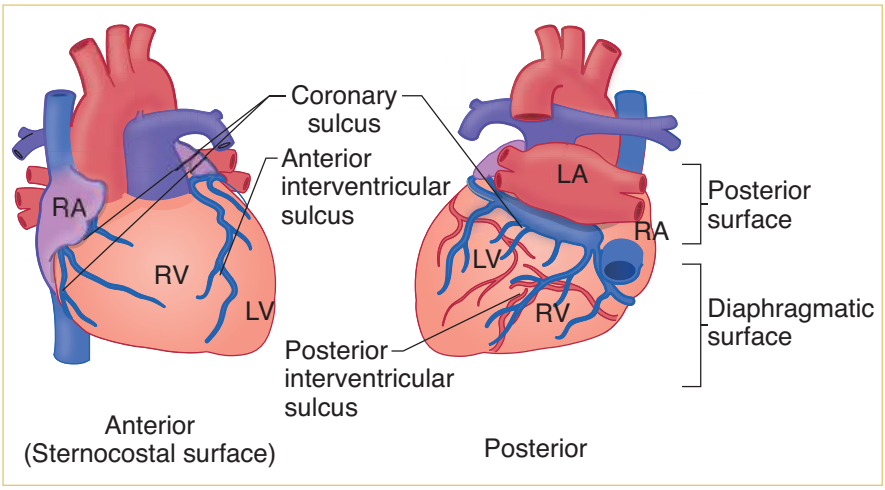

Figure II-2-34. Surfaces of Heart with Sulci

Surface projections

Surface projections of the heart may be traced on the anterior chest wall.

- The **upper right aspect** of the heart is deep to the **third right costal cartilage.**
- The **lower right aspect** of the heart is deep to the **sixth right costal cartilage.**
- The **upper left aspect** of the heart is deep to the **left second costal cartilage**
- The **apex** of the heart is in the **left fifth intercostal space** at the midclavicular line.
- The **right border** extends between the margin of the third right costal cartilage to the sixth right costal cartilage just to the right of the sternum.
- The **left border** extends between the fifth left intercostal space to the second left costal cartilage.
- The **inferior border** extends from the sixth right costal cartilage to the fifth left intercostal space at the midclavicular line.
- The **superior border** extends from the inferior margin of the second left costal cartilage to the superior margin of the third right costal cartilage.

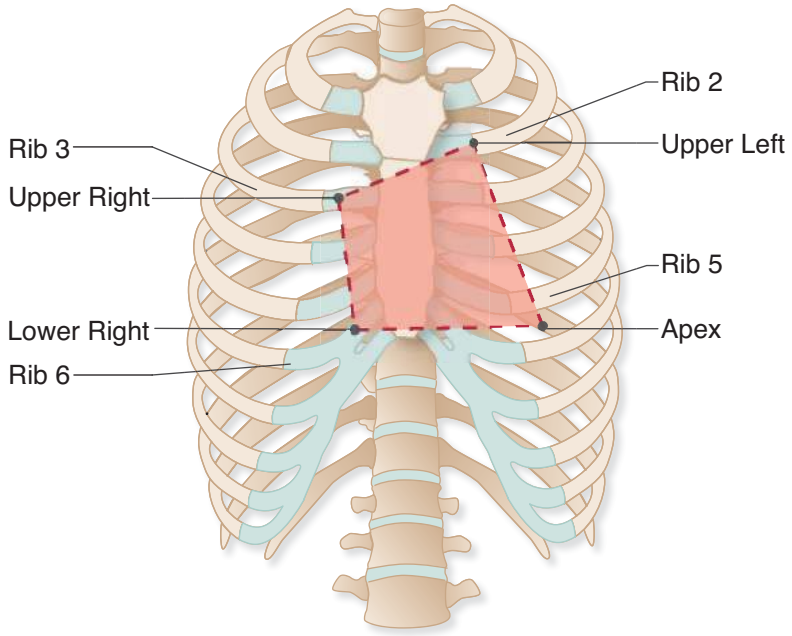

Figure II-2-35. Surface Projections of the Heart

Internal Features

Chambers of the Heart

The **right atrium** receives venous blood from the entire body with the exception of blood from the pulmonary veins.

- The **auricle** is derived from the fetal atrium; it has rough myocardium known as pectinate muscles.
- The **sinus venarum** is the smooth-walled portion of the atrium, which receives blood from the superior and inferior venae cavae. It developed from the **sinus venosus**.
- The **crista terminalis** is the vertical ridge that separates the smooth from the rough portion (pectinate muscles) of the right atrium; it extends longitudinally from the superior vena cava to the inferior vena cava. The **SA node** is in the upper part of the crista terminalis.
- The **fossa ovalis** is close to the foramen ovale, an opening in the interatrial septum which allows blood entering the right atrium from the inferior vena cava to pass directly to the left side of the heart.
- The right AV **(tricuspid) valve** communicates with the right ventricle.

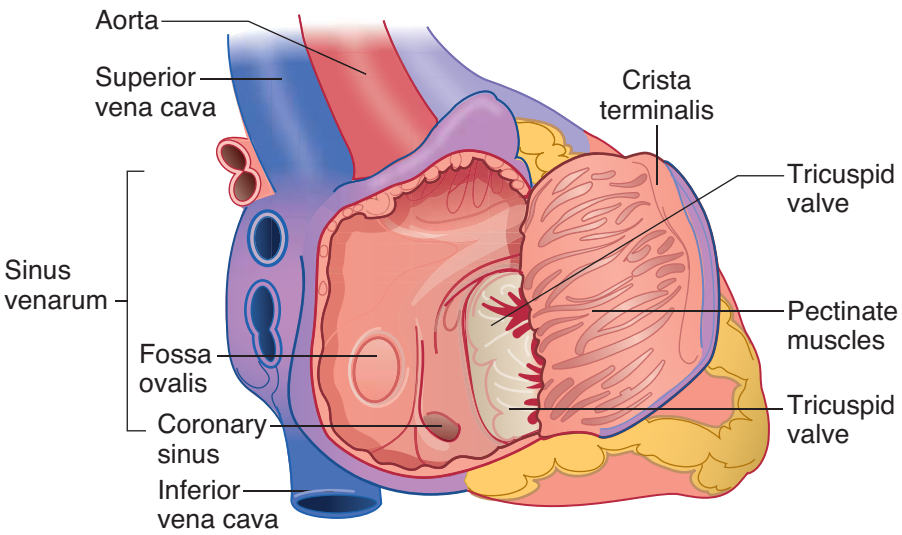

Figure II-2-36. Inside the Right Atrium

The **left atrium** receives oxygenated blood from the lungs via the pulmonary veins. There are 4 openings: upper right and left, and lower right and left pulmonary veins. The left AV orifice is guarded by the mitral **(bicuspid) valve**; it allows oxygenated blood to pass from the left atrium to the left ventricle.

The **right ventricle** receives blood from the right atrium via the tricuspid valve; outflow is to the pulmonary trunk via the pulmonary semilunar valve.

- The **trabeculae carneae** are ridges of myocardium in the ventricular wall.
- The **papillary muscles** project into the cavity of the ventricle and attach to cusps of the AV valve by the strands of the chordae tendineae.

- The **chordae tendineae** are fibrous cords between the papillary muscles and the valve leaflets that control closure of the valve during contraction of the ventricle.
- The **infundibulum** is the smooth area of the right ventricle leading to the pulmonary valve.
- The **septomarginal trabecula (moderator band)** is a band of cardiac muscle between interventricular septum and anterior papillary muscle which conducts part of the cardiac conduction system.

In the **left ventricle**, blood enters from the left atrium through the mitral valve and is pumped out to the aorta through the aortic valve.

- The **trabeculae carneae** are ridges of myocardium in the ventricular wall, normally thicker than those of the right ventricle.
- The **papillary muscles**, usually 2 large ones, are attached by the chordae tendineae to the cusps of the bicuspid valve.
- The **chordae tendineae** act in same way as the right ventricle.
- The **aortic vestibule** leads to the aortic semilunar valve and ascending aorta.

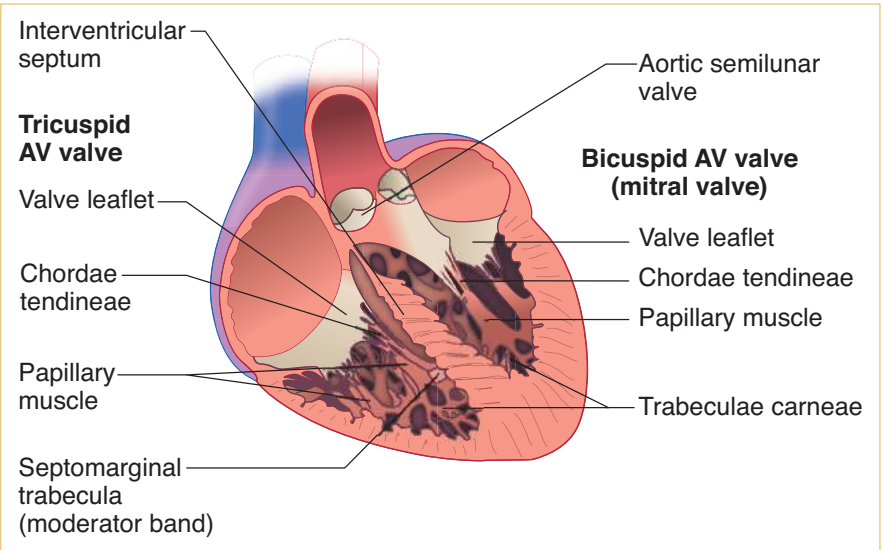

Figure II-2-37. Right and Left Ventricles

HEART HISTOLOGY

Cardiac muscle is striated in the same manner as skeletal muscle, but it differs in being composed of smaller cells (fibers) with only 1 or 2 nuclei. The nuclei are located centrally, instead of peripherally.

Layers of the Heart Wall

The heart wall is composed of 3 distinct layers: an outer epicardium, a middle myocardium and an inner endocardium. The epicardium, or visceral layer of serous pericardium, consists of a simple squamous epithelium (mesothelium) and its underlying connective tissue. The connective tissue contains a large number of fat cells and the coronary vessels. The muscular wall of the heart is the myocardium and is composed mainly of cardiac muscle cells. The endocardium, which lines the chambers of the heart, is composed of a simple squamous epithelium, the endothelium, and a thin layer of connective tissue. Cardiac muscle is striated like skeletal muscle, but these cells are smaller, with centrally placed nuclei. Cardiac muscle has a similar but somewhat less well developed T-tubule system compared to skeletal muscle that is located at the Z-line.

Intercalated Discs

Intercalated discs are special junctional complexes that join myocardial cells. The intercalated discs appear as dark, transverse lines in the light microscope. These disks contain gap junctions and adhering junctions. These junctions permit the spread of electrical (gap) and mechanical (adhering) effects through the walls of the heart, synchronizing activity for the pumping action of the heart chambers. While intercalated discs allow coordinated action of the myocardial cells, the squeezing and twisting movements of the heart chambers (particularly the left ventricle) during systole are due to the disposition of cardiac myocytes.

Purkinje cells are modified cardiac muscle cells with fewer contractile filaments. They are specialized for electrical impulse conduction rather than contraction. Purkinje cells are found in the conduction system of the heart.

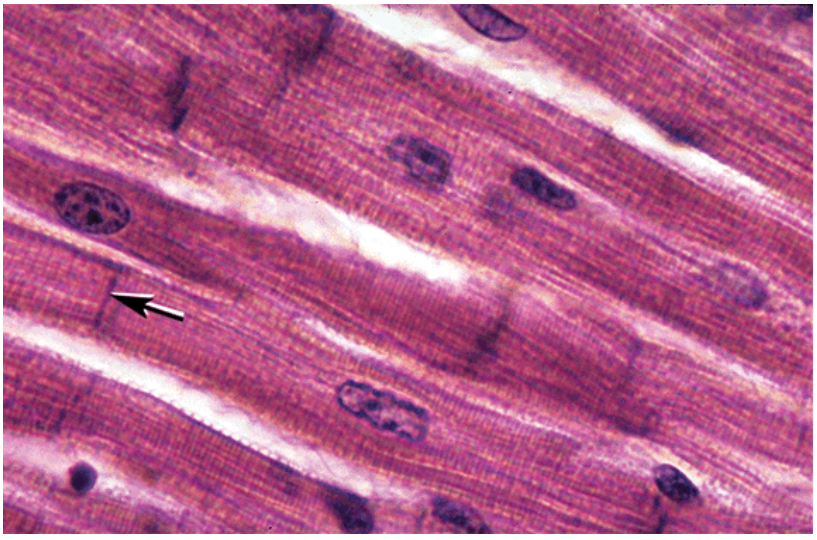

Copyright McGraw-Hill Companies. Used with permission.

Figure II-2-38. Cardiac muscle cells with centrally placed nuclei and intercalated disks (arrow)

Copyright McGraw-Hill Companies. Used with permission.

Figure II-2-39. EM of part of an intercalated disk with gap junction (arrow) adjacent to an adhering junction with intracellular density.

Auscultation of Heart Valves

Points of auscultation of the **semilunar valves** (aortic and pulmonary) and the **atrioventricular valves** (tricuspid and mitral or bicuspid) are shown below. The first heart sound occurs at the closure of the atrioventricular valves at the beginning of systole and the second heart sound occurs at the closure of the aortic and pulmonary semilunar valves at the end of systole.

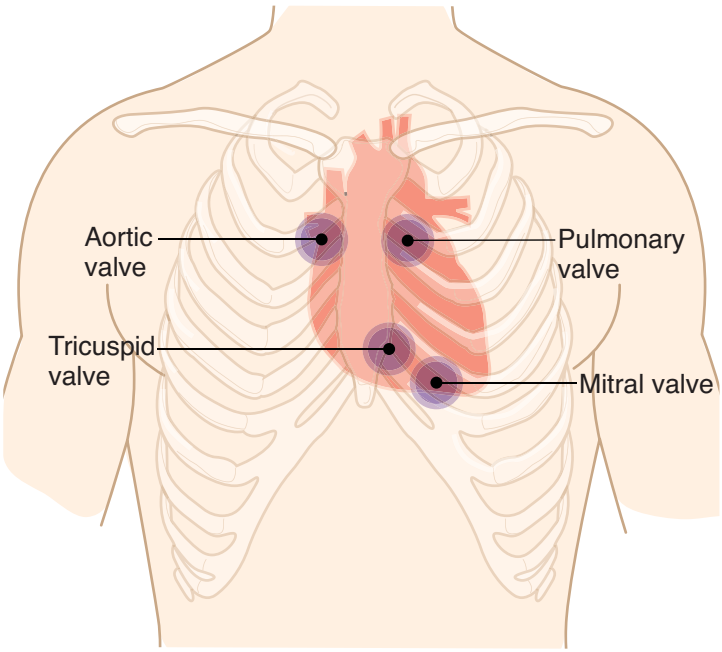

Figure II-2-40. Surface Projections of the Heart

Heart Murmurs

Murmurs in valvular heart disease result when there is **valvular insufficiency or regurgitation** (the valves fail to close completely) or **stenosis** (narrowing of the valves). The **aortic and mitral valves** are more commonly involved in valvular heart disease.

Valves of the Heart

- **Atrioventricular**
  Right heart: tricuspid
  Left heart: bicuspid
- **Semilunar**
  Aortic (3 cusps)
  Pulmonary (3 cusps)

For most of ventricular systole, the mitral valve should be closed and the aortic valve should be open, so that "common **systolic** valvular defects" include **mitral insufficiency** and **aortic stenosis**. For most of ventricular diastole, the mitral valve should be open and the aortic valve should be closed, so that "common **diastolic** valvular defects" include **mitral stenosis** and **aortic insufficiency**.

A heart murmur is heard downstream from the valve. Thus, stenosis is orthograde direction from valve and insufficiency is retrograde direction from valve.

Auscultation sites for mitral and aortic murmurs are shown in Figure II-2-41.

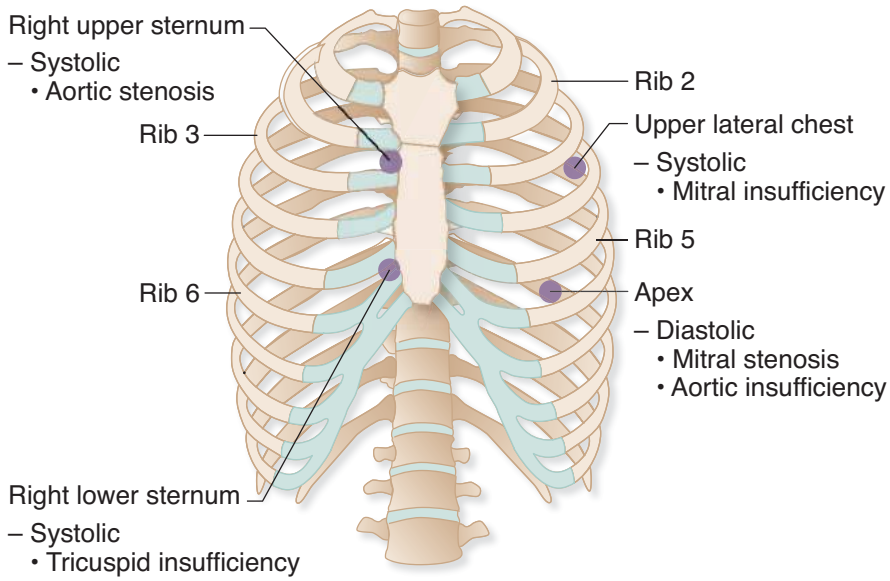

Figure II-2-41. Auscultation of Heart Murmurs

Table II-2-4. Heart Murmurs

	Stenosis	Insufficiency
A-V Valves Tricuspid (right) Mitral (left)	Diastolic murmur	Systolic murmur
Outflow Valves Pulmonic (right) Aortic (left)	Systolic murmur	Diastolic murmur

Arterial Supply of the Heart

The blood supply to the myocardium is provided by branches of the **right and left coronary arteries**. These 2 arteries are the only branches of the ascending aorta and arise from the **right and left aortic sinuses of the ascending aorta**, respectively. Blood flow enters the coronary arteries during diastole.

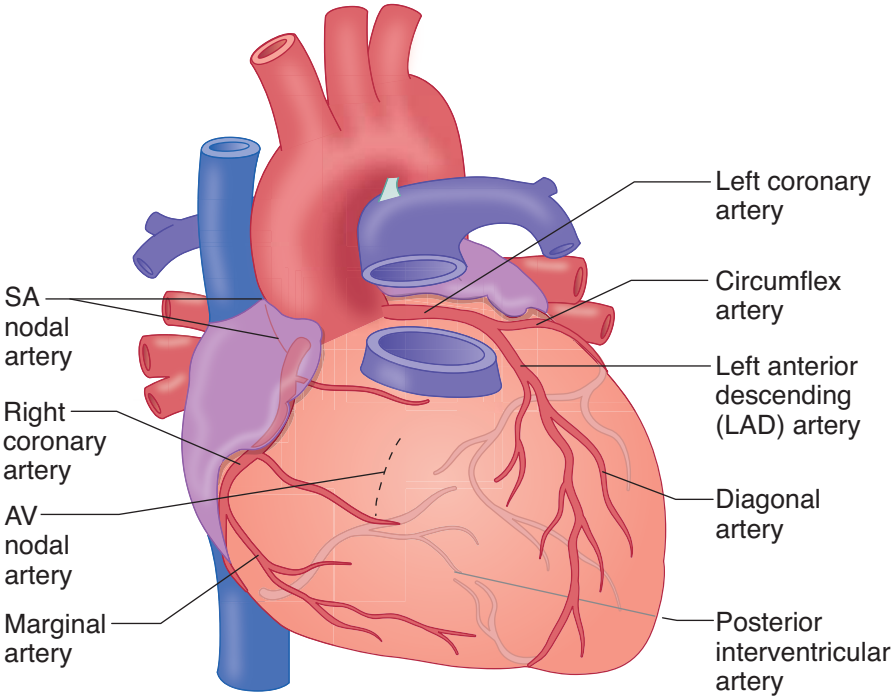

Figure II-2-42. Arterial Supply to the Heart

Right coronary artery

The **right coronary artery** courses in the coronary sulcus and supplies major parts of the right atrium and the right ventricle. The branches include the following:

- **Sinoatrial (SA) nodal artery:** One of the first branches of the right coronary, it encircles the base of the superior vena cava to supply the **SA node**.
- **Atrioventricular (AV) nodal artery:** It arises from the distal end of the right coronary artery as it forms the posterior interventricular artery and penetrates the interatrial septum to supply the **AV node**.
- **Posterior interventricular artery:** It is the terminal distribution of the right coronary artery and courses in the posterior interventricular sulcus to supply parts of the right and left ventricles and, importantly, **the posterior third** of the interventricular septum.

Left coronary artery

The **left coronary artery** travels a short course between the left auricle and ventricle, and divides into 2 branches: **anterior interventricular or left anterior descending (LAD) artery** and **circumflex artery**.

- The **anterior interventricular artery** descends in the anterior interventricular sulcus and provides branches to the (1) **anterior left ventricle wall**, (2) **anterior two-thirds of the interventricular septum**, (3) **bundle of His**, and (4) **apex**. The LAD is the most common site of coronary occlusion.

Clinical Correlate

In myocardial infarction, the left anterior descending artery is obstructed in 50% of cases, the right coronary in 30%, and the circumflex artery in 20% of cases.

- The **circumflex artery** courses around the left border of the heart in the coronary sulcus and supplies (1) the **left border of the heart** via the **marginal branch** and (2) ends on the posterior aspect of the left ventricle and supplies the **posterior-inferior** left ventricular wall.

Venous Drainage of the Heart

The major cardiac veins draining the heart course in the sulci and accompany the arteries but do not carry the same names. The major veins are the following:

- **Coronary sinus** is the main vein of the coronary circulation; it lies in the posterior coronary sulcus and drains to an opening in the right atrium. It develops from the **left sinus venosus**.
- **Great cardiac vein** lies in the anterior interventricular sulcus with the LAD artery; it is the main tributary of the coronary sinus.
- **Middle cardiac vein** lies in the posterior interventricular sulcus with the posterior interventricular artery; it joins the coronary sinus.
- **Venae cordis minimae (thebesian veins) and anterior cardiac veins** open directly to the chambers of the heart.

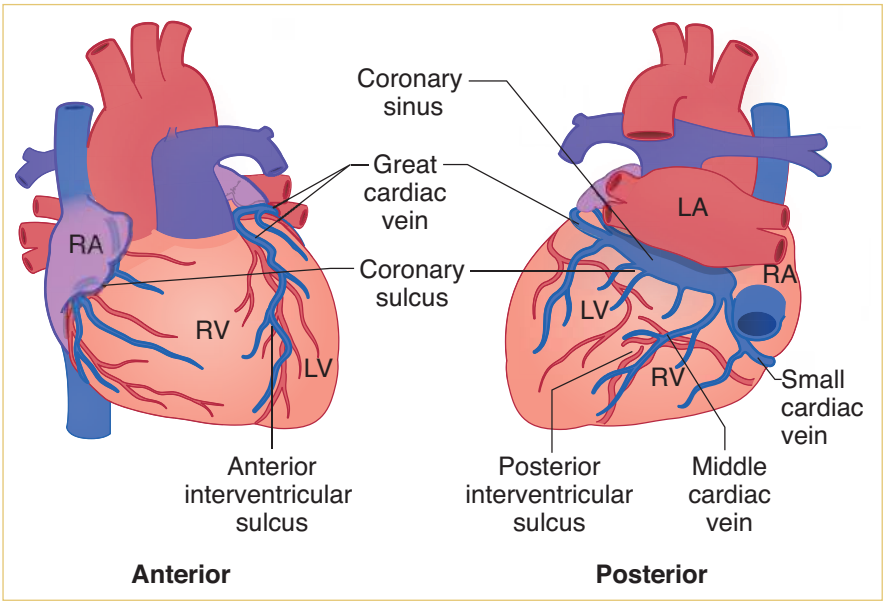

Figure II-2-43. Venous Drainage of the Heart

Conducting System of the Heart

The **cardiac conduction system** is a specialized group of myocardial cells that initiates the periodic contractions of the heart due to their ability to depolarize at a faster rate than other cardiac myocytes. Electrical activity spreads through the walls of the atria from the SA node and is quickly passed by way of internodal fibers to the atrioventricular node. From the atrioventricular node, activity passes through the bundle of His and then down the right and left bundle branches in the interventricular septum. The bundle branches reach additional

specialized cardiac muscle fibers known as Purkinje fibers in the ventricular walls.

- The Purkinje fibers run in several bundles along the endocardial surface and initiate ventricle activity starting at the apex of the ventricles.
- Purkinje fibers have a large cross section, a cytoplasm with few contractile fibrils and a large content of glycogen.

The **SA node** initiates the impulse for contraction of heart muscle (and is therefore termed the "pacemaker" of the heart). It is located at the superior end of the crista terminalis, where the superior vena cava enters the right atrium.

- The SA node is supplied by the SA nodal branch of the **right coronary artery**.
- Impulse production is speeded up by sympathetic nervous stimulation; it is slowed by parasympathetic (vagal) stimulation.

The **AV node** receives impulses from the SA node; it is located in the interatrial septum near the opening of the coronary sinus. The AV node slows the impulse so that it reaches the ventricles after it has reached the atria.

- The AV node is supplied by the **right coronary artery**.

The **bundle of His** originates in the AV node. It conducts impulses to the right and left ventricles. It is supplied by the **LAD artery**.

- In the right ventricle, the moderator band (septomarginal trabecula) contains the right bundle branch.
- Impulses pass from the right and left bundle branches to the papillary muscles and ventricular myocardium.

Innervation

The cardiac plexus is a combination of sympathetic and parasympathetic (vagal) fibers.

- **Sympathetic** stimulation increases the heart rate. Nerves that sense **pain** associated with coronary artery ischemia (angina) follow the **sympathetic pathways** back into spinal cord segments T1–T5.
- **Parasympathetic** stimulation slows the heart rate. Sensory nerves that carry the afferent limb of cardiac **reflexes** travel with the **vagus nerve**.

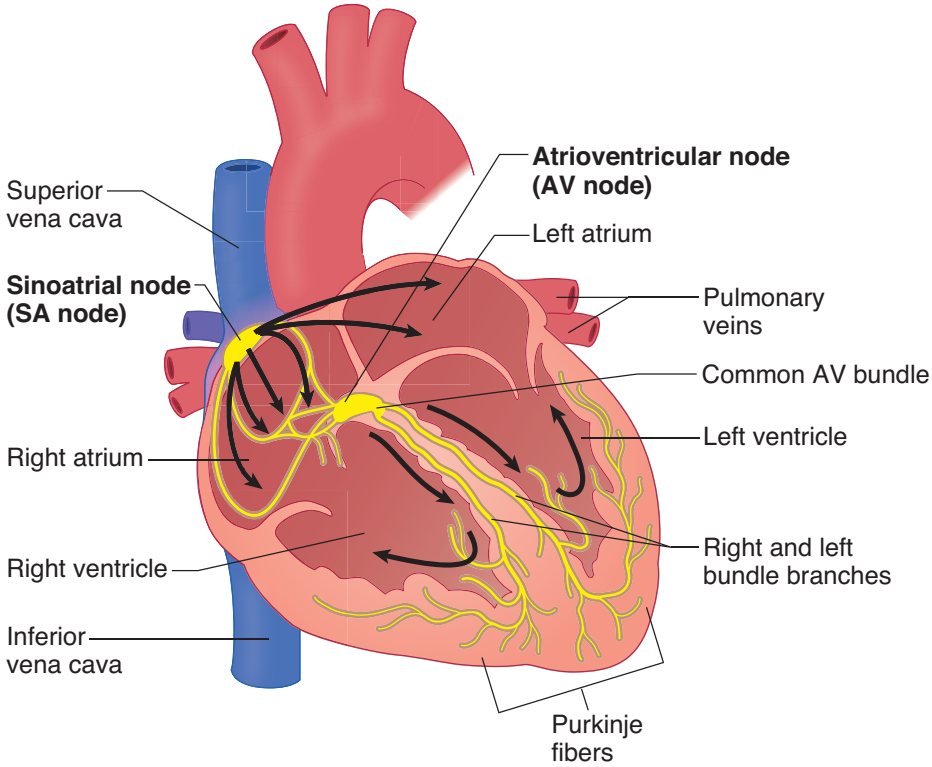

Figure II-2-44. Cardiac Conduction System

DIAPHRAGM

The diaphragm is composed of a muscular portion and a central tendon. It is dome-shaped, and descends upon contraction of its muscular portion. It is innervated by the **phrenic nerves** that arise from spinal cord segments **C3 through C5**.

The diaphragm is formed by the fusion of tissue from 4 sources:

- The septum transversum gives rise to the central tendon of the diaphragm.
- The pleuroperitoneal membranes give rise to parts of the tendinous portion of the diaphragm.
- The dorsal mesentery of the esophagus gives rise to the crura of the diaphragm.
- The body wall contributes muscle to the periphery of the diaphragm.

Apertures in the Diaphragm

Caval hiatus is located to the right of the midline at the level of T8, within the central tendon. It transmits the inferior vena cava and some branches of the right phrenic nerve.

Esophageal hiatus is located to the left of the midline at the level of T10, within the muscle of the right crus. It transmits the esophagus and the anterior and posterior vagus trunks.

Aortic hiatus is located in the midline at the level of T12, behind the 2 crura. It transmits the aorta and thoracic duct.

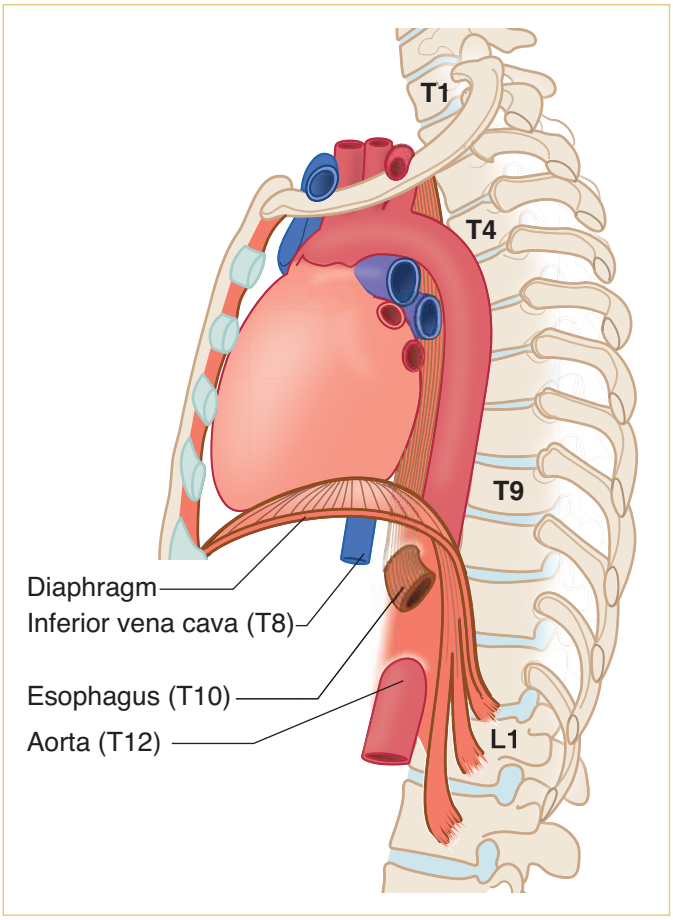

Figure II-2-45. The Diaphragm

Clinical Correlate

Pain Referral

Because the innervation to the diaphragm (motor and sensory) is primarily from C3 through C5 spinal nerves, pain arising from the diaphragm (e.g., subphrenic access) is referred to these dermatomes in the shoulder region.

Clinical Correlate

A **congenital diaphragmatic hernia** is a herniation of abdominal contents into the pleural cavity due to the failure of the **pleuroperitoneal membranes** to develop properly. The hernia is most commonly found on the left posterolateral side and causes pulmonary hypoplasia.

An **esophageal hiatal hernia** is a herniation of the stomach into the pleural cavity due to an abnormally large esophageal hiatus to the diaphragm. This condition renders the esophagogastric sphincter incompetent so that contents reflux into the esophagus.

RADIOLOGY

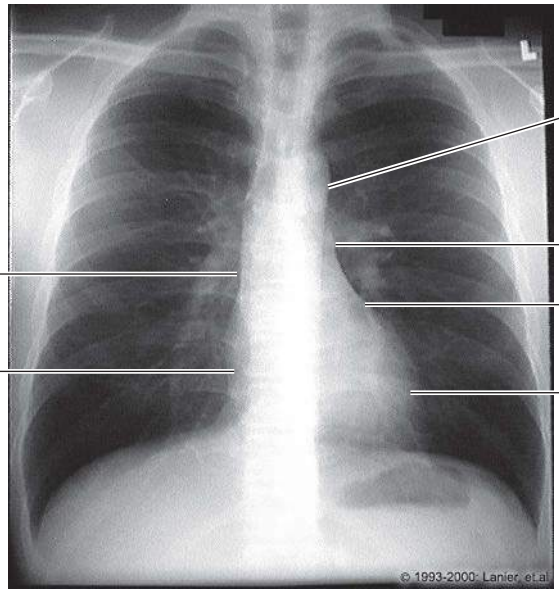

From the IMC, © 2010 DxR Development Group, Inc.
All rights reserved.

Figure II-2-46. Anterior Projection of Chest, Male

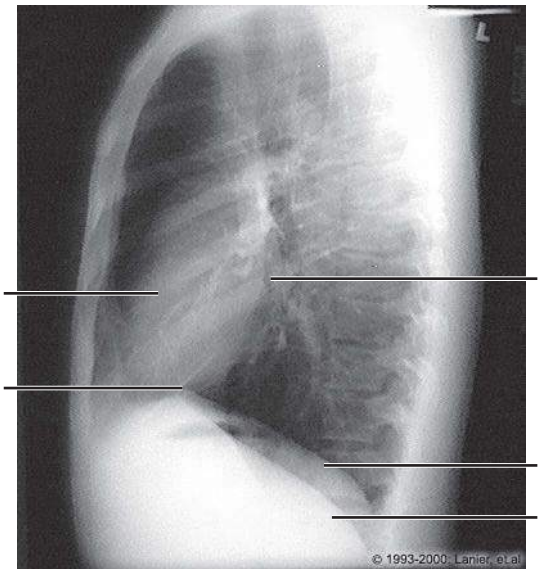

From the IMC, © 2010 DxR Development Group, Inc.
All rights reserved.

Figure II-2-47. Lateral Projection of Chest, Male

From the IMC, © 2010 DxR Development Group, Inc.
All rights reserved.

Figure II-2-48. Chest: CT, T2

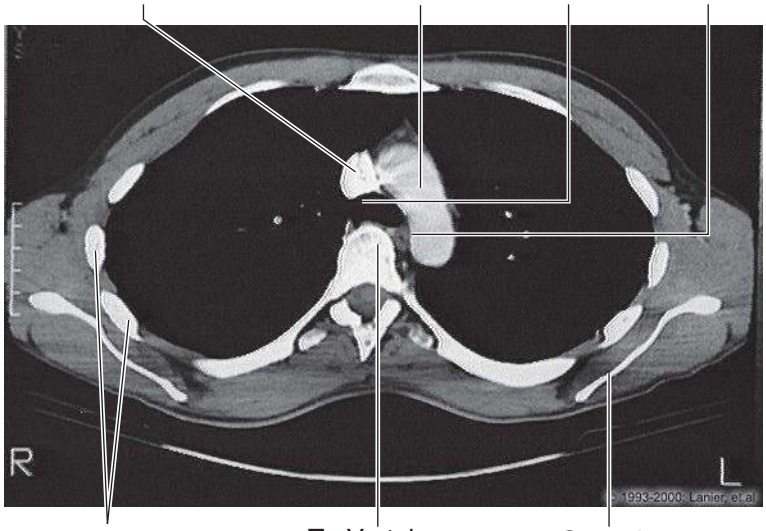

From the IMC, © 2010 DxR Development Group, Inc.
All rights reserved.

Figure II-2-49. Chest: CT, T3

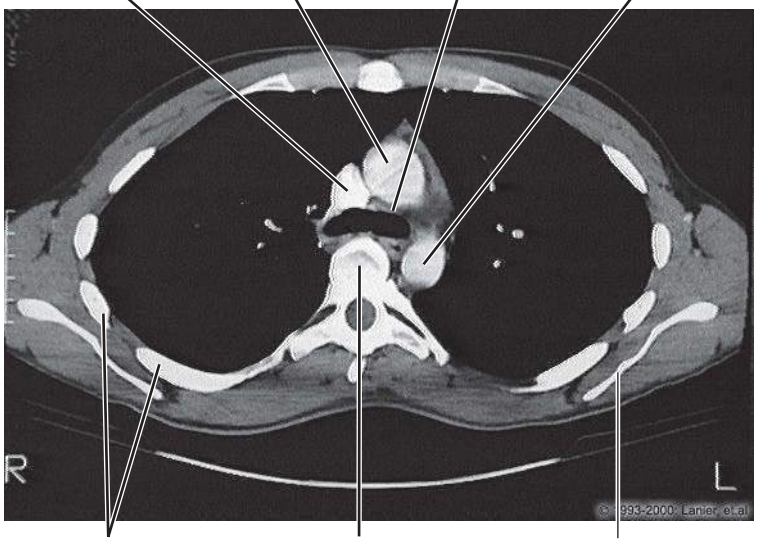

From the IMC, © 2010 DxR Development Group, Inc. All rights reserved.

Figure II-2-50. Chest: CT, T4

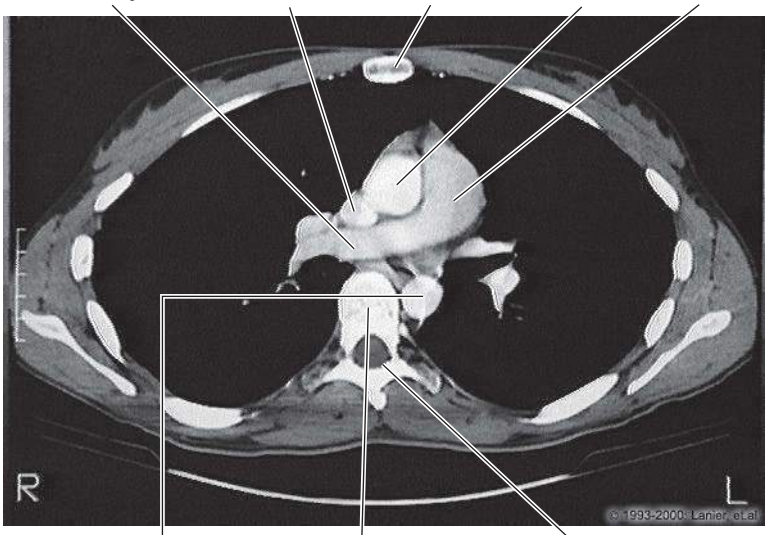

From the IMC, © 2010 DxR Development Group, Inc. All rights reserved.

Figure II-2-51. Chest: CT, T5

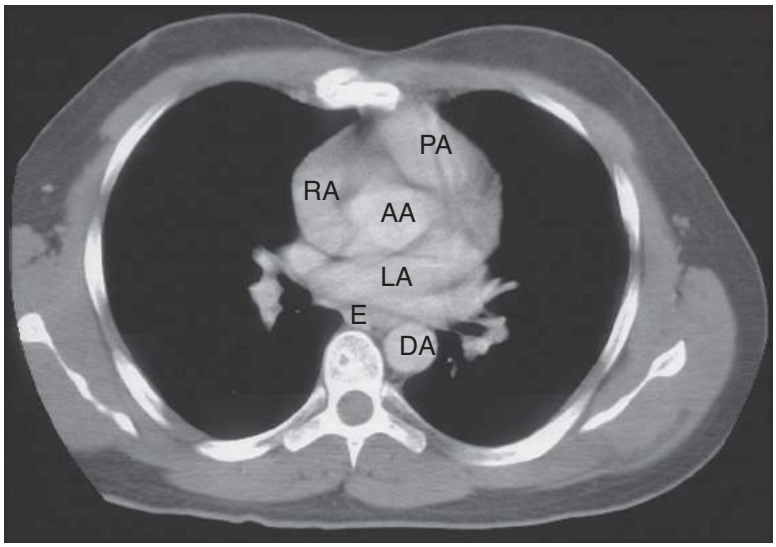

Copyright Lippincott Williams & Wilkins. Used with permission.

PA = pulmonary artery

RA = right atrium

AA = ascending aorta

LA = left atrium

E = esophagus

DA = descending aorta

Figure II-2-52. Chest: CT, T5

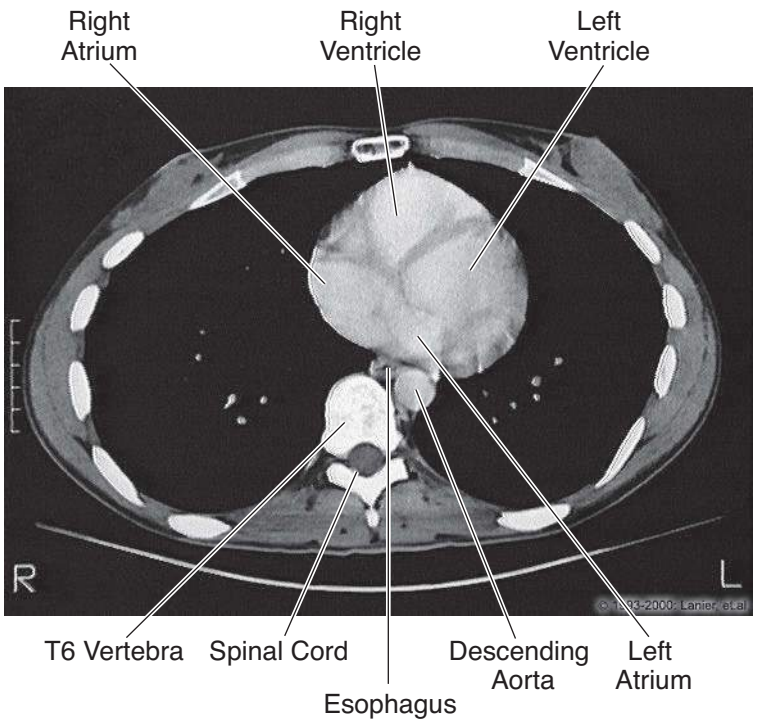

From the IMC, © 2010 DxR Development Group, Inc. All rights reserved.

Figure II-2-53. Chest: CT, T6

Abdomen, Pelvis, and Perineum 3

Learning Objectives

- ❑ Explain information related to inguinal region and canal
- ❑ Answer questions about embryology of the GI system
- ❑ Solve problems concerning peritoneum
- ❑ Answer questions about GI histology, innervation, and immune functions
- ❑ Solve problems concerning arterial supply and venous drainage to abdominal viscera
- ❑ Explain information related to posterior abdominal body wall
- ❑ Answer questions about urinary histology and function
- ❑ Use knowledge of male and female reproductive histology
- ❑ Demonstrate understanding of radiology of the abdomen and pelvis

ANTERIOR ABDOMINAL WALL

Surface Anatomy

The **linea alba** is a shallow groove that runs vertically in the median plane from the xiphoid to the pubis. It separates the right and left rectus abdominis muscles. The components of the rectus sheath intersect at the linea alba.

The **linea semilunaris** is a curved line defining the lateral border of the rectus abdominis, a bilateral feature.

Planes and Regions

The anterior abdominal wall is divided into 9 regions separated by several planes and lines.

The **subcostal plane** (horizontal) passes through the inferior margins of the 10th costal cartilages at the level of the third lumbar vertebra.

The **transpyloric plane** passes through the L1 vertebra, being half the distance between the pubis and the jugular notch. The plane passes through several important abdominal landmarks useful for radiology: pylorus of the stomach (variable), fundus of gallbladder, neck and body of the pancreas, hila of kidneys, first part of the duodenum, and origin of the superior mesenteric artery.

The **midclavicular lines** (vertical) are the 2 planes that pass from the midpoint of the clavicle to the midpoint of the inguinal ligament on each side.

RH: right hypochondrium

LH: left hypochondrium

RL: right lumbar

LL: left lumbar

RI: right inguinal

LI: left inguinal

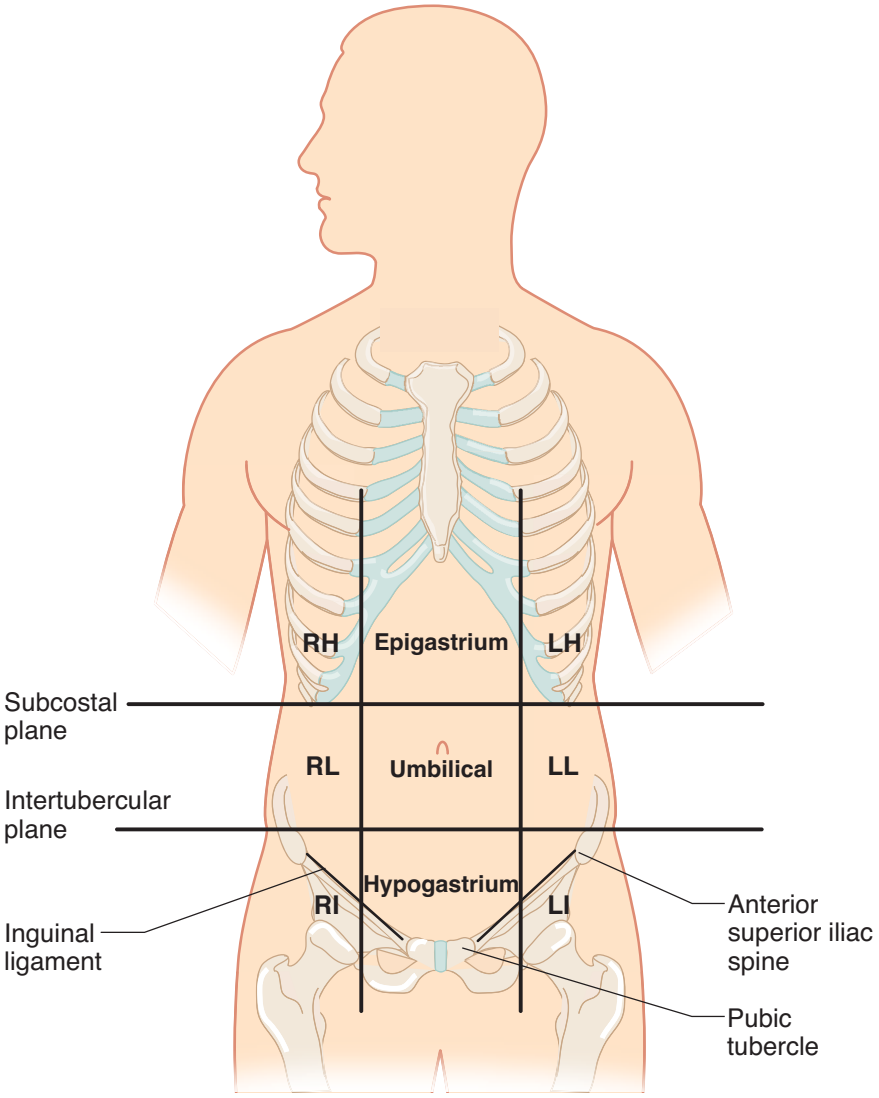

Figure II-3-1. Regions and Planes of the Abdomen

MUSCLES AND FASCIAE OF ANTERIOR BODY WALL

The anterolateral abdominal body wall is a multilayer of fat, fasciae, and muscles (with their aponeuroses) that support and protect the abdominal contents. Three flat abdominal muscles are arranged in layers and the rectus abdominis is oriented vertically adjacent to the midline, extending between the costal margin and the pubis. Abdominal muscles are important in respiration, defecation, micturition, childbirth, etc.

Layers of Anterior Abdominal Wall

The layers of tissue that make up the abdominal wall are described superficial to deep.

Skin

Superficial fascia of the anterior abdominal wall below the umbilicus consists of 2 layers:

- **Camper** (fatty) fascia is the outer, subcutaneous layer of superficial fascia that is variable in thickness owing to the presence of fat.
- **Scarpa** (membranous) fascia is the deeper layer of superficial fascia devoid of fat. It is continuous into the perineum with various perineal fascial layers (Colles' fascia, dartos fascia of the scrotum, superficial fascia of the clitoris or penis).

Muscles

The **external abdominal oblique muscle and aponeurosis** is the most superficial of the 3 flat muscles of the abdominal wall. Its contributions to the abdominal wall and inguinal region are the following:

- **Inguinal ligament** is the inferior rolled under aponeurotic fibers of the external oblique that extend between the anterior superior iliac spine and the pubic tubercle. Medially, the fibers of the inguinal ligament form a flattened horizontal shelf called the **lacunar ligament** that attaches deeply to the pectineal line of the pubis and continues as the pectineal ligament. Lacunar ligament forms the medial border of a femoral hernia.
- **Superficial inguinal ring** is a vertical triangular cleft in the external oblique aponeurosis that represents the medial opening of the inguinal canal just superior and lateral to the pubic tubercle. It transmits the structures of the female and male inguinal canals.
- **External spermatic fascia** is the outer layer of the 3 coverings of the spermatic cord formed at the superficial inguinal ring in males.
- **Rectus sheath**: The external aponeuroses contribute to the anterior layer of the rectus sheath.

Note

Anterior Abdominal Wall Layers

- Skin
- Superficial fascia
  - Camper (fatty)
  - Scarpa (fibrous)
- External oblique
- Internal oblique
- Transversus abdominis
- Transversalis fascia
- Extraperitoneal connective tissue
- Parietal peritoneum

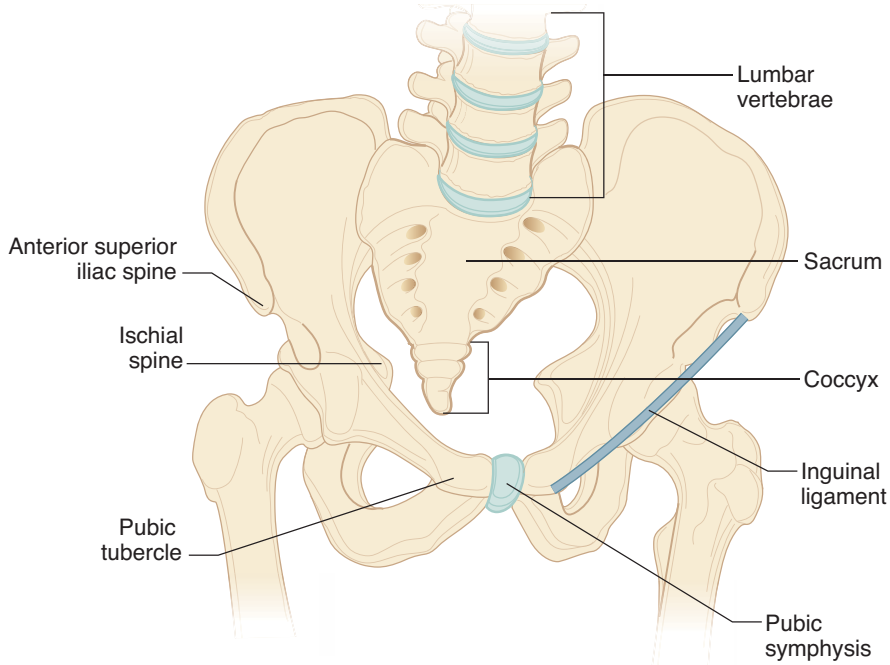

Figure II-3-2. Osteology of the Abdominopelvic Cavity

Internal abdominal oblique muscle and aponeurosis: This middle layer of the 3 flat muscles originates, in part, from the lateral two-thirds of the inguinal ligament. The internal oblique fibers course medially and arch over the inguinal canal in parallel with the arching fibers of the transversus abdominis muscle. The contributions of the internal abdominal oblique to the abdominal wall and inguinal region are the following:

- **Conjoint tendon (falx inguinalis**) is formed by the combined arching fibers of the internal oblique and the transversus abdominis muscles that insert on the pubic crest posterior to the superficial inguinal ring.
- **Rectus sheath:** The internal aponeuroses contribute to the layers of the rectus sheath.
- **Cremasteric muscle and fascia** represent the middle layer of the spermatic fascia covering the spermatic cord and testis in the male. It forms in the inguinal canal.

Transversus abdominis muscle and aponeurosis: This is the deepest of the flat muscles. The transversus muscle originates, in part, from the lateral one-third of the inguinal ligament and arches over the inguinal canal with the internal oblique fibers to contribute to the **conjoint tendon**. The aponeuroses of the transversus muscle also contribute to the layers of the rectus sheath. It does not contribute to any of the layers of the spermatic fasciae.

Abdominopelvic Fasciae and Peritoneum

Transversalis fascia: This fascia forms a continuous lining of the entire abdominopelvic cavity. Its contributions to the inguinal region include the following:

- **Deep inguinal ring** is formed by an outpouching of the transversalis fascia immediately above the midpoint of the inguinal ligament and represents the lateral and deep opening of the inguinal canal. The **inferior epigastric vessels** are **medial** to the deep ring.
- **Internal spermatic fascia** is the deepest of the coverings of the spermatic cord formed at the deep ring in the male.
- **Femoral sheath** is an inferior extension of the transversalis fascia deep to the inguinal ligament into the thigh containing the femoral artery and vein and the femoral canal (site of femoral hernia).
- **Rectus sheath**: The transversalis fascia contributes to the posterior layer of the rectus sheath.

Extraperitoneal connective tissue is a thin layer of loose connective tissue and fat surrounding the abdominopelvic cavity, most prominent around the kidneys. The **gonads** develop from the urogenital ridge within this layer.

Parietal peritoneum is the outer serous membrane that lines the abdominopelvic cavity.

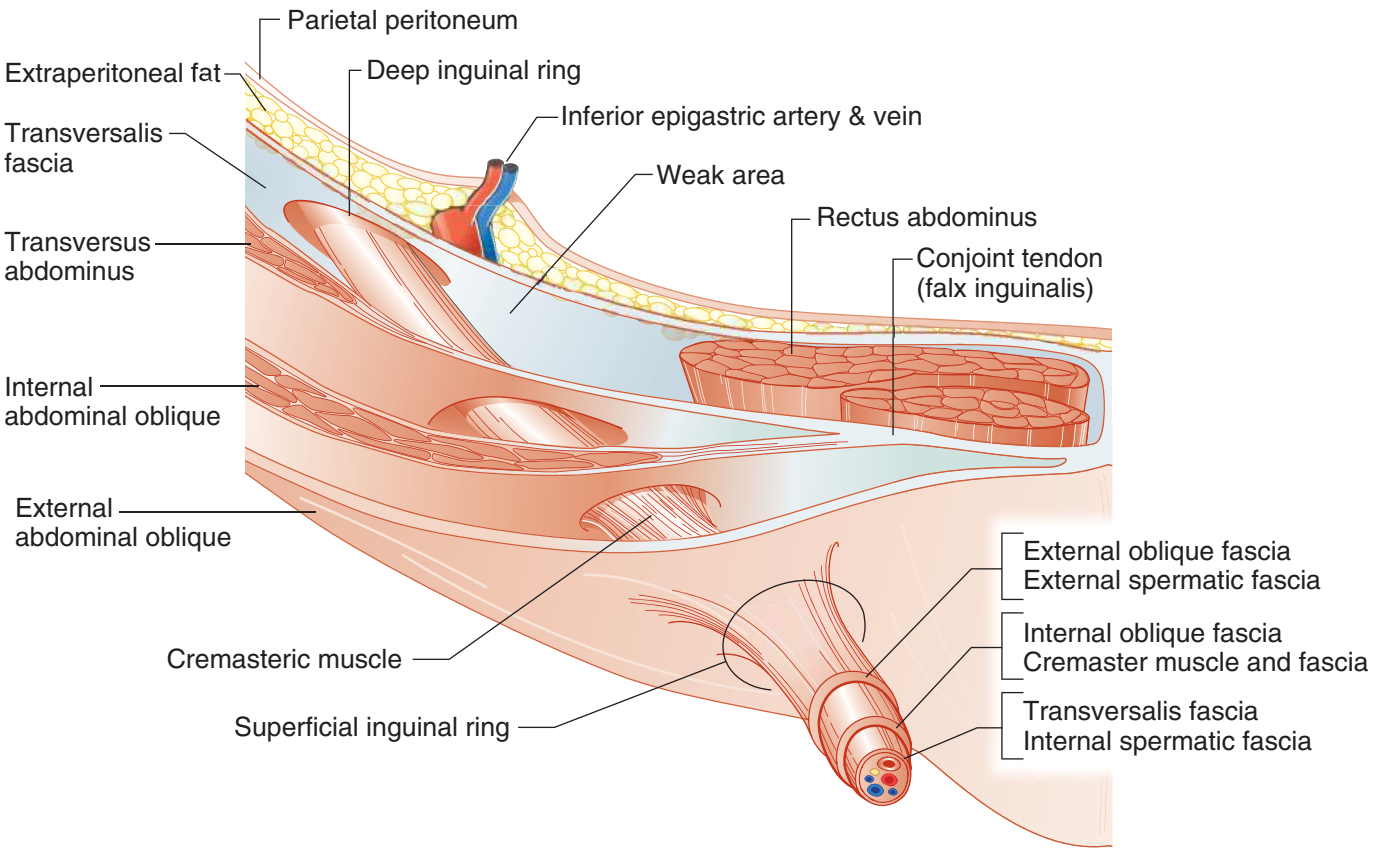

Figure II-3-3. Layers of Anterolateral Abdominal Wall and Inguinal Canal

Nerves, Blood Vessels, and Lymphatics of Abdominal Wall

Innervation of the skin and musculature of the anterior abdominal wall is via branches of the ventral primary rami of the lower 6 thoracic spinal nerves (includes the subcostal nerve), plus the iliohypogastric and ilioinguinal branches of the ventral primary rami of L1.

The major **arterial blood supply** to the anterior wall is derived from the superior epigastric branch of the internal thoracic artery, as well as the inferior epigastric and the deep circumflex iliac branches of the external iliac artery.

Venous drainage from the anterior wall is to the superficial epigastric, the lateral thoracic veins superiorly and the great saphenous vein inferiorly.

Lymph drainage from tissues of the anterior wall is to axillary nodes superiorly and to superficial inguinal nodes inferiorly.

INGUINAL REGION AND CANAL

The **inguinal canal** is the oblique passageway (approximately 4 cm long) in the lower aspect of the anterior abdominal wall running parallel and superior to the medial half of the inguinal ligament. Clinically, the inguinal region is important because it is the area where inguinal hernias occur.

The entrance into the canal is the **deep inguinal ring**, located just lateral to the inferior epigastric vessels and immediately superior to the midpoint of the inguinal ligament.

The **superficial inguinal ring** is the medial opening of the canal superolateral to the pubic tubercle.

Contents of the Inguinal Canal

Female Inguinal Canal

Round ligament of the uterus extends between the uterus and labia majora, and is a remnant of the caudal genital ligament and the homologue of the gubernaculum testis of the male.

Ilioinguinal nerve (L1), a branch of the lumbar plexus, exits the superficial ring to supply the skin of the anterior part of the mons pubis and labia majora.

Male Inguinal Canal

Ilioinguinal nerve (L1), a branch of the lumbar plexus, exits the superficial ring to supply the skin of the lateral and anterior scrotum.

The spermatic cord is formed during descent of the testis and contains structures that are related to the testis. The cord begins at the deep ring and courses through the inguinal canal and exits the superficial ring to enter the scrotum. The cord contains the following:

- **Testicular artery**, branch of the abdominal aorta that supplies the testis

- **Pampiniform venous plexus**, an extensive network of veins draining the testis located within the scrotum and spermatic cord. The veins of the plexus coalesce to form the testicular vein at the deep ring. The venous plexus assists in the regulation of the temperature of the testis.
- **Vas deferens** (ductus deferens) and its artery
- **Autonomic nerves**
- **Lymphatics:** Lymphatic drainage of the testis will drain into the lumbar (aortic) nodes of the lumbar region and not to the superficial inguinal nodes which drain the rest of the male perineum.

There are **3 fascial components derived from the layers** of the abdominal wall that surround the spermatic cord:

- **External spermatic fascia** is formed by the aponeuroses of the **external abdominal oblique** muscle at the superficial ring.
- **Middle or cremasteric muscle and fascia** are formed by fibers of the **internal abdominal oblique** within the inguinal canal. The cremasteric muscle elevates the testis and helps regulate the thermal environment of the testis.
- **Internal spermatic fascia** is formed by the **transversalis fascia** at the deep ring.

Clinical Correlate

A **varicocele** develops when blood collects in the pampiniform venous plexus and causes dilated and tortuous veins. This may result in swelling and enlargement of the scrotum or enlargement of the spermatic cord above the scrotum. Varicoceles are more prominent when standing because of the blood pooling into the scrotum. A varicocele will reduce in size when the individual is horizontal.

Boundaries of the Inguinal Canal

The **roof** is formed by fibers of the internal abdominal oblique and the transversus abdominis muscles arching over the spermatic cord.

The **anterior wall** is formed by aponeurosis of the external abdominal oblique throughout the inguinal canal and the internal abdominal oblique muscle laterally.

The **floor** formed by **inguinal ligament** throughout the entire inguinal canal and the lacunar ligament at the medial end.

The **posterior wall** is divided into lateral and medial areas:

- **Lateral area** is formed by the **transversalis fascia** and represents the **weak area** of the posterior wall.
- **Medial area** is formed and reinforced by the fused aponeurotic fibers of the internal abdominal oblique and transversus abdominis muscles (**conjoint tendon**).
- **Inferior epigastric artery and vein** ascend the posterior wall just lateral to the weak area and just medial to the deep ring.

Clinical Correlate

Cancers of the **penis** and **scrotum** will metastasize to the **superficial inguinal lymph nodes,** and **testicular cancer** will metastasize to the **aortic (lumbar) nodes**.

Clinical Correlate

In males, a **cremasteric reflex** can be demonstrated by lightly touching the skin of the upper medial thigh, resulting in a slight elevation of the testis. The sensory fibers of the reflex are carried by the L1 fibers of the **ilioinguinal nerve** and the motor response is a function of the genital branch of the **genitofemoral nerve** that innervates the cremasteric muscle.

Descent of the Testes

The testis develops from the mesoderm of the urogenital ridge within the extraperitoneal connective tissue layer. During the last trimester, it descends the posterior abdominal wall inferiorly toward the deep inguinal ring guided by the fibrous **gubernaculum**.

Clinical Correlate

Failure of one or both of the testes to descend completely into the scrotum results in **cryptorchidism,** which may lead to sterility if bilateral.

- An evagination of the parietal peritoneum and the peritoneal cavity extends into the inguinal canal called the **processus vaginalis**. The open connection of the processus vaginalis with the peritoneal cavity closes before birth.
- A portion of the processus vaginalis remains patent in the scrotum and surrounds the testis as the **tunica vaginalis.**

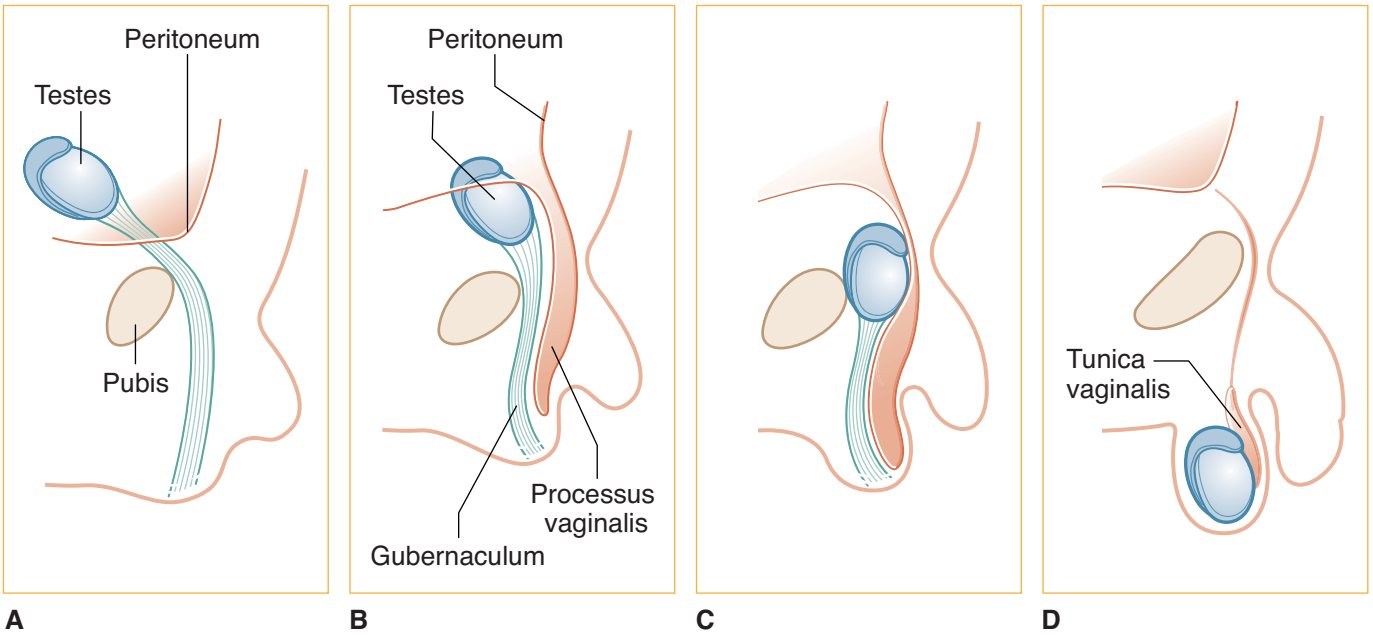

Figure II-3-4. Descent of the Testes

Clinical Correlate

A persistent process vaginalis often results in a **congenital indirect inguinal hernia.**

Clinical Correlate

A collection of serous fluid in the tunica vaginalis forms a **hydrocele**, resulting in an enlarged scrotum. A hydrocele does not reduce in size when the patient is lying down.

Note

Direct hernias are found **medial** to the inferior epigastric vessels, and indirect inguinal hernias occur **lateral** to the inferior epigastric vessels.

Inguinal Hernias

Herniation of abdominal viscera can occur in one of several weak aspects of the abdominal wall (e.g. inguinal, femoral, umbilical, or diaphragmatic). Inguinal hernias are the most common of the abdominal hernias and occur more frequently in males due to the inherent weakness of the male inguinal canal. Inguinal hernias occur superior to the inguinal ligament.

- **Indirect inguinal hernias** result when abdominal contents protrude through the deep inguinal ring **lateral** to the inferior epigastric vessels. After passing through the inguinal canal and superficial ring, the viscera can continue and coil in the scrotum.
  - Indirect hernias follow the route taken by the testis and are found **within** the spermatic cord.
  - They are covered by the 3 layers of spermatic fascia.
- **Direct inguinal hernias** result when the abdominal contents protrude through the weak area of the posterior wall of the inguinal canal **medial** to the inferior epigastric vessels (in the **inguinal [Hesselbach's] triangle**).

- Direct hernias rupture through the posterior wall of the inguinal canal and are usually found on the surface of the spermatic cord and bulge at the superficial ring.
- They may be covered by only the external layer of spermatic fascia.

Clinical Correlate

Direct inguinal hernias usually pass through the **inguinal (Hesselbach's) triangle:**

- **Lateral border:** inferior epigastric vessels
- **Medial border:** rectus abdominis muscle
- **Inferior border:** inguinal ligament

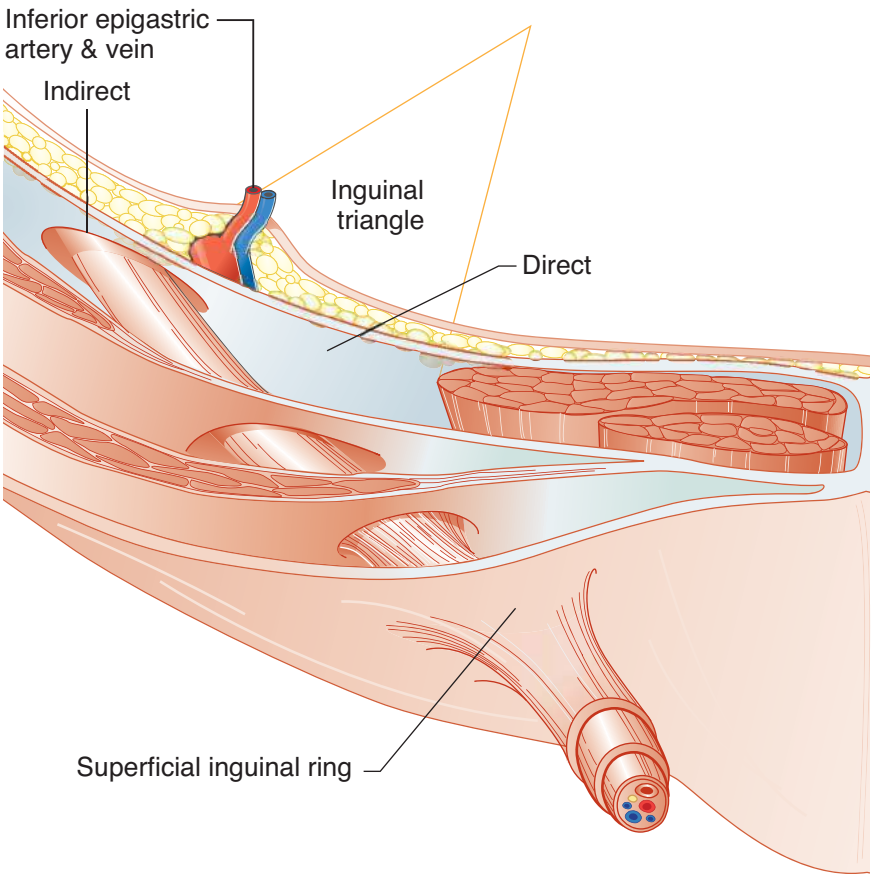

Figure II-3-5. Inguinal Hernia

Note

Both direct and indirect hernias exit through the superficial ring, but only indirect hernias pass through the deep ring.

Clinical Correlate

- Inguinal hernias pass **above** the inguinal ligament.
- Femoral hernias pass **below** the inguinal ligament.

Femoral Hernias

Femoral hernias most often occur in women.

Femoral sheath contains femoral artery, vein, and canal

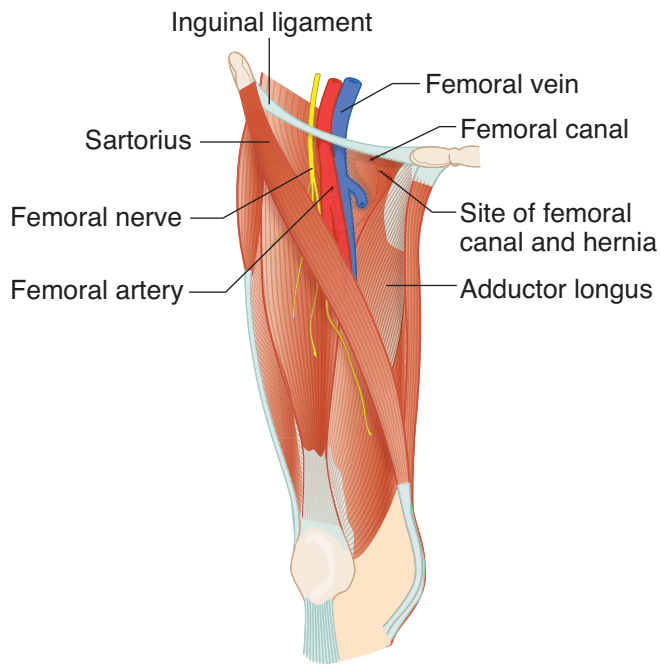

Figure II-3-6. Femoral Hernia

EMBRYOLOGY OF THE GASTROINTESTINAL SYSTEM

Primitive Gut Tube

The primitive gut tube is formed by incorporation of the **yolk sac** into the embryo during 2 body foldings: **head to tail (cranial-caudal)** and **lateral foldings**. While the epithelial lining of the mucosa of the primitive gut tube is derived from **endoderm**, the lamina propria, muscularis mucosae, submucosa, muscularis externa, and adventitia/serosa are derived from **mesoderm**.

The primitive gut tube is divided into **the foregut, midgut, and hindgut**, each supplied by a specific artery and autonomic nerves.

Table II-3-1. Adult Structures Derived from the 3 Divisions of the Primitive Gut Tube

Foregut	Midgut	Hindgut
Artery: celiac **Parasympathetic innervation:** vagus nerves **Sympathetic innervation:** • Preganglionics: thoracic splanchnic nerves, T5–T9 • Postganglionic cell bodies: celiac ganglion	**Artery:** superior mesenteric **Parasympathetic innervation:** vagus nerves **Sympathetic innervation:** • Preganglionics: thoracic splanchnic nerves, T9–T12 • Postganglionic cell bodies: superior mesenteric ganglion	**Artery:** inferior mesenteric **Parasympathetic innervation:** pelvic splanchnic nerves **Sympathetic innervation:** • Preganglionics: lumbar splanchnic nerves, L1–L2 • Postganglionic cell bodies: inferior mesenteric ganglion
Referred Pain: Epigastrium	**Referred Pain:** Umbilical	**Referred Pain:** Hypogastrium
Foregut Derivatives	**Midgut Derivatives**	**Hindgut Derivatives**
Esophagus Stomach Duodenum (first and second parts) Liver Pancreas Biliary apparatus Gallbladder	Duodenum (second, third, and fourth parts) Jejunum Ileum Cecum Appendix Ascending colon Transverse colon (proximal two-thirds)	Transverse colon (distal third—splenic flexure) Descending colon Sigmoid colon Rectum Anal canal (above pectinate line)

Development and Rotation of Foregut

After body foldings and the formation of the gut tube, the foregut is suspended from the dorsal body wall by the **dorsal embryonic mesentery** and from the ventral body wall by the **ventral embryonic mesentery**. Note that the **liver** develops in the ventral embryonic mesentery, and the **spleen** and dorsal pancreatic bud develop in the dorsal embryonic mesentery.

- The abdominal foregut rotates 90° (clockwise) around its longitudinal axis. The original left side of the stomach before rotation becomes the ventral surface after rotation and its anterior and posterior borders before rotation will become the **lesser and greater curvatures**, respectively.
- Foregut rotation results in the liver, lesser omentum (ventral embryonic mesentery), pylorus of the stomach, and duodenum moving to the **right**; and the spleen, pancreas, and greater omentum (dorsal embryonic mesentery) moving to the **left**.
- The ventral embryonic mesentery will contribute to the **lesser omentum** and **the falciform ligament**, both of which attach to the liver.
- The dorsal embryonic mesentery will contribute to the **greater omentum** and the **gastro-splenic** and **splenorenal** ligaments, all of which attach to the spleen or the greater curvature of the stomach.

Note

The lower respiratory tract, liver and biliary system, and pancreas all develop from an **endodermal outgrowth of the foregut**.

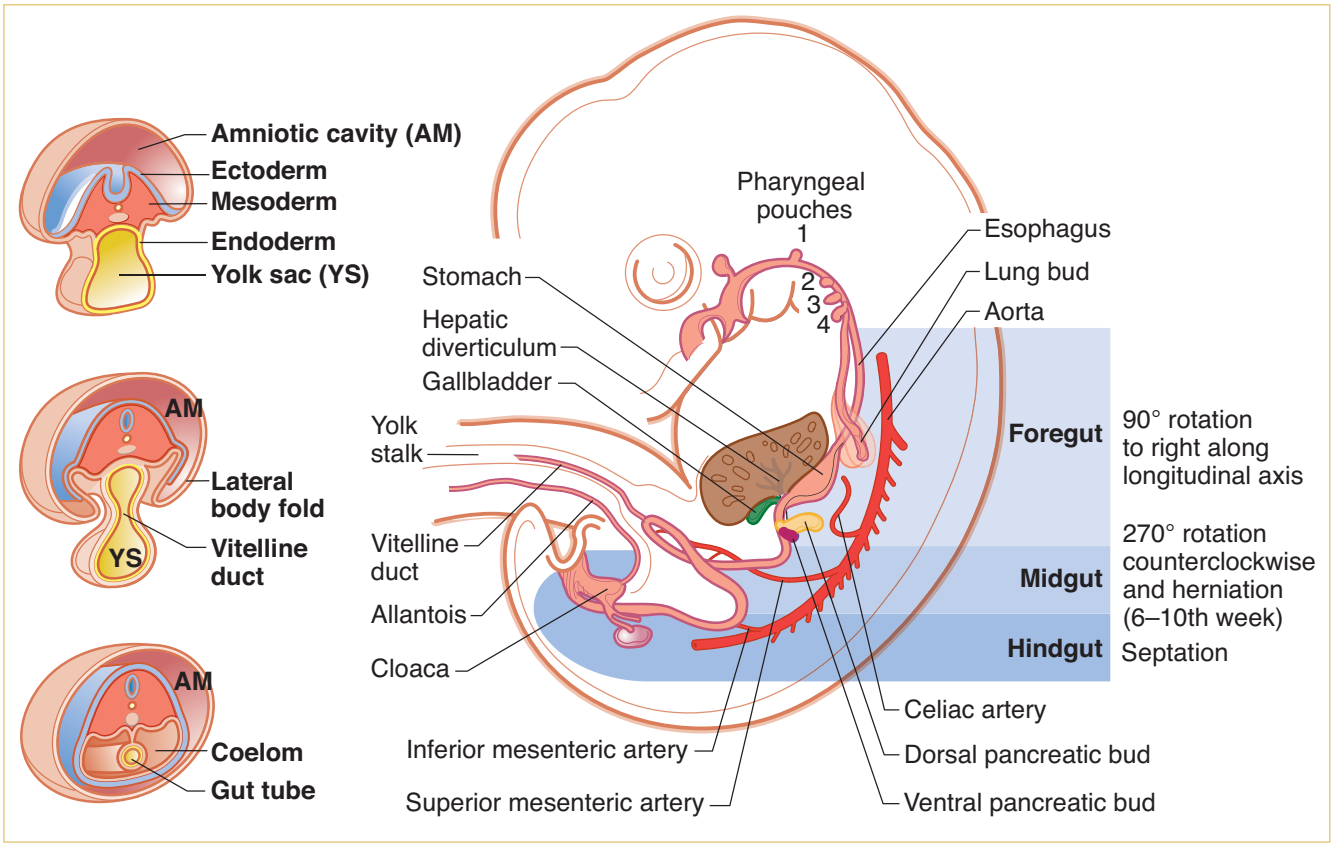

Figure II-3-7A. Development of Gastrointestinal Tract

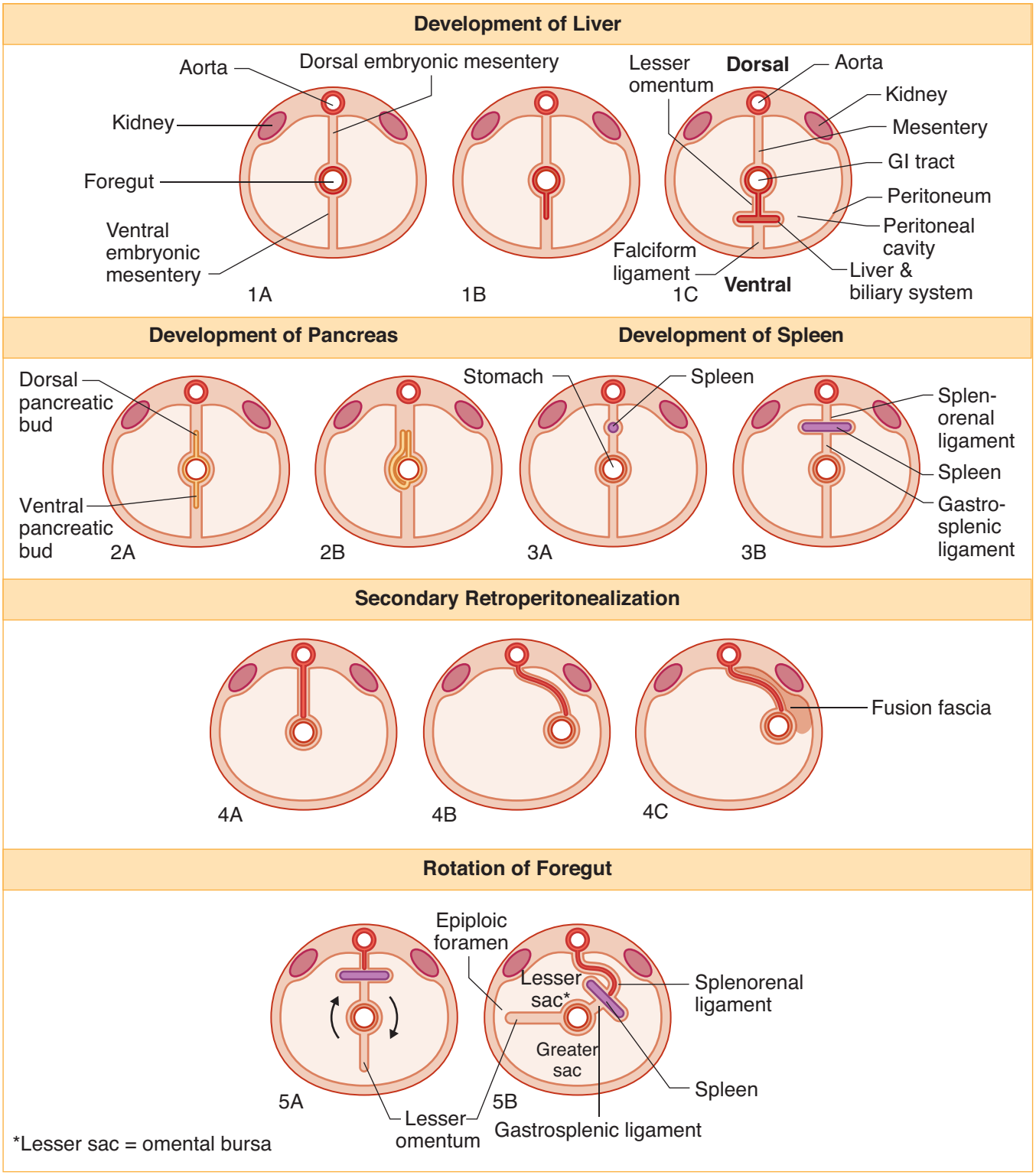

Figure II-3-7B. Cross-Sectional View of Foregut Development and Rotation

Development and Rotation of Midgut

The midgut originally develops from the cranial and caudal intestinal loops. During weeks 6–10, the midgut herniates into the umbilical cord. During herniation into and return from the umbilical cord, the midgut undergoes a 270° counterclockwise rotation around the axis of the **superior mesenteric artery**.

- This rotation results in the jejunum being on the left, and the ileum and cecum being on the right.
- It also causes the colon to assume the shape of an inverted "U."

PERITONEUM

The peritoneum is the serous membrane related to the viscera of the abdominal cavity. It is divided into 2 layers: **parietal** and **visceral**.

Clinical Correlate

Inflammation of the parietal peritoneum (peritonitis) results in sharp pain that is localized over the area.

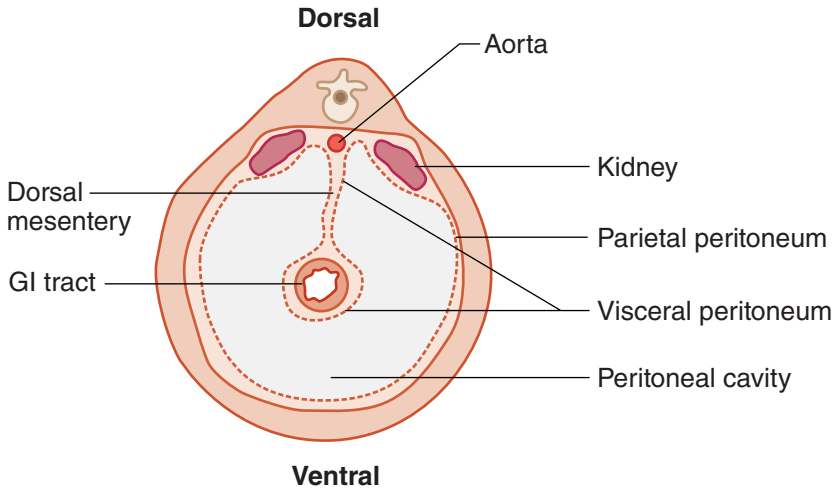

Figure II-3-7C. Peritoneum

The **parietal layer** lines the body wall and covers the retroperitoneal organs on one surface. Parietal peritoneum is very sensitive to somatic pain and is innervated by the lower intercostal nerves and the ilioinguinal and the iliohypogastric nerves of the lumbar plexus.

The **visceral layer** encloses the surfaces of the intraperitoneal organs. The visceral peritoneum usually forms double-layered peritoneal membranes (mesenteries) that suspend parts of the GI tract from the body wall. The mesenteries allow for the passage of vessels, nerves, and lymphatics to reach the GI tract.

Different terms describe the postnatal remnants of mesenteries in the abdomen (Figures II-3-8 and II-3-9):

- **Omentum**: lesser and greater omenta attach to the lesser or greater curvatures of the stomach, respectively
- **Mesocolon**: transverse and sigmoid mesocolon attach to the transverse colon or the sigmoid colon, respectively
- **Ligaments**: reflections of mesenteries between organs or the body wall, named according to their attachments

Peritoneal Cavity

The peritoneal cavity is the potential space located between the parietal and visceral peritoneal layers. The 90° rotation and the shift of the embryonic mesenteries divide the peritoneal cavity into 2 sacs (Figures II-3-7B and II-3-9).

- **The lesser sac (omental bursa)** is a cul-de-sac formed posterior to the stomach and the lesser omentum
- **The greater sac** is formed by the larger area of the remaining peritoneal cavity. The only communication between the lesser sac and the greater sac is the **epiploic foramen (of Winslow)**.

Intraperitoneal versus Retroperitoneal Organs

The abdominal viscera are classified according to their relationship to the peritoneum.

- **Intraperitoneal organs** are suspended by a mesentery and are almost completely enclosed in visceral peritoneum. They are mobile.
- **Retroperitoneal organs** are partially covered on one side with parietal peritoneum. They are immobile or fixed. Many retroperitoneal organs are originally suspended by a mesentery and become secondarily retroperitoneal. In **secondary retroperitonealization,** parts of the gut tube (most of the duodenum, pancreas, ascending colon, descending colon, part of rectum) fuse with the body wall by way of fusion of visceral peritoneum with parietal peritoneum. This causes the organs to become secondarily retroperitoneal (and the visceral peritoneum covering the organ is renamed as the parietal peritoneum). The vessels within the mesentery of these gut structures become secondarily retroperitoneal.

Table II-3-2. Intraperitoneal and Retroperitoneal Organs

Major Intraperitoneal Organs (suspended by a mesentery)	**Major Secondary Retroperitoneal Organs** (lost a mesentery during development)	**Major Primary Retroperitoneal Organs** (never had a mesentery)
Stomach Liver and gallbladder Spleen Duodenum, 1st part Tail of pancreas Jejunum Ileum Appendix Transverse colon Sigmoid colon	Duodenum, 2nd and 3rd parts Head, neck, and body of pancreas Ascending colon Descending colon Upper rectum	Kidneys Adrenal glands Ureters Aorta Inferior vena cava Lower rectum Anal canal

Epiploic Foramen (of Winslow)

The **epiploic foramen** is the opening between omental bursa and greater peritoneal sac (Figures II-3-7B, II-3-8, and II-3-9). The boundaries of the epiploic foramen are the following:

- **Anteriorly:** hepatoduodenal ligament and the hepatic portal vein
- **Posteriorly:** inferior vena cava
- **Superiorly:** caudate lobe of the liver
- **Inferiorly:** first part of the duodenum

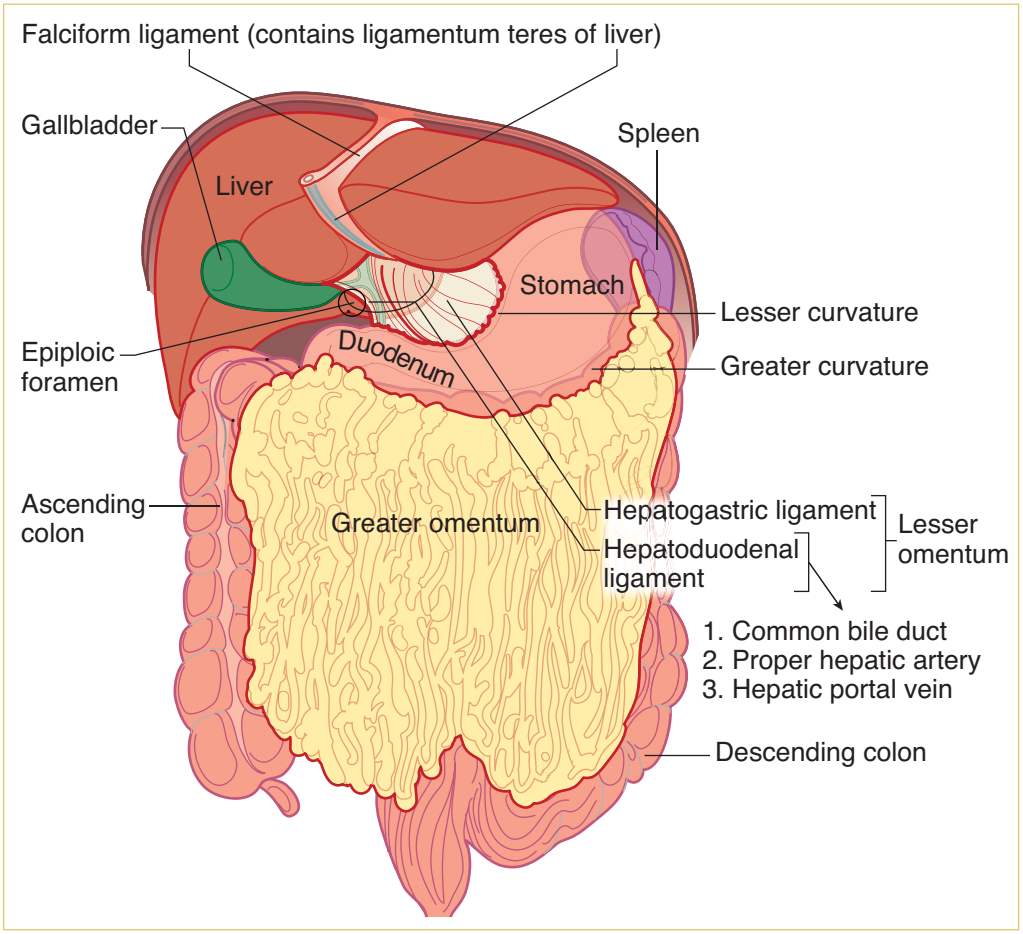

Figure II-3-8. Peritoneal Membranes

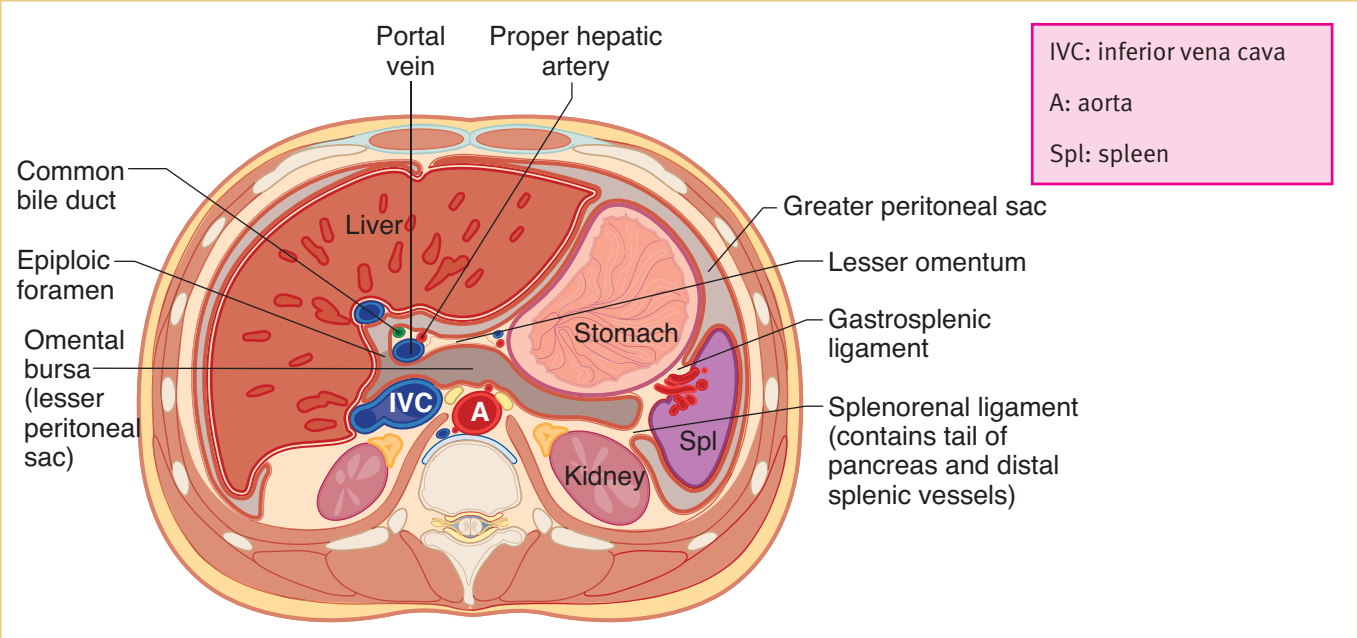

Figure II-3-9. Greater and Lesser Peritoneal Sacs

DEVELOPMENT OF ABDOMINAL VISCERA

Liver

The hepatic diverticulum develops as an outgrowth of the **endoderm** of the foregut in the region of the duodenum near the border between the foregut and the midgut.

- This diverticulum enters the ventral embryonic mesentery and distally becomes the liver and gallbladder and proximately becomes the biliary duct system.
- The part of the ventral embryonic mesentery between the liver and gut tube becomes the **lesser omentum**, and the part between the liver and ventral body wall becomes the **falciform ligament**.

Pancreas

The pancreas develops from 2 pancreatic diverticula (buds), which evaginate from the **endodermal** lining of the foregut in the region of duodenum.

- The ventral bud rotates around the gut tube to fuse with the dorsal bud, together to form a single pancreas.
- The **dorsal pancreatic bud** forms the **neck, body, and tail of the pancreas**.
- The **ventral pancreatic bud** forms the **head and uncinate process**.

Clinical Correlate

A defect in the rotation and fusion of the ventral and dorsal buds results in an **annular pancreas** which can **constrict or obstruct the duodenum** and result **in polyhydramnios**.

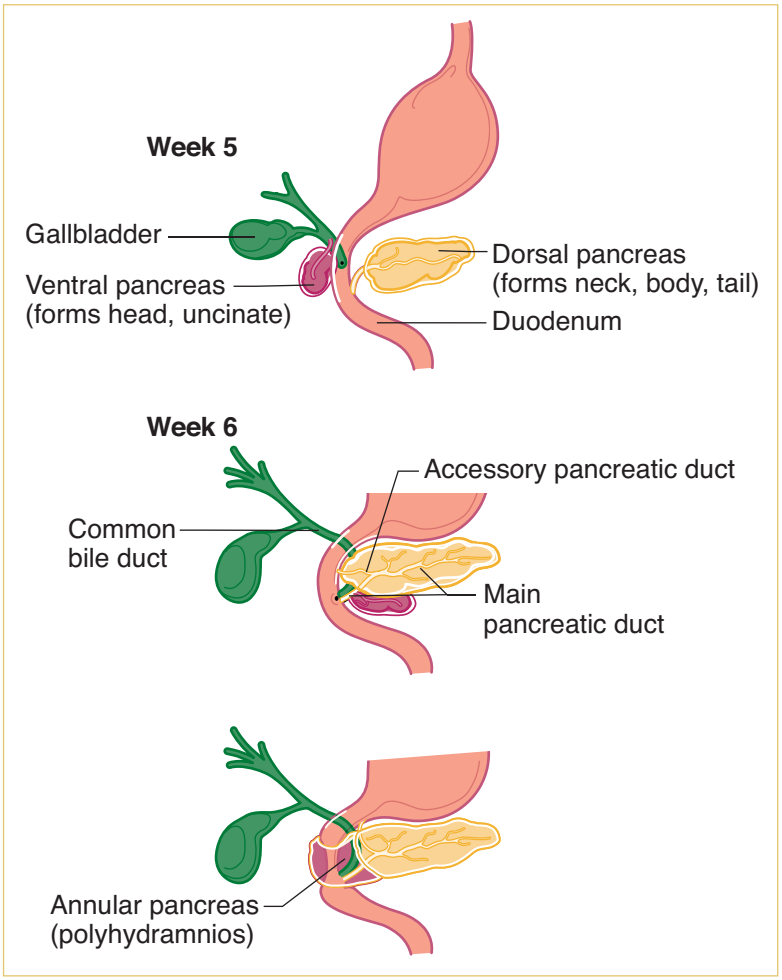

Figure II-3-10. Development of the Pancreas and Duodenum

Spleen

The spleen develops from **mesoderm** within the dorsal embryonic mesentery (Figure II-3-7B). The embryonic mesentery between the spleen and the gut tube becomes the **gastrosplenic ligament**. The mesentery between the spleen and the dorsal body wall becomes the **splenorenal ligament**.

CONGENITAL ABNORMALITIES OF THE GUT TUBE

Hypertrophic pyloric stenosis occurs when the muscularis externa hypertrophies, causing a narrow pyloric lumen. It is associated with **polyhydramnios**; projectile, nonbilious vomiting; and a small knot at the right costal margin.

Extrahepatic biliary atresia occurs when the lumen of the biliary ducts is occluded owing to incomplete recanalization. It is associated with jaundice, white-colored stool, and dark-colored urine.

Annular pancreas occurs when the ventral and dorsal pancreatic buds form a ring around the duodenum, thereby causing an obstruction of the duodenum and polyhydramnios.

Duodenal atresia occurs when the lumen of the duodenum is occluded owing to failed recanalization. It is associated with **polyhydramnios**, bile-containing vomitus, and a distended stomach.

An **omphalocele** occurs when the midgut loop fails to return to the abdominal cavity and remains in the umbilical stalk. The viscera herniate through the **umbilical ring** and are contained in a **shiny sac** of amnion at the base of the umbilical cord. It is often associated with multiple anomalies of the heart and nervous system, with a high mortality rate (25%).

Gastroschisis occurs when the abdominal viscera herniate through the body wall directly into the amniotic cavity, usually to the right of the umbilicus.

- This is a defect in the closure of the lateral body folds and a weakness of the anterior wall.
- Note that the viscera do not protrude through the umbilical ring and are not enclosed in a sac of amnion.

Ileal (Meckel) diverticulum occurs when a remnant of the vitelline duct persists, thereby forming a blind pouch on the antimesenteric border of the ileum. It is often asymptomatic but can become inflamed if it contains ectopic gastric, pancreatic, or endometrial tissue, which may produce ulceration. It is typically found 2 feet from the ileocecal junction, are 2 inches long, and appears in 2% of the population.

Vitelline fistula occurs when the vitelline duct persists, thereby forming a direct connection between the intestinal lumen and the outside of the body at the umbilicus. It is associated with drainage of meconium from the umbilicus.

Malrotation of midgut occurs when the midgut undergoes only partial rotation and results in abnormal position of abdominal viscera. It may be associated with **volvulus** (twisting of intestines).

Colonic aganglionosis (Hirschsprung disease) results from the failure of **neural crest** cells to form the myenteric plexus in the sigmoid colon and rectum. It is associated with loss of peristalsis and immobility of the hindgut, fecal retention and abdominal distention of the transverse colon (megacolon).

ABDOMINAL VISCERA

Liver

The liver has 2 surfaces: a superior or **diaphragmatic** surface and an inferior or a **visceral** surface. It lies mostly in the right aspect of the abdominal cavity and is protected by the rib cage. The liver is invested by visceral peritoneum:

- The reflection of visceral peritoneum between the diaphragmatic surface of the liver and the diaphragm forms the **falciform ligament**, which continues onto the liver as the coronary ligament and the right and left triangular ligaments.
- The extension of visceral peritoneum between the visceral surface of the liver and the first part of the duodenum and the lesser curvature of the stomach forms the **hepatoduodenal and hepatogastric ligaments** of the **lesser omentum**, respectively.

The liver is divided into 2 lobes of unequal size:

- Fissures for the ligamentum teres and the ligamentum venosum, the porta hepatis, and the fossa for the gallbladder further subdivide the right lobe into the right lobe proper, the quadrate lobe, and the caudate lobe.
- The quadrate and caudate lobes are anatomically part of the right lobe but functionally part of the left. They receive their blood supply from the left branches of the portal vein and hepatic artery and secrete bile to the left hepatic duct.

The liver has a central hilus, or porta hepatis, which receives venous blood from the **portal vein** and arterial blood from the **hepatic artery**.

- The central hilus also transmits the common bile duct, which collects bile produced by the liver.
- These structures, known collectively as the portal triad, are located in the hepatoduodenal ligament, which is the right free border of the lesser omentum.

The **hepatic veins** drain the liver by collecting blood from the liver sinusoids and returning it to the inferior vena cava.

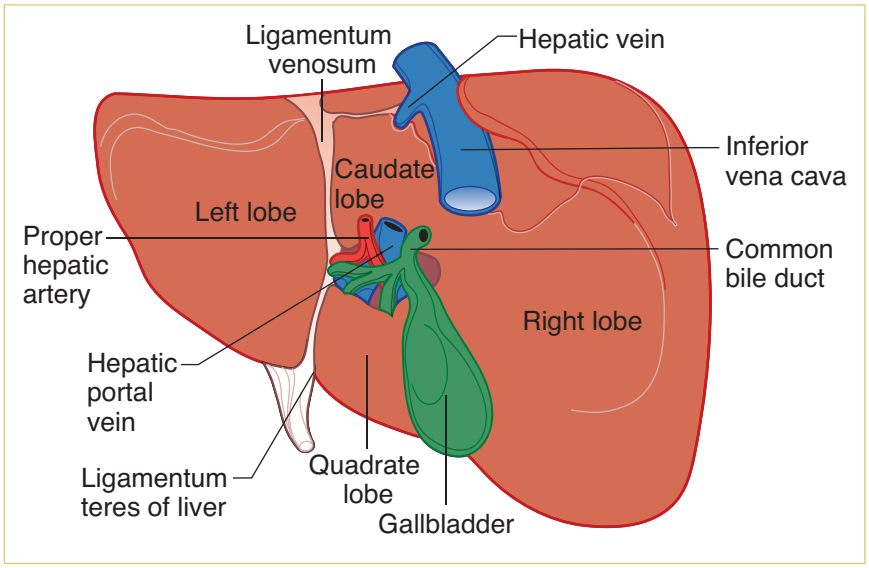

Figure II-3-11. Visceral Surface of the Liver

Gallbladder

The gallbladder lies in a fossa on the visceral surface of the liver to the right of the quadrate lobe. It stores and concentrates bile, which enters and leaves through the cystic duct.

- The cystic duct joins the common hepatic duct to form the **common bile duct**.
- The common bile duct descends in the hepatoduodenal ligament, then passes posterior to the first part of the duodenum. The common bile duct

penetrates the head of the pancreas where it joins the main pancreatic duct and forms the **hepatopancreatic ampulla,** which drains into the second part of the duodenum at the **major duodenal papilla**.

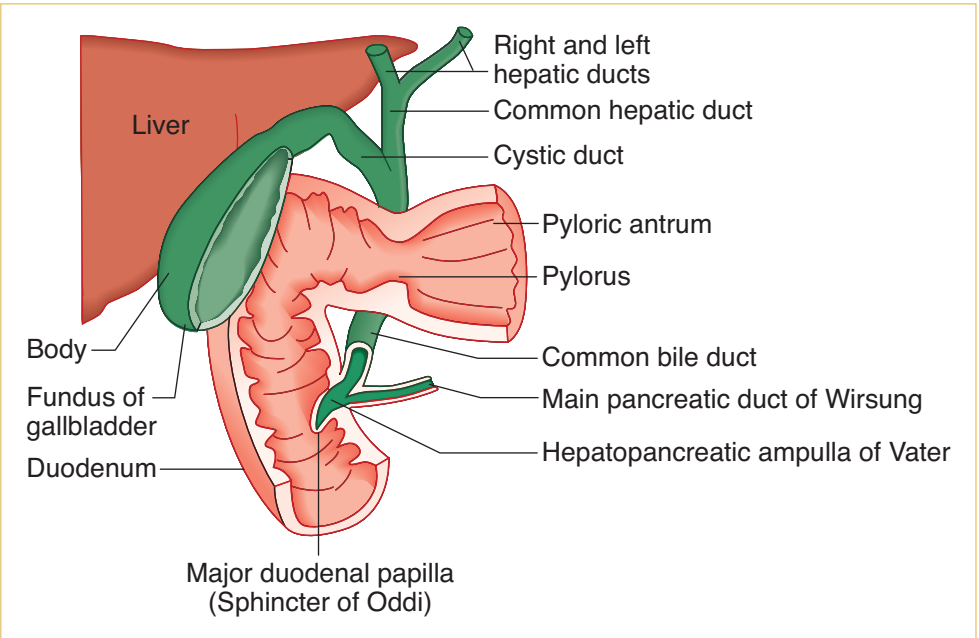

Figure II-3-12. Biliary Ducts

Pancreas

The pancreas horizontally crosses the posterior abdominal wall at approximately at the level of the transpyloric plane. The gland consists of 4 parts: **head, neck, body, and tail**.

- The head of the pancreas rests within the C-shaped area formed by the duodenum and is traversed by the common bile duct. It includes the **uncinate process** which is crossed by the superior mesenteric vessels.
- Posterior to the neck is the site of formation of the hepatic portal vein.
- The body passes to the left and passes anterior to the aorta and the left kidney. The splenic artery undulates along the superior border of the body of the pancreas with the splenic vein coursing posterior to the body.
- The tail of the pancreas enters the **splenorenal ligament** to reach the hilum of the spleen. The tail is the only part of the pancreas that is **intraperitoneal**.

The main **pancreatic duct** (Figures II-3-12 and II-3-13) courses through the body and tail of the pancreas to reach the head of the pancreas, where it joins with the common bile duct to form the hepatopancreatic ampulla.

The head of the pancreas receives its blood supply from the **superior and inferior pancreaticoduodenal branches** of the gastroduodenal and superior mesenteric arteries, respectively. This region is important for **collateral circulation** because there are anastomoses between these branches of the celiac trunk and superior mesenteric artery.

Clinical Correlate

Carcinoma of the pancreas commonly occurs in the **head of the pancreas** and may constrict the main **pancreatic duct** and the **common bile duct**. Obstruction of the bile duct may cause **jaundice**.

The neck, body, and tail of the pancreas receive their blood supply from the **splenic artery**.

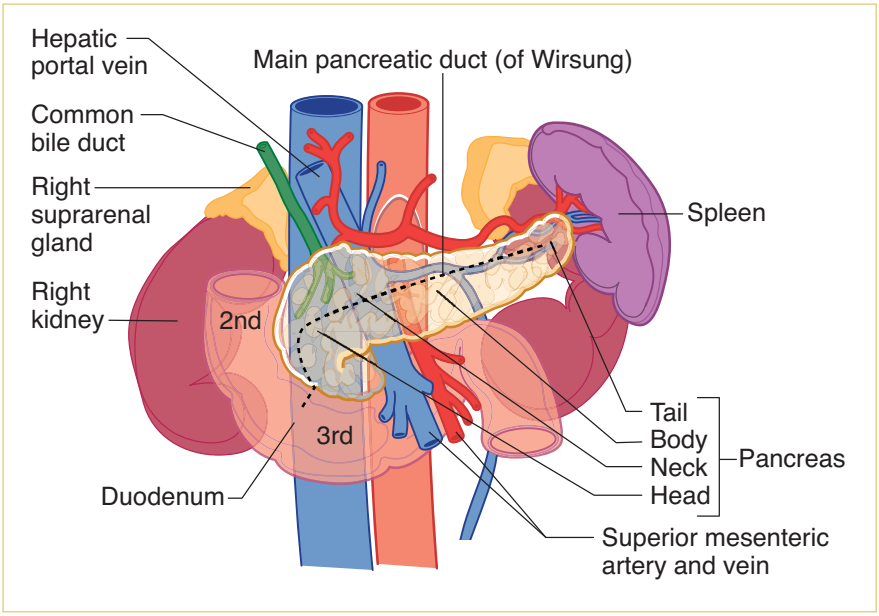

Figure II-3-13. Adult Pancreas

Clinical Correlate

The spleen may be lacerated with a fracture of the **9th, 10th, or 11th rib on the left side.**

Spleen

The spleen is a peritoneal organ in the upper left quadrant that is deep to the left 9th, 10th, and 11th ribs. The visceral surface of the spleen is in contact with the left colic flexure, stomach, and left kidney. Inasmuch as the spleen lies above the costal margin, a normal-sized spleen is not palpable.

The splenic artery and vein reach the hilus of the spleen by traversing the **splenorenal ligament**.

Clinical Correlate

A **sliding hiatal hernia** occurs when the cardia of the stomach herniates through the esophageal hiatus of the diaphragm. This can damage the vagal trunks as they pass through the hiatus.

Stomach

The stomach has a right **lesser curvature**, which is connected to the porta hepatis of the liver by the lesser omentum (hepatogastric ligament), and a left **greater curvature** from which the greater omentum is suspended (Figure II-3-8).

The cardiac region receives the esophagus; and the dome-shaped upper portion of the stomach, which is normally filled with air, is the fundus. The main central part of the stomach is the body. The pyloric portion of the stomach has a thick muscular wall and narrow lumen that empties into the duodenum approximately in the transpyloric plane (L1 vertebra).

Duodenum

The duodenum is C-shaped, has 4 parts, and is located retroperitoneal except for the first part.

- The first part is referred to as the duodenal cap (bulb). The gastroduodenal artery and the common bile duct descend posterior to the first part.
- The second part (descending) receives the **common bile duct** and main **pancreatic duct** at the hepatopancreatic ampulla (of Vater). Smooth muscle in the wall of the duodenal papilla is known as the sphincter of Oddi.

Note that the foregut terminates at the point of entry of the common bile duct; the remainder of the duodenum is part of the midgut.

Jejunum and Ileum

The jejunum begins at the duodenojejunal junction and comprises 2/5 of the remaining small intestine. The beginning of the ileum is not clearly demarcated; it consists of the distal 3/5 of the small bowel.

The jejunoileum is suspended from the posterior body wall by the mesentery proper. Although the root of the mesentery is only 6 inches long, the mobile part of the small intestine is approximately 22 feet in length.

Colon

The **cecum** is the first part of the colon, or large intestine, and begins at the ileocecal junction. It is a blind pouch, which often has a mesentery and gives rise to the vermiform appendix. The appendix has its own mesentery, the mesoappendix.

The **ascending colon** lies retroperitoneally and lacks a mesentery. It is continuous with the transverse colon at the right (hepatic) flexure of colon.

The **transverse colon** has its own mesentery called the **transverse mesocolon**. It becomes continuous with the descending colon at the left (splenic) flexure of colon. The midgut terminates at the junction of the proximal two-thirds and distal one-third of the transverse colon.

The **descending colon** lacks a mesentery. It joins the sigmoid colon where the large bowel crosses the pelvic brim.

The **sigmoid colon** is suspended by the **sigmoid mesocolon**. It is the terminal portion of the large intestine and enters the pelvis to continue as the rectum.

The superior one-third of the **rectum** is covered by peritoneum anteriorly and laterally. It is the fixed, terminal, straight portion of the hindgut.

The **anal canal** is about 1.5 inches long and opens distally at the anus. It is continuous with the rectum at the pelvic diaphragm, where it makes a 90-degree posterior bend (anorectal flexure) below the rectum.

- The **puborectalis component** of the pelvic diaphragm pulls the flexure forward, helping to maintain fecal continence.
- The **internal anal sphincter** is circular smooth muscle that surrounds the anal canal. The **sympathetics** (lumbar splanchnics) **increase** the tone of the muscle and the **parasympathetics** (pelvic splanchnics) **relax** the muscle during defecation.

- The **external anal sphincter** is circular voluntary skeletal muscle surrounding the canal that is voluntarily controlled by the inferior rectal branch of the **pudendal nerve** and **relaxes** during defecation.
- The anal canal is divided into upper and lower parts separated by the **pectinate line**, an elevation of the mucous membrane at the distal ends of the anal columns.

Table II-3-3. Comparison of Features Above and Below the Pectinate Line

Above	Below
Visceral (ANS) sensory innervation	Somatic sensory innervation
Portal venous drainage	Caval venous drainage
Drain to iliac lymph nodes	Drain to superficial inguinal nodes
Internal hemorrhoids (painless)	External hemorrhoids (painful)
Endoderm	Ectoderm

Abbreviations: ANS, autonomic nervous system

GASTROINTESTINAL HISTOLOGY

The alimentary or gastrointestinal (GI) tract is a muscular tube that runs from the oral cavity to the anal canal. The GI tract walls are composed of 4 layers: mucosa, submucosa, muscularis externa, and serosa.

Copyright McGraw-Hill Companies. Used with permission.

Figure II-3-14. Organization of the GI tract

Mucosa (M) submucosa (SB), muscularis externa (ME), serosa or visceral peritoneum (S), mesentery (arrow)

Mucosa

The **mucosa** is the innermost layer and has 3 components.

- The **epithelium** lining the lumen varies in different regions, depending on whether the function is primarily conductive and protective (stratified squamous; in the pharynx and esophagus), or secretory and absorptive (simple columnar; stomach and intestine).
- The **lamina propria** is a layer of areolar connective tissue that supports the epithelium and attaches it to the underlying muscularis mucosae. Numerous capillaries form extensive networks in the lamina propria (particularly in the small intestine).

  Within the lamina propria are blind-ended lymphatic vessels (lacteals) that carry out absorbed nutrients and white blood cells (particularly lymphocytes). The GALT (gut-associated lymphoid tissue), responsible for IgA production, is located within the lamina propria.
- The **muscularis mucosa** is a thin smooth-muscle layer that marks the innermost edge of the mucosa. The muscle confers some motility to the mucosa and facilitates discharge of secretions from glands. In the small intestine, a few strands of smooth muscle may run into the lamina propria and up to the tips of villi.

Submucosa

The **submucosa** is a layer of loose areolar connective tissue that attaches the mucosa to the muscularis externa and houses the larger blood vessels and mucous-secreting glands.

Muscularis Externa

The **muscularis externa** is usually comprised of 2 layers of muscle: an inner circular and an outer longitudinal. The muscularis externa controls the lumen size and is responsible for peristalsis. The muscle is striated in the upper third of the esophagus and smooth elsewhere.

Serosa

The **serosa** (or peritoneum of anatomy) is composed of a mesothelium (a thin epithelium lining the thoracic and abdominal cavities) and loose connective tissue. In the abdominal cavity, the serosa surrounds each intestinal loop and then doubles to form the mesentery within which run blood and lymphatic vessels.

INNERVATION

The GI tract has both intrinsic and extrinsic innervation. The **intrinsic** innervation is entirely located within the walls of the GI tract. The intrinsic system is capable of autonomous generation of peristalsis and glandular secretions. An interconnected network of ganglia and nerves located in the submucosa forms the Meissner's plexus and controls much of the intrinsic motility of the lining of the alimentary tract. Auerbach's plexus contains a second network of neuronal ganglia, and is located between the 2 muscle layers of the muscularis externa. All GI-tract smooth muscle is interconnected by gap junctions.

Clinical Correlate

Hirschsprung disease or aganglionic megacolon is a genetic disease present in approximately 1 out of 5,000 live births. It may result from mutations that affect the migration of neural crest cells into the gut. This results in a deficiency of terminal ganglion cells in Auerbach's plexus and affects digestive tract motility, particularly in the rectum (peristalsis is not as effective and constipation results).

The **extrinsic** autonomic innervation to the GI tract is from the parasympathetic (stimulatory) and sympathetic (inhibitory) axons that modulate the activity of the intrinsic innervation. Sensory fibers accompany the parasympathetic nerves and mediate visceral reflexes and sensations, such as hunger and rectal fullness. Visceral pain fibers course back to the CNS with the sympathetic innervation. Pain results from excessive contraction and/or distention of the smooth muscle. Visceral pain is referred to the body wall dermatomes that match the sympathetic innervation to that GI tract structure.

IMMUNE FUNCTIONS

The lumen of the GI tract is normally colonized by abundant bacterial flora. The majority of the bacteria in the body—comprising about 500 different species—are in our gut, where they enjoy a rich growth medium within a long, warm tube. Most of these bacteria are beneficial (vitamins B12 and K production, additional digestion, protection against pathogenic bacteria) but a few species of pathogenic microbes appear at times. The gut has defense mechanisms to fight these pathogens (GALT and Paneth cells).

REGIONAL DIFFERENCES

Major differences lie in the general organization of the mucosa (glands, folds, villi, etc.) and in the types of cells comprising the epithelia and associated glands in the GI tract.

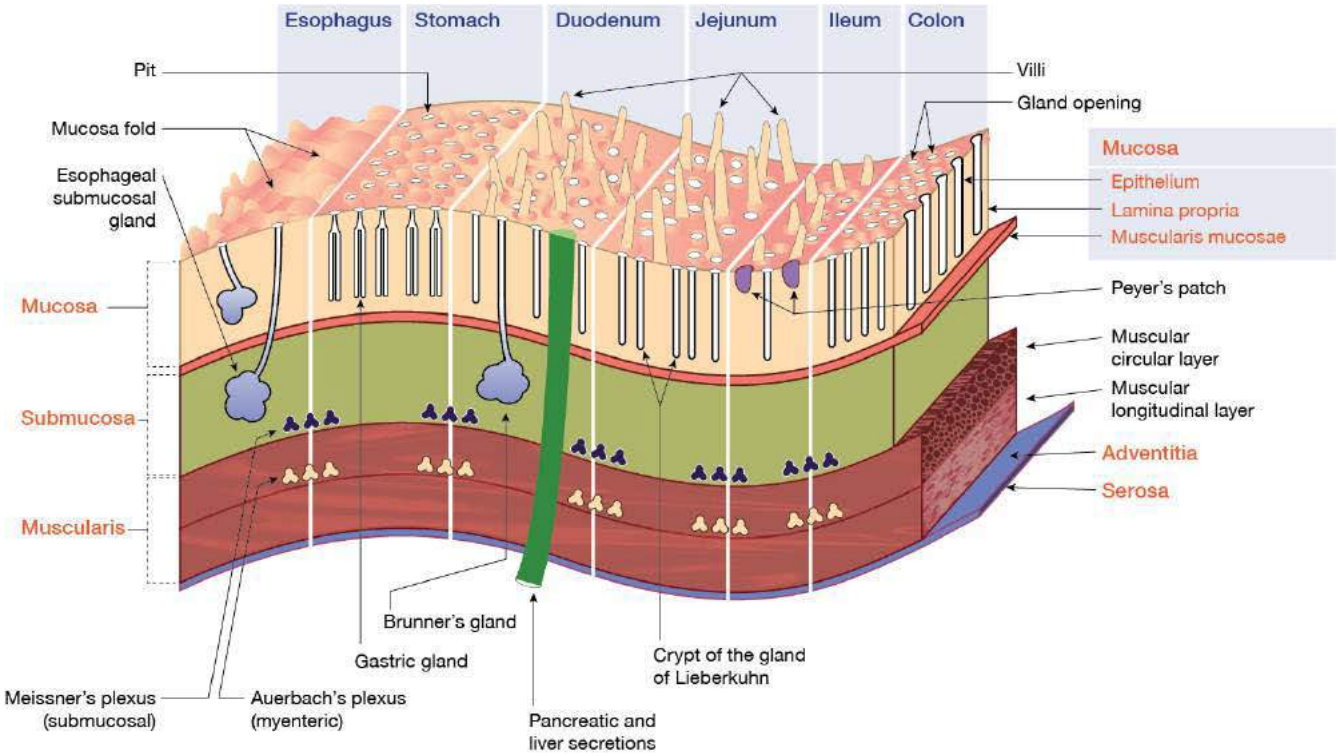

Figure II-3-15. Histologic Organization of the Digestive Tube

Table II-3-4. Histology of Specific Regions

Region	Major Characteristics	Mucosal Cell Types at Surface	Function of Surface Mucosal Cells
Esophagus	• Nonkeratinized stratified squamous epithelium • Skeletal muscle in muscularis externa (upper 1/3) • Smooth muscle (lower 1/3)	—	—
Stomach (body and fundus)	*Rugae:* shallow pits; deep glands	Mucous cells Chief cells Parietal cells Enteroendocrine (EE) cells	Secrete mucous; form protective layer against acid; tight junctions between these cells probably contribute to the acid barrier of the epithelium. Secrete pepsinogen and lipase precursor Secrete HCl and intrinsic factor Secrete a variety of peptide hormones
Pylorus	Deep pits; shallow, branched glands	Mucous cells Parietal cells EE cells	Same as above Same as above High concentration of gastrin
Small intestine	Villi, plicae, and crypts	Columnar absorptive cells	Contain numerous microvilli that greatly increase the luminal surface area, facilitating absorption
Duodenum	Brunner glands, which discharge alkaline secretion	Goblet cells Paneth cells EE cells	Secrete acid glycoproteins that protect mucosal linings Contains granules that contain lysozyme. May play a role in regulating intestinal flora High concentration of cells that secrete cholecystokinin and secretin
Jejunum	Villi, well developed plica, crypts	Same cell types as found in the duodenal epithelium	Same as above
Ileum	Aggregations of lymph nodules called Peyer's patches	M cells found over lymphatic nodules and Peyer's patches	Endocytose and transport antigen from the lumen to lymphoid cells
Large intestine	Lacks villi, crypts	Mainly mucous-secreting and absorptive cells	Transports Na^+ (actively) and water (passively) out of lumen

Oral Cavity

The epithelium of the oral cavity is a stratified squamous epithelium. Mucous and serous secretions of the salivary glands lubricate food, rinse the oral cavity, moisten the food for swallowing and provide partial antibacterial protection. Secretions of IgA from plasma cells within the connective tissue are transported through the gland epithelia to help protect against microbial attachment and invasion.

Esophagus

The esophagus is also lined by a stratified squamous epithelium. In the lower part of the esophagus there is an abrupt transition to the simple columnar epithelium of the stomach. Langerhans cells—macrophage-like antigen-presenting cells—are present in the epithelial lining. The muscularis externa of the esophagus consists of striated muscle in the upper third, smooth muscle in the distal third, and a combination of both in the middle third.

Copyright McGraw-Hill Companies. Used with permission.

Figure II-3-16. Esophagus with non-keratinizing stratified squamous epithelium (arrow) and a thin lamina propria with vessels (arrowheads)

The underlying muscularis externa (ME) is skeletal muscle from the upper half of the esophagus

Stomach

The stomach has 3 distinct histological areas: the cardia, body, and pyloric antrum. The mucosa of the stomach is thrown into folds (rugae) when empty, but disappears when the stomach is full. The surface is lined by a simple columnar epithelium. The stomach begins digestion by initiating the chemical and enzymatic breakdown of ingested food. Proteins are initially denatured by the acidic gastric juice before being hydrolyzed to polypeptide fragments by the enzyme pepsin. The chyme consists of denatured and partially broken-up food particles suspended in a semi-fluid, highly acidic medium.

Gastric pits form numerous deep tubular invaginations that line the inner surface of the stomach. The gastric pits are closely spaced; they penetrate into the thickness of the mucosa and extend into gastric glands. The transition between pits and glands is marked by the isthmus, where there is a narrowing of the lumen, and by a change in cellular composition of the epithelium. The glands are coiled in the cardiac and pyloric regions of the stomach and straight in the fundus and body regions. Glands in the body of the stomach deliver gastric juice (containing HCl and enzymes, rennin and lipase) to each pit, and from there to the stomach lumen. There are about 5 million glands in the stomach, secreting some 2 liters of fluid per day.

Mucous-secreting cells are located on the inner surface of the stomach, in the pit and in the neck, the transitional region between pits and glands. These cells produce a thick layer of mucous which covers and protects the stomach, falling into 2 categories: the surface mucous is composed of neutral glycoproteins, while the mucous secreted by the neck mucous cells is composed of acidic glycoproteins. In cardiac and pyloric regions, mucous cells are also the major cell type in the glands.

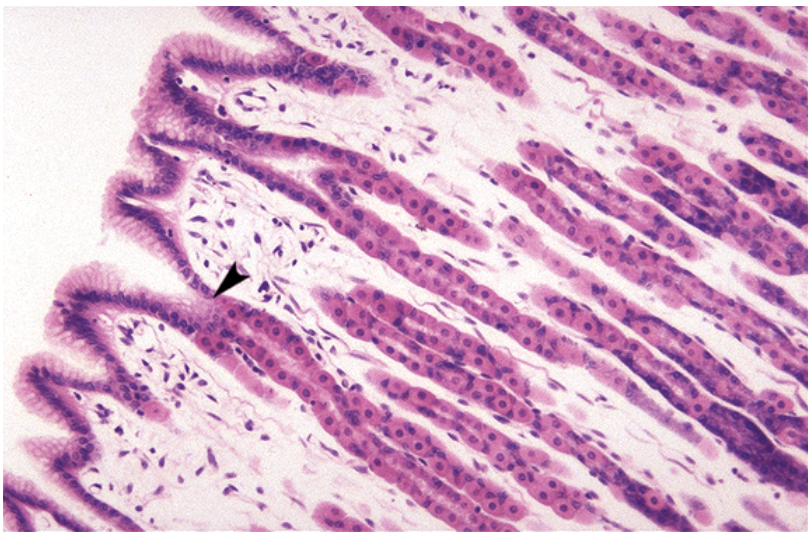

Copyright McGraw-Hill Companies. Used with permission.

Figure II-3-17. Cardiac part of the stomach with gastric pits and coiled gastric glands.

Stem cells that regenerate all stomach cells are located at the isthmus (arrowhead)

Oxyntic or parietal cells secrete 0.1N HCl into the stomach lumen and bicarbonate ions into the lamina propria (a byproduct of the acid production) in response to histamine, gastrin, and acetylcholine. These cells also secrete intrinsic factor (a glycoprotein necessary for absorption of vitamin B12). Vitamin B12 is required for production of erythrocytes; deficiencies result in pernicious anemia and a disruption of peripheral and central nervous system myelin (see subacute combined degeneration in *Neuroscience* section).

Parietal cells, located in the upper regions of the gastric glands, have a broader base and narrower apex. Their structure varies greatly depending on their functional state.

Clinical Correlate

Acetylcholine and gastrin increase HCL secretion by parietal cells. Histamine potentiates both by binding to the histamine H_2 receptor. Cimetidine and H_2 antagonists inhibit histamine.

Clinical Correlate

Infection by *Helicobacter pylori* affects the gastric mucosal lining and allows pepsin, HCl, and proteases to erode the mucosa.

Hematemesis and melena are common clinical findings.

Chief or **peptic cells** secrete pepsinogen, an enzyme precursor that is stored in secretory (zymogen) granules before its induced secretion. Pepsinogen is inactive and protects the peptic cells from autodigestion. Low pH, in the stomach lumen, converts pepsinogen to pepsin.

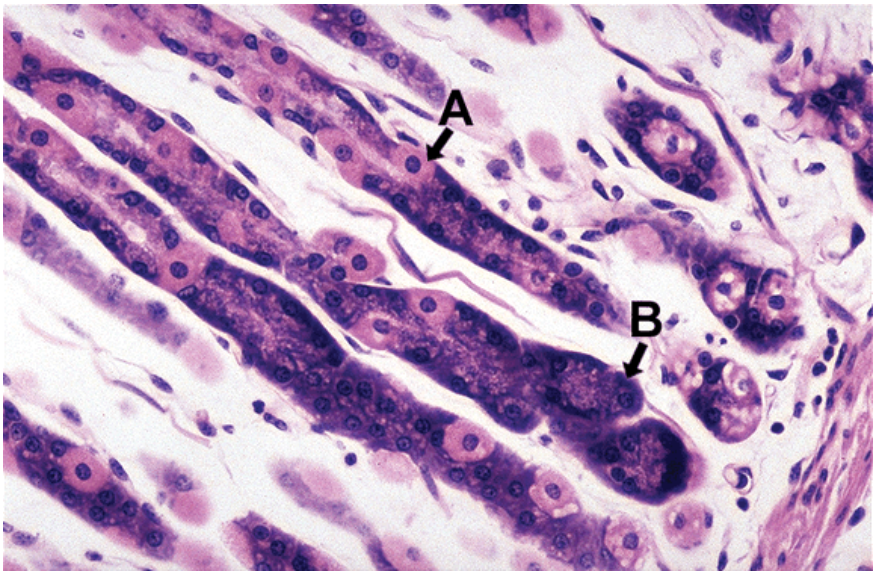

Copyright McGraw-Hill Companies. Used with permission.

Figure II-3-18. Stomach near the base of gastric glands

Pale-staining parietal cells (A) and chief cells (B) are shown.

The **enteroendocrine cells** or APUD cells (amine precursor uptake and decarboxylation) are present throughout the GI tract and are also found in the respiratory tract. They constitute a diffuse neuroendocrine system that collectively accounts for more cells than all other endocrine organs in the body. Enteroendocrine cells are dispersed throughout the GI tract so that they can receive and transmit local signals.

The **stem cells** responsible for the regeneration of all types of cells in the stomach epithelium are **located in the isthmus**. Their mitotic rate can be influenced by the presence of gastrin and by damage (aspirin, alcohol, bile salt reflux). Renewal of many gastric epithelial cells occurs every 4–7 days.

- Although the stem cells are capable of differentiating into any of the stomach cell types, there is evidence that the position of the cell along the gland influences its fate.
- In contrast to the short life span (4–5 days) of the cells near the acidic environment, the chief cells—deep within the glands—may have a life span >190 days.

Small Intestine

The small intestine is tubular in shape and has a total length of about 21 feet. The effective internal surface area of the small intestine is greatly increased by the plicae circulares, villi and microvilli.

Plicae circulares (circular folds or valves of Kerckring) are foldings of the inner surface that involve both mucosa and sub-mucosa. Plicae circulares increase the surface area by a factor of 3.

Villi arise above the muscularis mucosae and they include the lamina propria and epithelium of the mucosa. Villi increase the surface area by a factor of 10.

Microvilli of the absorptive epithelial cells increase the surface area by a factor of 20–30. The surface area of microvilli is increased even further by the presence of surface membrane glycoproteins, constituting the glycocalyx to which enzymes are bound.

The luminal surface of the small intestine is perforated by the openings of numerous tubular invaginations (the crypts of Lieberkühn) analogous to the glands of the stomach. The crypts penetrate through the lamina propria and reach the muscularis mucosae.

The small intestine completes digestion, absorbs the digested food constituents (amino acids, monosaccharides, fatty acids), and transports them into blood and lymphatic vessels.

The **duodenum** is the proximal pyloric end of the small intestine. Distal to the duodenum is the **jejunum**, and then the **ileum**.

In the small intestine, the chyme from the stomach is **mixed** with mucosal cell secretions, exocrine pancreatic juice, and bile.

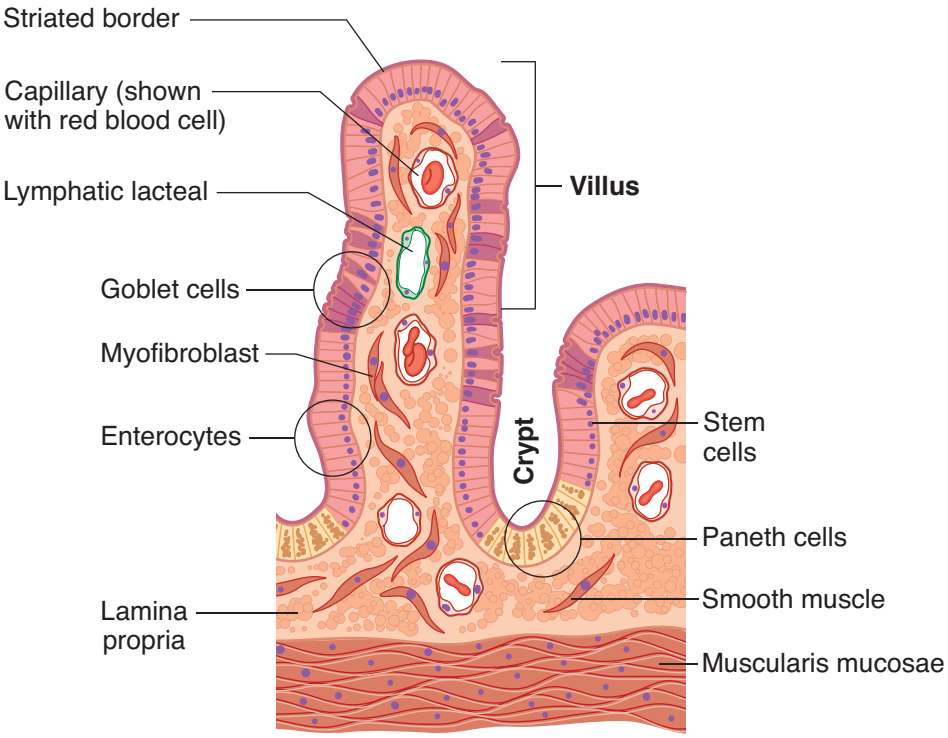

Figure II-3-19. Small Intestine Mucosal Histology

Clinical Correlate

Any compromise of the mucous protection can lead to significant damage and irritation of the gastrointestinal tract, leading to gastritis, duodenitis, or even peptic ulcer disease.

Mucous production occurs in surface epithelial cells throughout the GI tract, by **Brunner glands** in the duodenum and **goblet cells** in the mucosa throughout the intestine.

Mucous functions include lubrication of the GI tract, binding bacteria, and trapping immunoglobulins where they have access to pathogens.

The **rate of mucous** secretion is increased by cholinergic stimulation, chemical irritation, and physical irritation.

In the **duodenum,** the acidic chyme from the stomach is neutralized by the neutral or alkaline mucous secretions of glands located in the submucosal or Brunner's glands. The duodenum also receives digestive enzymes and bicarbonate from the pancreas and bile from the liver (via gallbladder) through the bile duct, continuing the digestive process.

Clinical Correlate

Peristalsis is activated by the **parasympathetic system**. For those suffering from decreased intestinal motility manifesting as constipation (paralytic ileus, diabetic gastroparesis), dopaminergic and cholinergic agents are often used (e.g., metoclopramide).

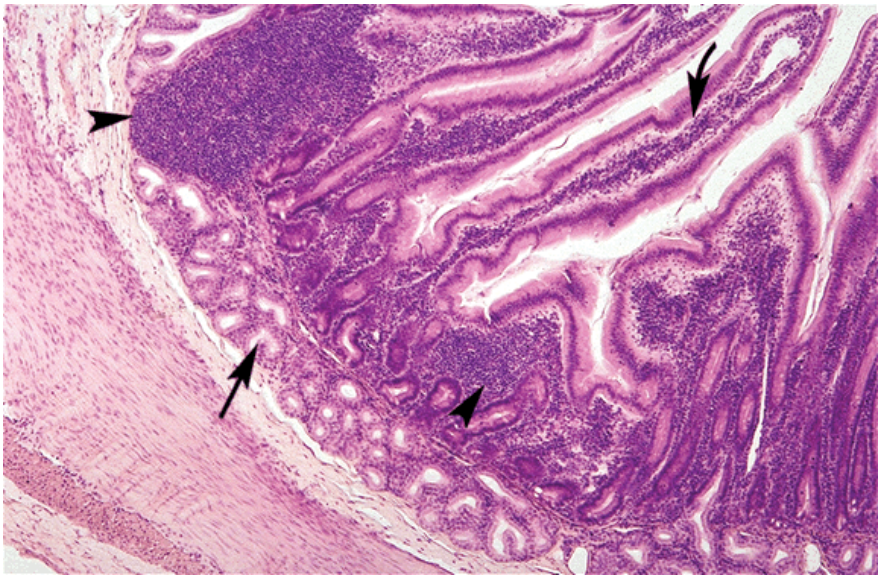

Copyright McGraw-Hill Companies. Used with permission.

Figure II-3-20. Duodenum with villi (curved arrow) and submucosal Brunner glands (arrow)

Patches of lymphatic tissue are in the lamina propria (arrowheads).

In the **jejunum,** the digestion process continues via enterocyte-produced enzymes and absorbs food products. The plicae circulares are best developed here. In the **ileum,** a major site of immune reactivity, the mucosa is more heavily infiltrated with lymphocytes and the accompanying antigen-presenting cells than the duodenum and jejunum. Numerous primary and secondary lymphatic nodules (Peyer's patches) are always present in the ileum's mucosa, though their location is not fixed in time. In the infant, maternal IgGs that are ingested are recognized by the Fc receptors in microvilli and endocytosed to provide passive immunity. In the adult, only trace amounts of intact proteins are transferred from lumen to lamina propria, but IgAs produced in GALT in the ileum are transported in the opposite direction into the lumen.

Throughout the small intestine, **the simple columnar intestinal epithelium has 5 types of differentiated cells, all derived from a common pool of stem cells.**

- **Goblet cells** secrete mucous that protects the surface of the intestine with a viscous fluid consisting of glycoproteins (20% peptides, 80% carbohydrates).
- **Enterocytes** have 2 major functions. Enterocytes participate in the final digestion steps and they absorb the digested food (in the form of amino acids, monosaccharides, and emulsified fats) by transporting it from the lumen of the intestine to the lamina propria, where it is carried away by blood vessels and lymphatics.
- **Paneth cells** are cells located at the base of the crypts, especially in the jejunum and ileum; they contain visible acidophilic secretory granules located in the apical region of the cells. These cells protect the body against pathogenic microorganisms by secreting lysozyme and defensins (or cryptins) that destroy bacteria. Their life span is about 20 days.

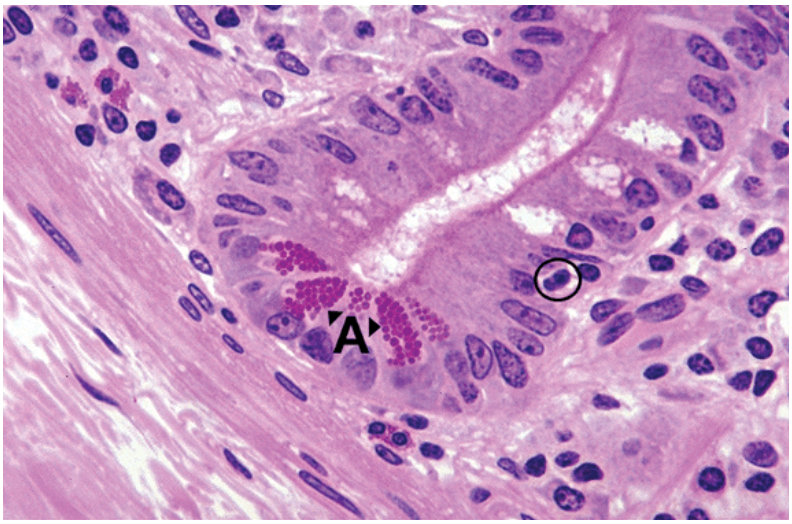

Copyright McGraw-Hill Companies. Used with permission.

Figure II-3-21. Cells at the base of crypts of Lieberkühn include Paneth cells (A) with large apical granules of lysozyme, and an adjacent stem cell (circle) undergoing mitosis.

- **Enteroendocrine cells** of the small and large intestine, like those of the stomach, secrete hormones that control the function of the GI tracts and associated organs. They are located in the lower half of the crypts and are detectable by silver-based stains.
- **Stem cells** are located in the crypts, about one-third of the way up from the bottom. Their progeny differentiates into all the other cell types. **The epithelial lining of the small intestine, particularly that covering the villi, completely renews itself every 5 days (or longer, during starvation).** The newly created cells (goblet, enterocytes, and enteroendocrine cells) migrate up from the crypts, while the cells at the tips of microvilli undergo apoptosis and slough off. There is also a

Note

Histologically, the duodenum contains submucosal Brunner's glands, and the ileum contains Peyer's patches in the lamina propria. The jejunum can be easily recognized because it has neither Brunner's glands nor Peyer's patches.

group of fibroblasts that accompany these epithelial cells as they move toward the tips of the villi. Other cells move to the base of the crypts, replenishing the population of Paneth and enteroendocrine cells.

Gut-associated lymphatic tissue (GALT): Throughout the intestine, the lamina propria is heavily infiltrated with macrophages and lymphocytes. Peyer's patches are patches of GALT that are prominent in the ileum. M cells in the epithelium transport luminal antigens to their base, where they are detected by B lymphocytes and taken up by antigen-presenting macrophages.

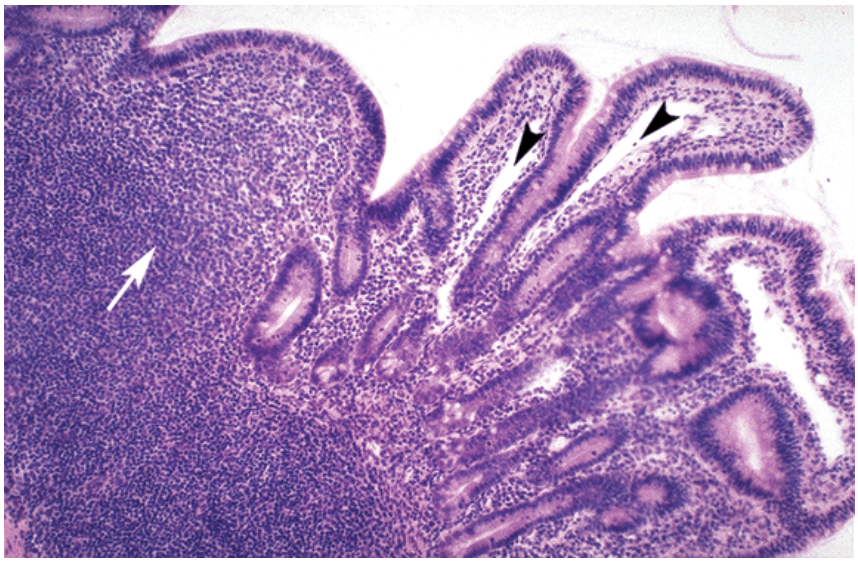

Copyright McGraw-Hill Companies. Used with permission.

Figure II-3-22. Ileum with Peyer's patches (arrow) and central lacteals (arrowheads) in the lamina propria of the villi

Large Intestine

The **large intestine** includes the cecum (with appendix), ascending, transverse, and descending colon, sigmoid colon, rectum, and anus. The large intestine has a wide lumen, strong musculature, and longitudinal muscle that is separated into 3 strands, the teniae coli. The inner surface has no plicae and no villi but consists of short crypts of Lieberkühn.

General features

- The colon is larger in diameter and shorter in length than is the small intestine. Fecal material moves from the **cecum**, through the colon (**ascending**, **transverse**, **descending**, and **sigmoid colons**), rectum, and anal canal.
- Three longitudinal bands of muscle, the **teniae coli**, constitute the outer layer. Because the colon is longer than these bands, pouching occurs, creating **haustra** between the teniae and giving the colon its characteristic "caterpillar" appearance.

- The mucosa has **no villi**, and mucous is secreted by short, inward-projecting colonic glands.
- Abundant lymphoid follicles are found in the cecum and appendix, and more sparsely elsewhere.
- The major functions of the colon are **reabsorption of fluid and electrolytes** and **temporary storage of feces**.

Defecation

Rectal distention with feces activates intrinsic and cord reflexes that cause relaxation of the internal anal sphincter (smooth muscle) and produce the urge to defecate. If the external anal sphincter (skeletal muscle innervated by the **pudendal nerve**) is then voluntarily relaxed, and intra-abdominal pressure is increased via the **Valsalva maneuver**, defecation occurs. If the external sphincter is held contracted, the urge to defecate temporarily diminishes.

Throughout the large intestine, the epithelium contains goblet, absorptive, and enteroendocrine cells. Unlike the small intestine, about half of the epithelial cells are mucous-secreting goblet cells, providing lubrication. The major function of the large intestine is fluid retrieval. Some digestion is still occurring, mainly the breakdown of cellulose by the permanent bacterial flora. Stem cells are in the lower part of the crypts.

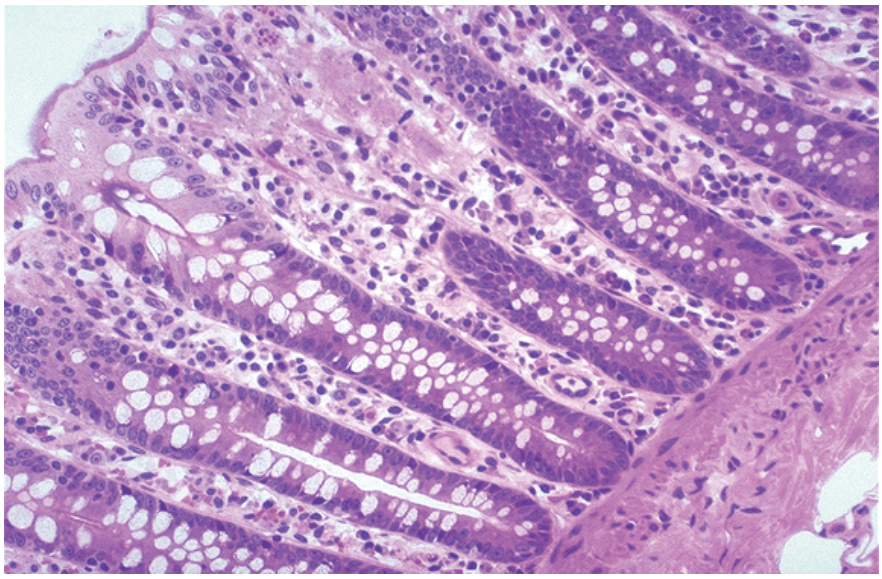

Copyright McGraw-Hill Companies. Used with permission.

Figure II-3-23. Large intestine with crypts but no villi and many light-staining goblet cells interspersed among enterocytes

GASTROINTESTINAL GLANDS

Salivary Glands

The major salivary glands are all branched tubuloalveolar glands, with secretory **acini** that drain into **ducts**, which drain into the oral cavity. Acini contain **serous**, **mucous**, or both types of secretory cells, as well as **myoepithelial cells**, both surrounded by a basal lamina. Serous cells secrete various proteins and enzymes. Mucous cells secrete predominantly glycosylated mucins.

Table II-3-5. Gastrointestinal Glands

Salivary glands Submandibular Parotid Sublingual	• Produce approximately 1.5 L/day of saliva • Presence of food in the mouth; the taste, smell, sight, or thought of food; or the stimulation of vagal afferents at the distal end of the esophagus increase production of saliva	
Functions	• Initial triglyceride digestion (lingual lipase) • Initial starch digestion (α-amylase) • Lubrication	
Regulation	**Parasympathetic**	↑ synthesis and secretion of **watery** saliva via muscarinic receptor stimulation; (anticholinergics → dry mouth)
	Sympathetic	↑ synthesis and secretion of **viscous** saliva via β-adrenergic receptor stimulation

The ducts that drain the glands increase in size and are lined by an epithelium that transitions from cuboidal to columnar to pseudostratified to stratified columnar cells. The smallest ducts, **intercalated ducts**, have myoepithelial cells; the next larger ducts, **striated ducts**, have columnar cells with basal striations, caused by basal infolding of cell membranes between prominent mitochondria. These columnar cells make the saliva hypotonic by transporting Na and Cl ions out of saliva back into the blood.

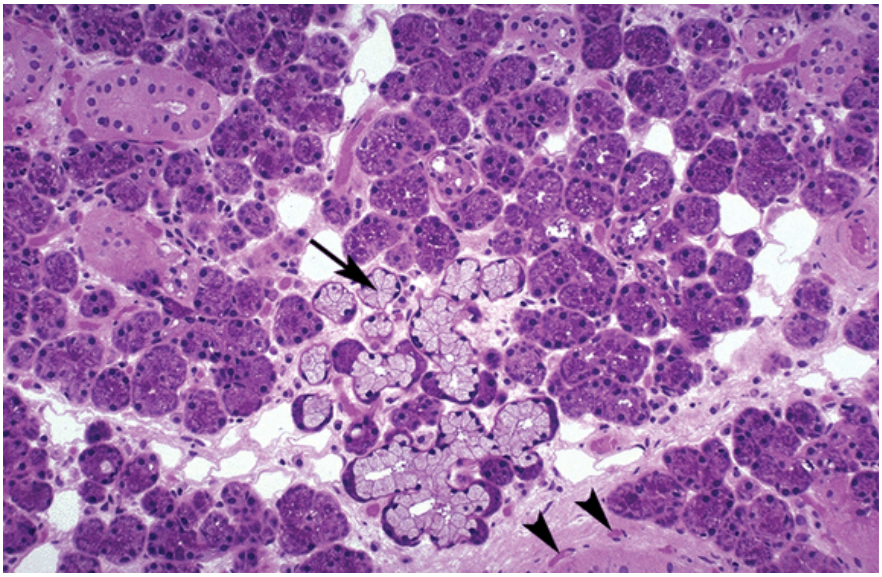

Copyright McGraw-Hill Companies. Used with permission.

Figure II-3-24. Submandibular with a mix of light-staining mucous acini (arrow) adjacent to dark-staining serous acini

Small vessels (arrowheads)

- The **parotid glands** lie on the surface of the masseter muscles in the lateral face, in front of each external auditory meatus. The parotids are **entirely serous** salivary glands that drain inside each cheek through **Stensen's ducts** which open above the second upper molar tooth. The parotid glands contribute 25% of the volume of saliva.
- The **submandibular glands** lie inside the lower edge of the mandible, and are mixed serous/mucous glands with a **predominance of serous** cells. They drain in the floor of the mouth near the base of the tongue through **Wharton's ducts**. The submandibular glands contribute 70% of the volume of saliva.
- The **sublingual glands** lie at the base of the tongue, and are also mixed serous/mucous glands with a **predominance of mucous** cells. They drain into the mouth through multiple small ducts. The sublingual glands contribute 5% of the volume of saliva.

Exocrine Pancreas

The pancreas is a branched tubuloacinar exocrine gland with **acini**. The acini are composed of secretory cells that produce multiple digestive enzymes including proteases, lipases, and amylases. Acinar cells are functionally polarized, with basophilic RER at their basal ends below the nucleus, and membrane-bound, enzyme-containing eosinophilic **zymogen granules** toward their apex.

The endocrine-producing cells of the **islets of Langerhans** are embedded within the exocrine pancreas.

Clinical Correlate

The parotid gland is the major site of the mumps and rabies viruses that are transmitted in saliva.

Benign tumors most frequently appear at the parotid gland; their removal is complicated by the facial nerve traversing the gland.

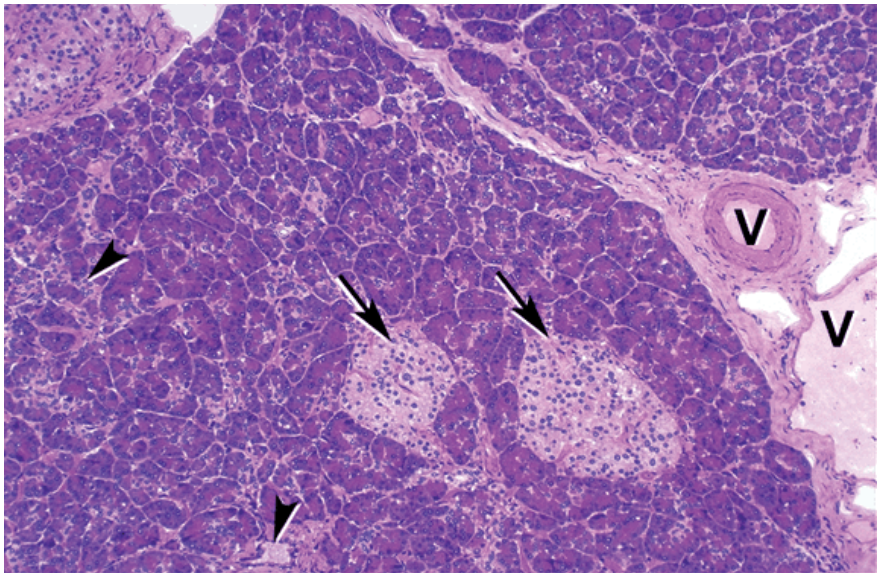

Copyright McGraw-Hill Companies. Used with permission.

Figure II-3-25. Pancreas with light-staining islets of Langerhans (arrows) surrounded by exocrine acini with ducts (arrowheads) and adjacent blood vessels (V)

Unlike salivary glands, the **pancreas lacks myoepithelial cells** in acini and **lacks striated ducts**. Also, unlike salivary glands, the cells of the intercalated ducts extend partially into the lumen of pancreatic acini as **centroacinar cells**. The pancreas does not usually have mucinous cells in acini, but may have mucinous cells in its ducts.

Pancreatic acini drain via progressively larger ducts into the duodenum. The main pancreatic **duct (of Wirsung)** is the distal portion of the dorsal pancreatic duct that joined the ventral pancreatic duct in the head of the pancreas. The main duct typically joins with the common bile duct and enters the duodenum through the **ampulla of Vater** (controlled by the **sphincter of Oddi**). Sometimes the pancreas has a persistent accessory duct with separate drainage into the duodenum, the **accessory duct of Santorini**, and a persisting remnant of the proximal part of the dorsal pancreatic duct.

Liver

The liver is the largest visceral organ and gland (both exocrine and endocrine) in the body. **Hepatocytes**, of endodermal epithelial origin, carry out both exocrine and endocrine functions. The liver has unusual capillaries, the hepatic **sinusoids**, that facilitate exchange (uptake and secretion) between hepatocytes and blood. The liver has **Kupffer cells**, specialized cells of the mononuclear phagocyte system (blood monocyte derived) which patrol the **space of Disse** between hepatocytes and blood.

The liver has epithelial lined exocrine (excretory) ducts, the **bile ducts**, lined by **biliary epithelium**, which drain hepatocyte products (bile) into the duodenum, ultimately through the common bile duct. Blood flow into the liver is dual (75% from **portal vein**, 25% from **hepatic artery**), while blood flow out is via **hepatic veins** into the inferior vena cava.

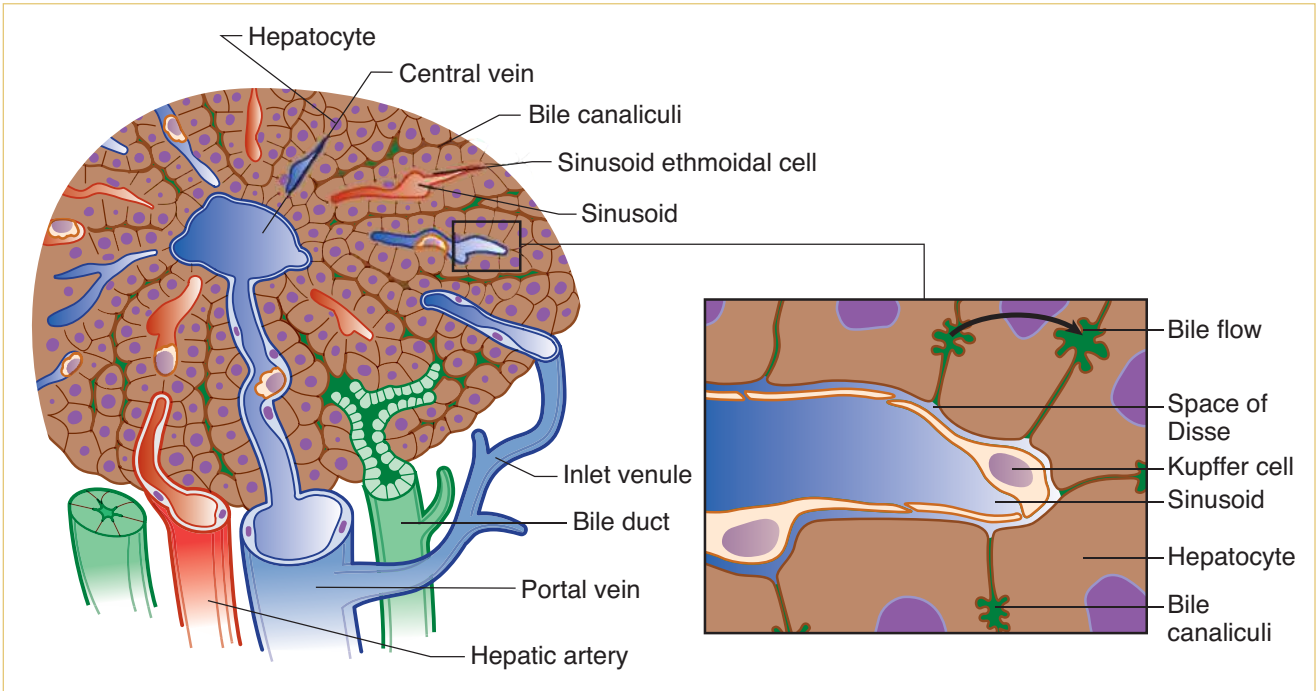

Figure II-3-26. Organization of a Liver Lobule

Hepatocytes are functionally polarized, like many other epithelial cells, but rather than being polarized along a single axis, each hepatocyte has multiple "**basal**" and "**apical**" surfaces.

- Where 2 hepatocytes abut, their "apical" surfaces form bile **canaliculi**, extracellular grooved bile channels joined by tight and occluding junctions between adjacent hepatocytes. Bile is secreted into bile canaliculi, which drains into progressively larger bile ducts and empties into the duodenum.
- Where a hepatocyte abuts a sinusoid, its membrane has microvilli, representing a "basal" or basolateral surface. Exchange between blood and hepatocytes is facilitated by the surface microvilli. This exchange occurs in the space of Disse, which is between the fenestrated endothelial cells of the sinusoid and the basal surface of hepatocytes.

The hepatic artery and portal vein enter and the common hepatic duct exits the liver in the hepatic **hilum**. Within the liver, branches of the hepatic artery, portal vein, and bile duct tend to run together in thin connective tissue bands. When seen in cross section, these 3 structures and their connective tissue are called a **portal triad or portal tract**. Blood from both the portal vein and hepatic artery branches flows through and mixes in hepatic sinusoids that run between cords or plates of hepatocytes. After passing by hepatocytes, the sinusoidal blood flows into hepatic venules, which form progressively larger branches draining into the right and left hepatic veins which drain into the inferior vena cava.

A **classic hepatic lobule** is a hexagonal structure with a portal tract at each corner of the hexagon and a central vein in the center of the hexagon. Blood flow is from the triads into the central vein and bile flow is opposite, from the central vein to the triads.

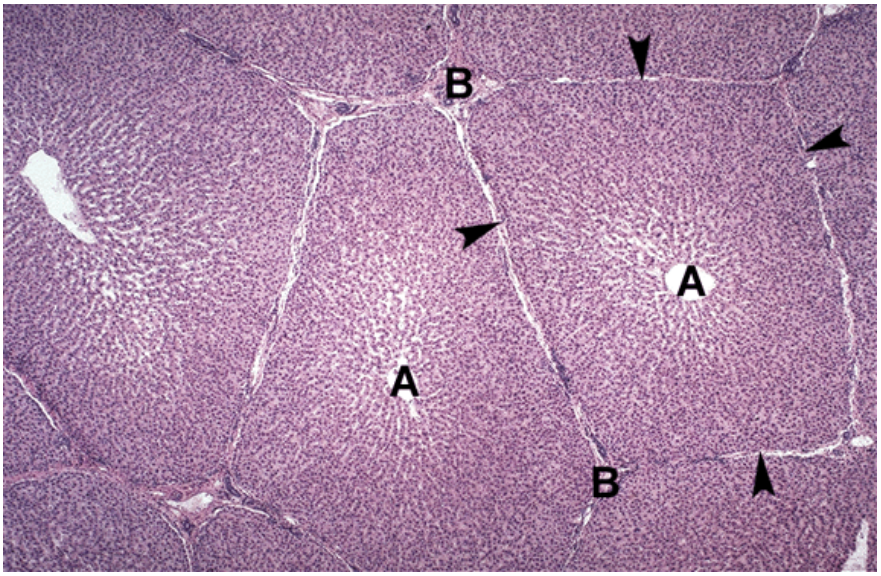

Copyright McGraw-Hill Companies. Used with permission.

Figure II-3-27. Liver lobules with central veins (A) in the center of each lobule and connective tissue (arrowheads) separating each lobule and portal triads at each point of the lobule (B)

A **portal lobule** is a triangular structure with a central vein at each corner and a portal tract in the center. Bile flows from the periphery of the portal lobule into the central triad.

A **hepatic acinus** is based on blood flow from the hepatic artery branches to central veins. As hepatic arterial blood flow enters the sinusoids from side branches extending away from the center of the hepatic triad (rather than directly from the triad), the center of the acinus is conceived of as centered on such a branch extending out from a triad (or between 2 triads) and ending at 2 nearby central veins, resulting in a roughly elliptical structure with portal tracts at the 2 furthest poles and 2 central veins at the 2 closest edges.

In the acinus, the hepatocytes receiving the first blood flow (and the most oxygen and nutrients) are designated **zone 1**, while those receiving the last blood flow (and least oxygen and nutrients) are near the central veins and designated **zone 3**. **Zone 2** hepatocytes are in between zones 1 and 3. This model helps to explain the **differential effect on hepatocytes of changes in blood flow, oxygenation, etc**. Zone 3 is most susceptible to injury by decreased oxygenation of blood or decreased blood flow into the liver (as well as stagnation of blood drainage out of the liver due to congestive heart failure).

The metabolic activity of hepatocytes varies within the zones of the acinus. Zone 1 hepatocytes are most involved in glycogen synthesis and plasma protein synthesis (albumin, coagulation factors and complement components). Zone 3 cells are most concerned with lipid, drug, and alcohol metabolism and detoxification.

Ito cells (stellate cells) are mesenchymal cells that live in the space of Disse. They contain fat and are involved in **storage of fat-soluble vitamins, mainly vitamin A**.

Bile formation by hepatocytes serves both an exocrine and excretory function. Bile salts secreted into the duodenum aid in fat emulsification and absorption, as well as excretion of endogenous metabolites (bilirubin) and drug metabolites that cannot be excreted by the kidney.

Gallbladder

The gallbladder is lined by a simple columnar epithelium with both absorptive and mucin secretory function, with underlying lamina propria. Unlike the gut tube, the gallbladder **lacks muscularis mucosae and submucosa**, and the muscularis externa is not organized into 2 distinct layers like the gut. The surface of the gallbladder is covered by peritoneal serosa (mesothelium). The gallbladder has a wide end, the **fundus**, and a narrowing **neck**, which empties into the **cystic duct** and which has spiral valves of Heister. The cystic duct joins the **common hepatic duct** to form the **common bile duct**, which joins the pancreatic duct at or just before the ampulla of Vater.

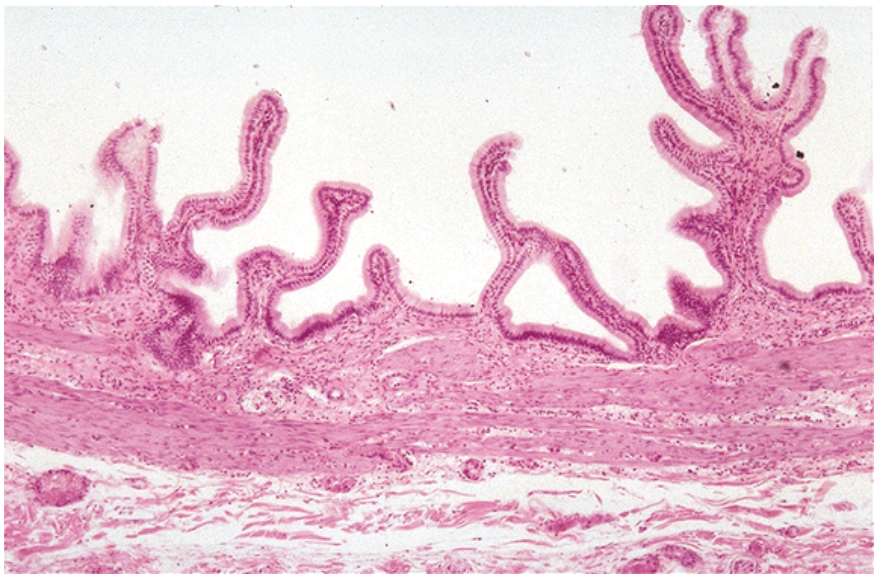

Copyright McGraw-Hill Companies. Used with permission.

Figure II-3-28. Gallbladder with folds lined by a simple columnar epithelium with no goblet cells

The gallbladder stores and concentrates bile by absorption of electrolytes and water. After a meal, entrance of lipid into the duodenum stimulates enteroendocrine cells of the duodenum to secrete cholecystokinin, which stimulates contraction and emptying of the gallbladder. At the same time, it relaxes the sphincter of Oddi in the ampulla of Vater. This delivers a bolus of bile into the duodenum.

Clinical Correlate

When stimulated during liver injury, Ito cells may release type I collagen and other matrix components into the space of Disse, **contributing to scarring** of the liver in some diseases (cirrhosis due to ethanol). This may lead to the development of portal hypertension, portacaval anastomoses, and esophageal or rectal bleeding.

Clinical Correlate

Disturbance of the balance in the components of bile can lead to precipitation of one or more of the bile components, resulting in stone (or **calculus**) formation or **lithiasis** in the gallbladder and/or bile ducts.

Note

Main Functions of Bile

- Absorption of fats from intestinal lumen
- Excretion
- Transport of IgA

ARTERIAL SUPPLY TO ABDOMINAL VISCERA

The blood supply to the abdominal viscera and the body wall is provided by branches of the abdominal aorta. The aorta enters the abdomen by passing through the aortic hiatus of the diaphragm at the **T12 vertebra** (Figure II-3-28). It descends on the lumbar vertebra just to the left of the midline and bifurcates at the **L4 vertebral** level. During its short course in the abdomen, the aorta gives origin to 3 groups of branches: (a) **3 unpaired visceral branches**, (b) **3 paired visceral branches**, and (c) several **parietal branches** to the body wall.

Note

Abdominal Aorta Branches

Visceral branches

Unpaired: celiac (foregut), superior mesenteric (midgut), inferior mesenteric (hindgut)

Paired: middle suprarenals, renals, gonadals

Parietal branches

Unpaired: median sacral

Paired: inferior phrenics, lumbars, common iliac

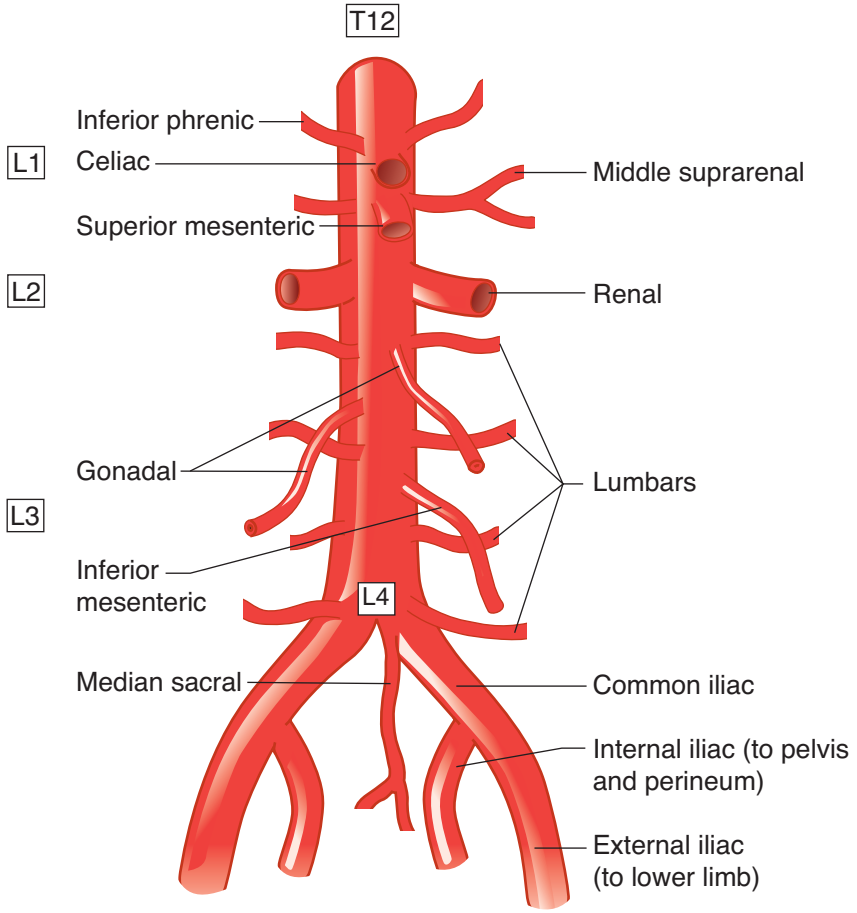

Figure II-3-29. Visceral and Parietal Branches of the Abdominal Aorta

Clinical Correlate

The most common site for an **abdominal aneurysm** is in the area between the renal arteries and the bifurcation of the abdominal aorta. Signs include decreased circulation to the lower limbs and pain radiating down the back of the lower limbs. The most common site of **atherosclerotic plaque** is at the bifurcation of the abdominal aorta.

Three Unpaired Visceral Arteries

Celiac Artery (Trunk)

The **celiac artery** is the blood supply to the structures derived from the foregut. The artery arises from the anterior surface of the aorta just inferior to the aortic hiatus at the level of T12–L1 vertebra. The celiac artery passes above the superior border of the pancreas and then divides into 3 retroperitoneal branches.

The **left gastric artery** courses superiorly and upward to the left to reach the **lesser curvature** of the stomach. The artery enters the lesser omentum and

follows the lesser curvature distally to the pylorus. The distribution of the left gastric includes the following:

- **Esophageal branch** to the distal one inch of the esophagus in the abdomen
- **Most of the lesser curvature**

The **splenic artery** is the longest branch of the celiac trunk and runs a very tortuous course along the superior border of the pancreas. The artery is retroperitoneal until it reaches the tail of the pancreas, where it enters the splenorenal ligament to enter the hilum of the spleen. The distributions of the splenic artery include:

- **Direct branches to the spleen**
- **Direct branches to the neck, body, and tail of pancreas**
- **Left gastroepiploic artery** that supplies the left side of the **greater curvature** of the stomach
- **Short gastric** branches that supply to the **fundus** of the stomach

The **common hepatic artery** passes to the right to reach the superior surface of the first part of the duodenum, where it divides into its 2 terminal branches:

- **Proper hepatic artery** ascends within the hepatoduodenal ligament of the lesser omentum to reach the porta hepatis, where it divides into the **right and left hepatic arteries**. The right and left arteries enter the 2 lobes of the liver, with the right hepatic artery first giving rise to the **cystic artery** to the gallbladder.
- **Gastroduodenal artery** descends posterior to the first part of the duodenum and divides into the **right gastroepiploic artery** (supplies the pyloric end of the greater curvature of the stomach) and the **superior pancreaticoduodenal arteries** (supplies the head of the pancreas, where it anastomoses the inferior pancreaticoduodenal branches of the superior mesenteric artery).

Clinical Correlate

- The **splenic artery** may be subject to erosion by a penetrating ulcer of **the posterior wall** of the stomach into the lesser sac.
- The **left gastric artery** may be subject to erosion by a penetrating ulcer of the **lesser curvature** of the stomach.
- The **gastroduodenal artery** may be subject to erosion by a penetrating ulcer of the **posterior wall** of the first part of the duodenum.

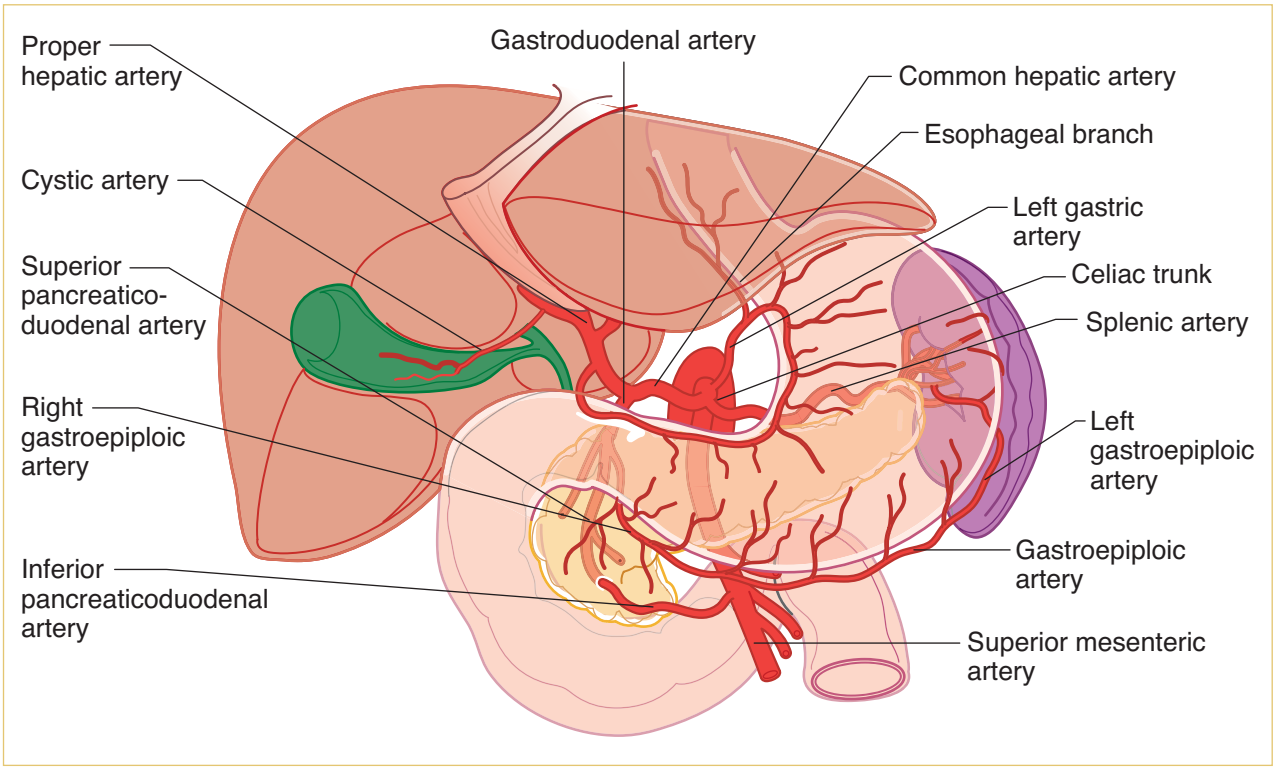

Figure II-3-30. Celiac Artery

Superior Mesenteric Artery

The **superior mesenteric artery** (SMA) supplies the viscera of the midgut. The SMA arises from the aorta deep to the neck of the pancreas just below the origin of the celiac artery at the L1 vertebral level. It then descends anterior to the uncinate process of the pancreas and the third part of the duodenum to enter the mesentery proper. The superior mesenteric vein is to the right of the artery. Branches of the SMA include:

- **Inferior pancreaticoduodenal arteries** which anastomose with the superior pancreaticoduodenal branches of the gastroduodenal artery in the head of the pancreas
- **Intestinal arteries** arise as 12–15 branches from the left side of the SMA and segmentally supply the jejunum and ileum. Distally, they form vascular arcades and vasa recta arteries at the wall of the gut.
- **Ileocolic artery** is the most inferior branch which descends to the lower right quadrant to supply the distal ileum and cecum.
- **Right colic artery** passes to the right to supply the ascending colon.
- **Middle colic artery** ascends and enters the transverse mesocolon to supply the proximal two-thirds of the transverse colon.

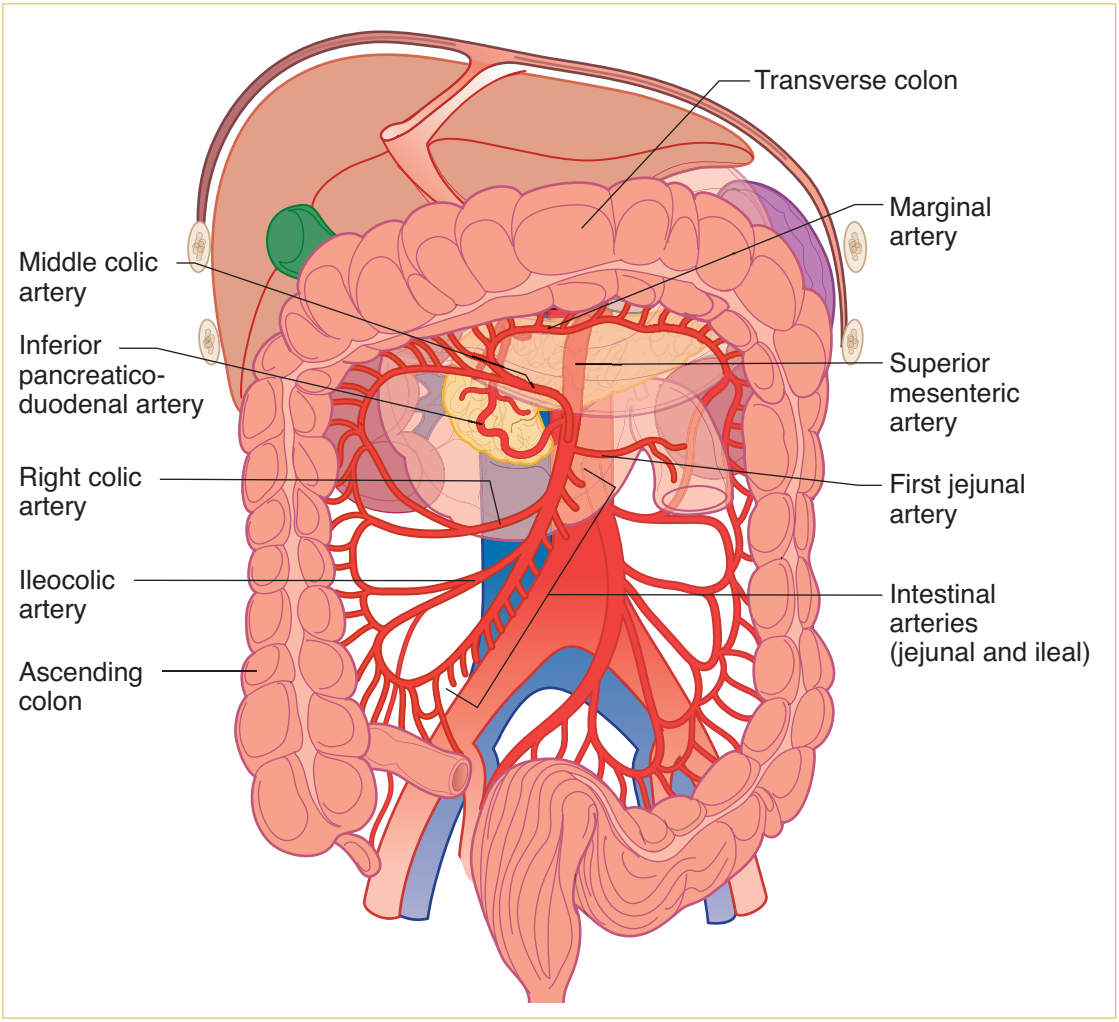

Figure II-3-31. Distribution of Superior Mesenteric Artery

Inferior Mesenteric Artery

The inferior mesenteric artery (IMA) is the third unpaired visceral branch of the aorta that supplies the hindgut (distal third of the transverse colon to the pectinate line). It arises from the aorta just above its bifurcation at the level of the L3 vertebra. It descends retroperitoneally and inferiorly to the left and gives rise to 3 branches:

- **Left colic artery** supplies the distal third of the transverse colon and the descending colon
- **Sigmoid arteries** to the sigmoid colon
- **Superior rectal artery** descends into the pelvis and supplies the superior aspect of the rectum and anal canal.

The branches of the SMA and IMA to the ascending, transverse and descending parts of the large intestines are interconnected by a continual arterial arch called the **marginal artery.** The marginal artery provides a collateral circulation between the parts of the large intestines if there is a vascular obstruction in some part of the SMA and IMA.

Clinical Correlate

Branches of the **celiac** and **superior mesenteric arteries** form a collateral circulation within the head of the pancreas.

Clinical Correlate

The **splenic flexure** is the most common site of bowel ischemia.

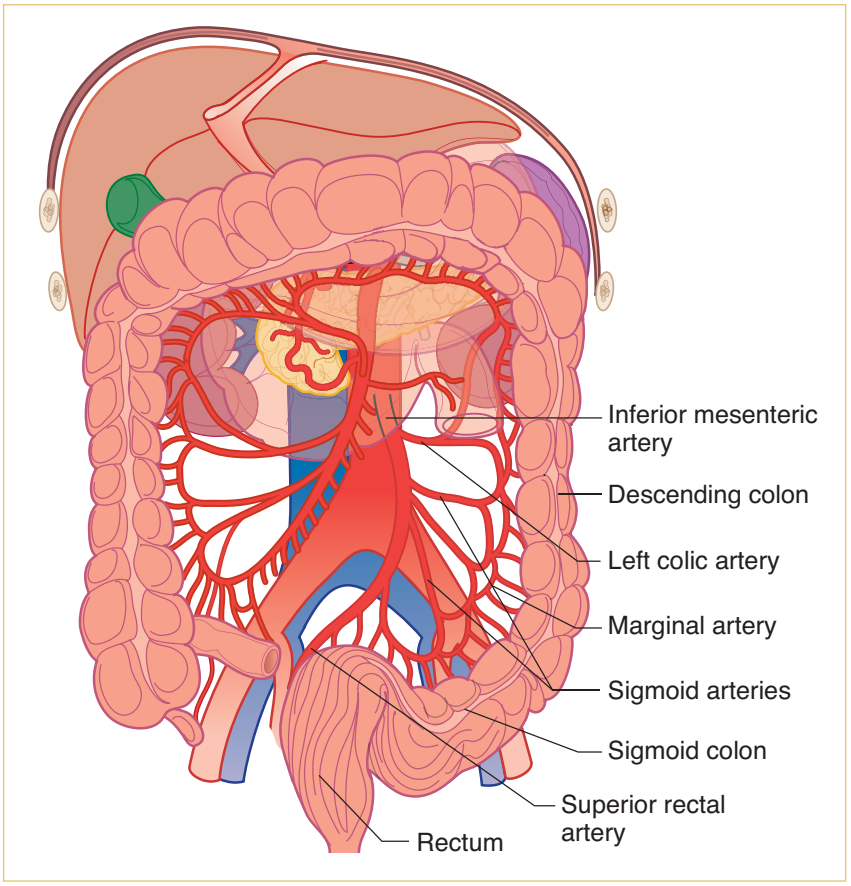

Figure II-3-32. Distribution of Inferior Mesenteric Artery

Clinical Correlate

The **left renal vein may be compressed** by an **aneurysm of the superior mesenteric artery** as the vein crosses anterior to the aorta. Patients with compression of the left renal vein may have renal and adrenal hypertension on the left, and, in males, a varicocele on the left.

Three Paired Visceral Arteries

- **Middle suprarenal arteries** branch from the aorta above the renal arteries and supply the medial parts of the suprarenal gland.
- **Renal arteries** are large paired vessels that arise from the aorta at the upper border of the L2 vertebra. They course horizontally to the hila of the kidneys. The right renal artery is the longer than the left and passes posterior to the inferior vena cava.
- **Gonadal arteries** arise from the anterior surface of the aorta just inferior to the renal arteries. They descend retroperitoneally on the ventral surface of the psoas major muscle.

VENOUS DRAINAGE OF ABDOMINAL VISCERA

Inferior Vena Cava

The **inferior vena cava** forms to the right of the lumbar vertebrae and the abdominal aorta by the union of the 2 common iliac veins at the **L5 vertebral level**. The inferior vena cava ascends to the right of the midline and passes through the caval hiatus of the diaphragm at the **T8 vertebral level**. The inferior vena cava receives blood from the lower limbs, pelvis and perineum,

paired abdominal viscera, and body wall. Note that the vena cava does not receive blood directly from the GI tract, except the lower rectum and anal canal.

The **right tributaries** (right gonadal, right suprarenal) drain separately into the inferior vena cava. But on the left side, the left gonadal and left suprarenal veins drain into the left renal vein, which then drains into the vena cava. The left renal vein crosses anterior to the aorta, just inferior to the origin of the superior mesenteric artery.

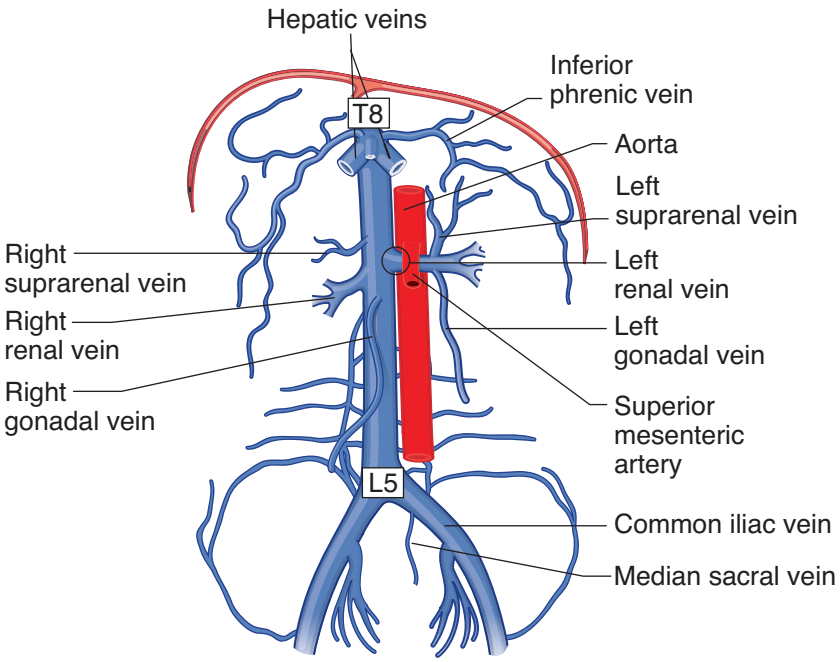

Figure II-3-33. Inferior Vena Cava and Tributaries

Hepatic Portal System

The **hepatic portal system** is an extensive network of veins that receives the blood flow from the GI tract above the pectinate line. The venous flow is carried to the liver via the **hepatic portal vein** where it enters the liver sinusoids, which drain to the hepatic veins, which then drain into the inferior vena cava and ultimately into the right atrium.

The hepatic portal vein is formed by the union of the **superior mesenteric** (drains midgut) and **splenic** (drains foregut) veins posterior to the **neck of the pancreas**. **The inferior mesenteric vein** (drains hindgut) usually drains into splenic vein.

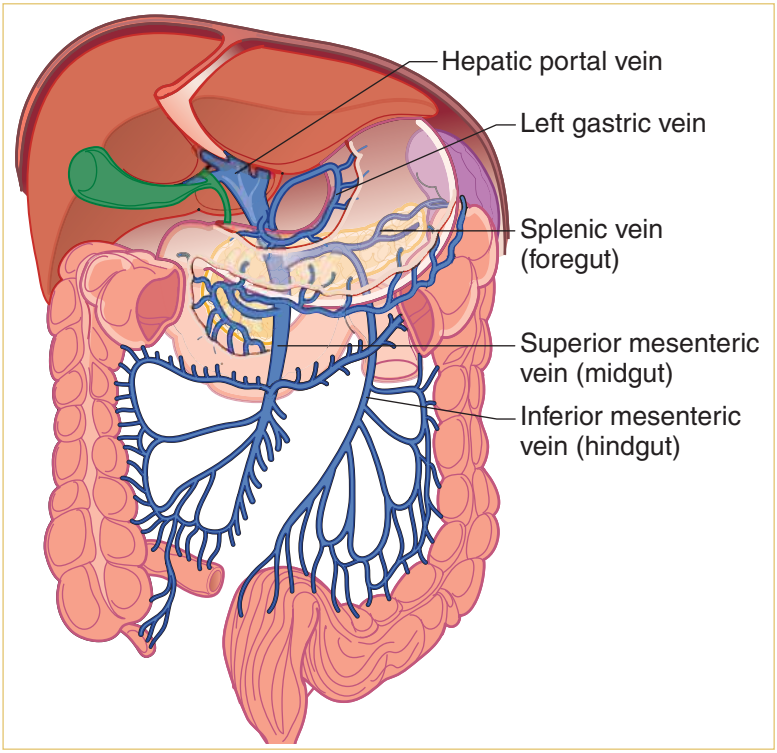

Figure II-3-34A. Hepatic Portal System

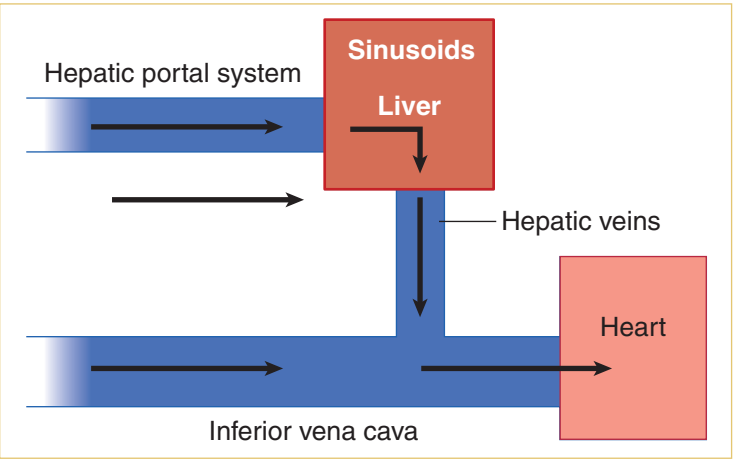

Figure II-3-34B. Comparison of Normal Caval and Portal Blood Flow

If there is an obstruction to flow through the portal system (**portal hypertension**), blood can flow in a retrograde direction (because of the absence of valves in the portal system) and pass through **anastomoses** to reach the caval system. Sites for these anastomoses include the **esophageal veins, rectal veins**, and **thoracoepigastric veins**. Enlargement of these veins may result in esophageal varices, hemorrhoids, or a caput medusae.

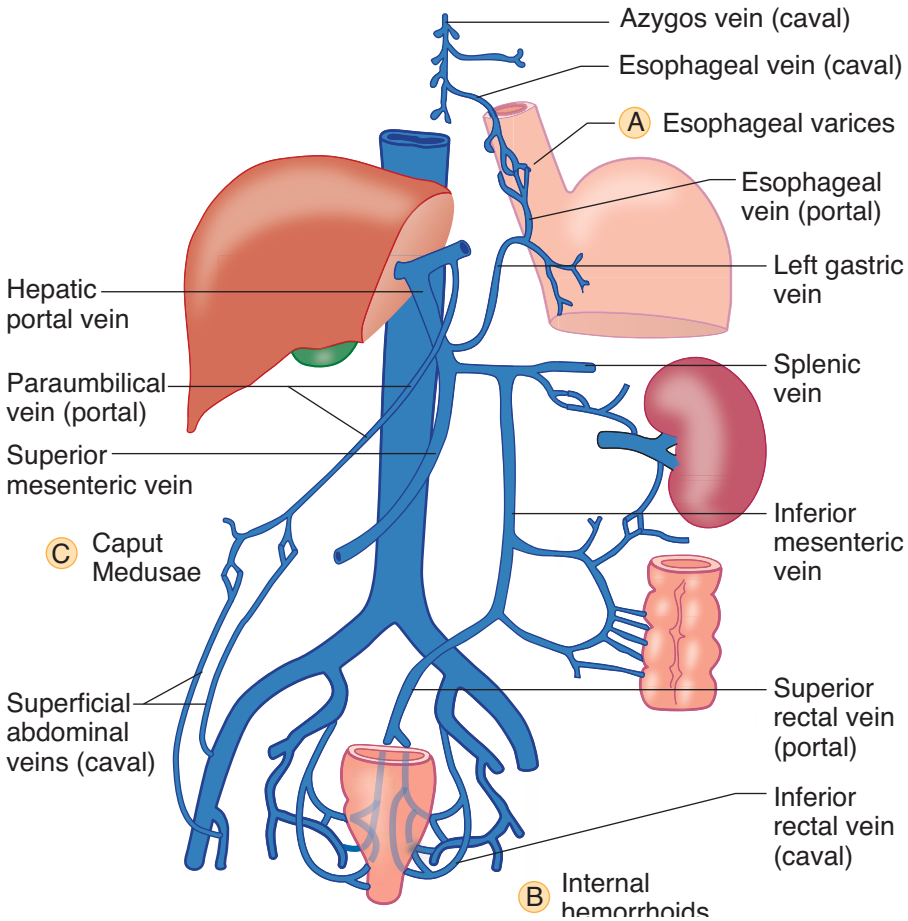

Figure II-3-35. Chief Portacaval Anastomoses

Table II-3-6. Sites of Portacaval Anastomoses

Sites of Anastomoses	Portal		Caval	Clinical Signs
Esophagus A	Esophageal veins (left gastric veins)	→	Veins of the thoracic esophagus, which drain into the azygos system	Esophageal varices
Rectum B	Superior rectal veins (inferior mesenteric vein)	→	Inferior rectal veins (internal iliac vein)	Internal hemorrhoids
Umbilicus C	Paraumbilical veins	→	Superficial veins of the anterior abdominal wall	Caput medusa

POSTERIOR ABDOMINAL BODY WALL

Embryology of Kidneys and Ureter

Renal development is characterized by 3 successive, slightly overlapping kidney systems: **pronephros**, **mesonephros**, and **metanephros**.

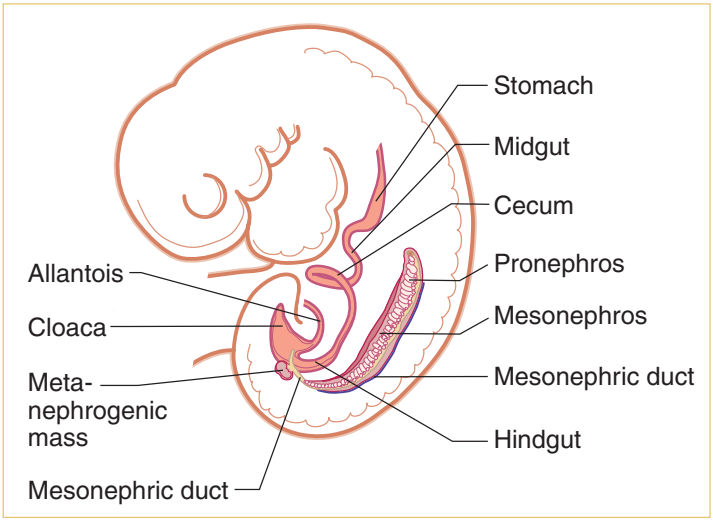

Figure II-3-36. Pronephros, Mesonephros, and Metanephros

During week 4, segmented nephrotomes appear in the cervical intermediate mesoderm of the embryo. These structures grow laterally and canalize to form nephric tubules. The first tubules formed regress before the last ones are formed. By the end of week 4, the pronephros disappears and does not function.

In week 5, the mesonephros appears as S-shaped tubules in the intermediate mesoderm of the thoracic and lumbar regions of the embryo.

- The medial end of each tubule enlarges to form a Bowman's capsule into which a tuft of capillaries, or glomerulus, invaginates.
- The lateral end of each tubule opens into the **mesonephric (Wolffian) duct**, an intermediate mesoderm derivative. The duct drains into the hindgut.
- Mesonephric tubules function temporarily and degenerate by the beginning of month 3. The mesonephric duct persists in the male as the ductus epididymidis, ductus deferens, and the ejaculatory duct. It disappears in the female.

During week 5, the metanephros, or permanent kidney, develops from 2 sources: the **ureteric bud**, a diverticulum of the mesonephric duct, and the **metanephric mass** (blastema), from intermediate mesoderm of the lumbar and sacral regions.

The **ureteric bud** penetrates the metanephric mass, which condenses around the diverticulum to form the metanephrogenic cap. The bud dilates to form the renal pelvis, which subsequently splits into the cranial and caudal major calyces. Each major calyx buds into the metanephric tissue to form the minor calyces.

One to 3 million collecting tubules develop from the minor calyces, thus forming the renal pyramids. The ureteric bud forms the **drainage components** of the urinary system (calyces, pelvis, ureter).

Penetration of collecting tubules into the **metanephric mass** induces cells of the tissue cap to form **nephrons**, or excretory units. Lengthening of the excretory tubule gives rise to the proximal convoluted tubule, the loop of Henle, and the distal convoluted tubule.

The kidneys develop in the pelvis but appear to ascend into the abdomen as a result of fetal growth of the lumbar and sacral regions. With their ascent, the ureters elongate, and the kidneys become vascularized by arteries which arise from the abdominal aorta.

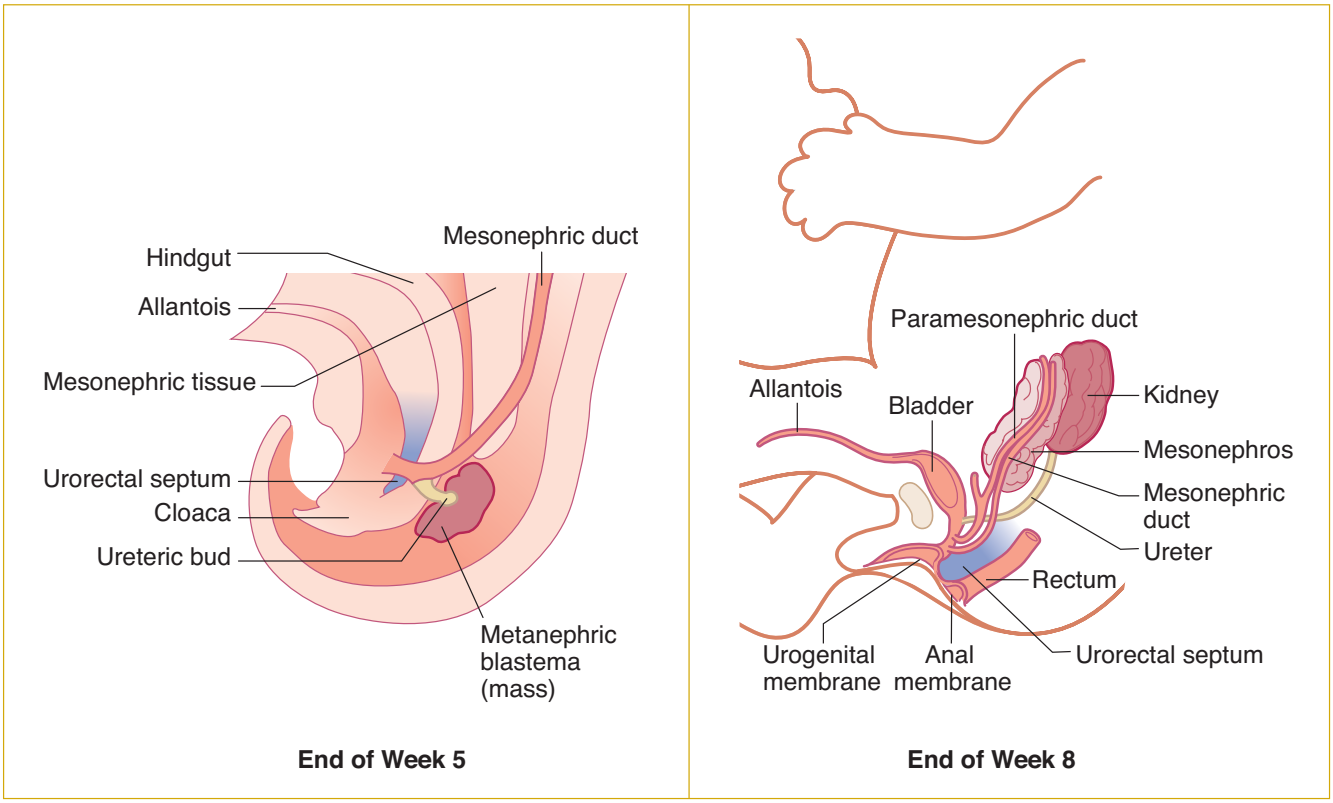

Figure II-3-37. Development of the Urinary System

Embryology of Bladder and Urethra

The **hindgut** does not rotate but it is divided into 2 parts by the **urorectal septum**. The urorectal septum divides the cloaca into the **anorectal canal** and the **urogenital sinus** by week 7.

The **urogenital sinus** is divided into 3 parts:

- The **upper** (cranial) and largest part of the urogenital sinus (endoderm) becomes the **urinary bladder**, which is initially continuous with the **allantois**.
  - The lumen of the allantois becomes obliterated to form a fibrous cord, the **urachus**. The urachus connects the apex of the bladder to the umbilicus. In the adult, this structure becomes the **median umbilical ligament**.
  - The **trigone of the bladder** is formed by the incorporation of the caudal mesonephric ducts into the dorsal bladder wall. This mesodermal tissue is eventually covered by endodermal epithelium so that the entire lining of the bladder is of **endodermal origin**. The smooth muscle of the bladder is derived from splanchnic mesoderm.
  - The mesonephric ducts also form the **ejaculatory ducts** as they enter the prostatic urethra.
- The **middle** part of the urogenital sinus (endoderm) will form all of the **urethra** of the female and the **prostatic, membranous, and proximal spongy urethra** in the male.
  - The **prostate gland** in the male is formed by an endodermal outgrowth of the prostatic urethra.
- The **inferior** part of the sinus forms the **lower vagina** and contributes to the primordia of the penis or the clitoris.

The **anorectal canal** forms the hindgut distally to the pectinate line.

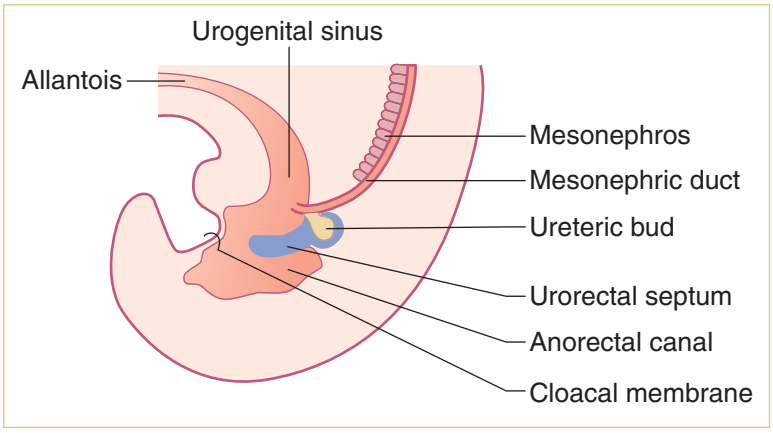

Figure II-3-38. Development of Bladder and Urethra

Congenital Abnormalities of the Renal System

Renal agenesis results from failure of one or both kidneys to develop because of early degeneration of the ureteric bud. Unilateral agenesis is fairly common; bilateral agenesis is fatal (associated with oligohydramnios, and the fetus may have **Potter sequence**: clubbed feet, pulmonary hypoplasia, and craniofacial anomalies).

Pelvic kidney is caused by a failure of one kidney to ascend. **Horseshoe kidney** (usually **normal renal function**, predisposition to calculi) is a fusion of both kidneys at their ends and failure of the fused kidney to ascend. The horseshoe kidney hooks under the origin of the **inferior mesenteric artery**.

Double ureter is caused by the early splitting of the ureteric bud or the development of 2 separate buds.

Failure of the allantois to be obliterated results in **urachal fistulas** or **sinuses**. In male children with congenital valvular obstruction of the prostatic urethra or in older men with enlarged prostates, a **patent urachus may cause drainage of urine through the umbilicus**.

Posterior Abdominal Wall and Pelvic Viscera

The **kidneys** are a pair of bean-shaped organs approximately 12 cm long. They extend from vertebral level T12 to L3 when the body is in the erect position. The right kidney is positioned slightly lower than the left because of the mass of the liver. Both kidneys are in contact with the diaphragm, psoas major, and quadratus lumborum.

- Right kidney: contacts the above structures and the 12th rib
- Left kidney: contacts the above structures and the 11th and 12th ribs

Ureters are fibromuscular tubes that connect the kidneys to the urinary bladder in the pelvis. They run posterior to the ductus deferens in males and posterior to the uterine artery in females. They begin as continuations of the renal pelves and run retroperitoneally, crossing the external iliac arteries as they pass over the pelvic brim. The ureter lies on the **anterior surface** of the **psoas major muscle**.

Clinical Correlate

The most common sites of ureteral constriction susceptible to **blockage by renal calculi** are:

- Where the renal pelvis joins the ureter
- Where the ureter crosses the pelvic inlet
- Where the ureter enters the wall of the urinary bladder

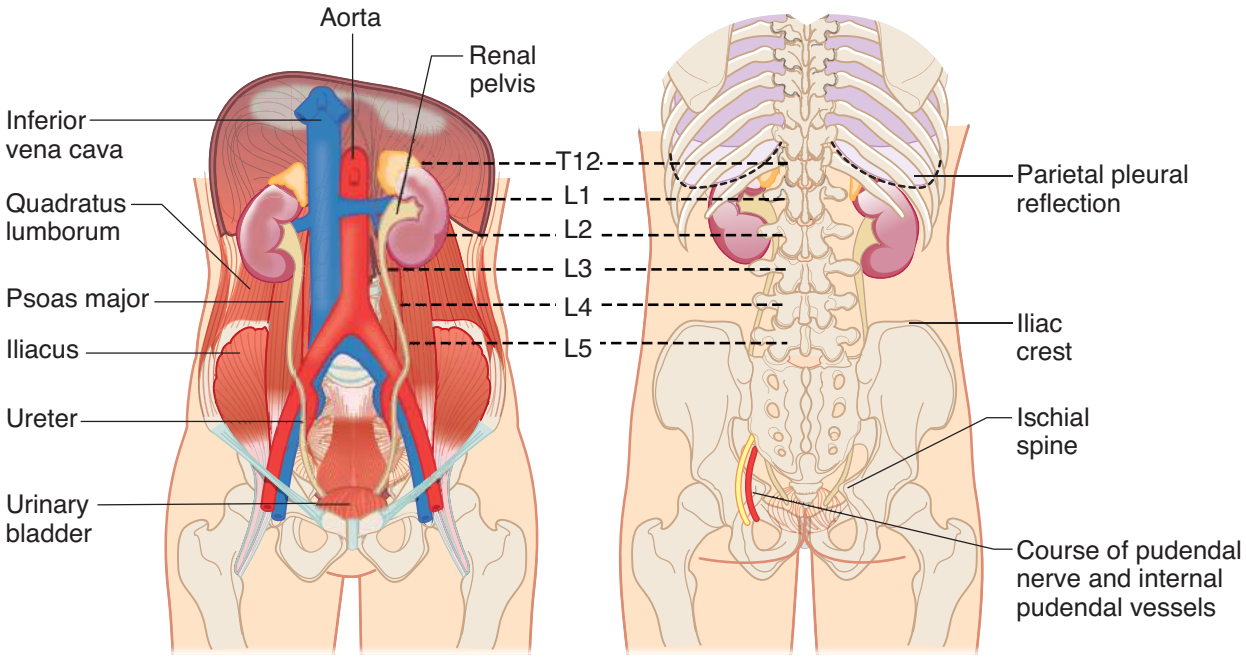

Figure II-3-39A. Muscles of the Posterior Abdominal Wall

Figure II-3-39B. Bony Landmarks of the Posterior Abdominal Wall

Note

Parasympathetic fibers facilitate micturition and sympathetic fibers inhibit micturition.

Clinical Correlate

Spastic bladder results from lesions of the spinal cord **above the sacral spinal cord levels**. There is a loss of inhibition of the parasympathetic nerve fibers that innervate the detrusor muscle during the filling stage. Thus, the detrusor muscle responds to a minimum amount of stretch, causing urge incontinence.

Clinical Correlate

Atonic bladder results from lesions **to the sacral spinal cord segments** or the sacral spinal nerve roots. Loss of pelvic splanchnic motor innervation with loss of contraction of the detrusor muscle results in a full bladder with a continuous dribble of urine from the bladder.

Clinical Correlate

Weakness of the **puborectalis** part of the levator ani muscle may result in **rectal incontinence**.

Weakness of the **sphincter urethrae** part of the urogenital diaphragm may result in **urinary incontinence**.

The **urinary bladder** is covered superiorly by peritoneum. The body is a hollow muscular cavity.

- The neck is continuous with the urethra.
- The trigone is a smooth, triangular area of mucosa located internally at the base of the bladder.
- The base of the triangle is superior and bounded by the 2 openings of the ureters. The apex of the trigone points inferiorly and is the opening for the urethra.
- **Blood Supply**
  - The bladder is supplied by vesicular branches of the internal iliac arteries and umbilical arteries.
  - The vesicular venous plexus drains to internal iliac veins.
- **Lymphatics**
  - Drain to the external and internal iliac nodes
- **Innervation**
  - Parasympathetic innervation is from sacral segments S2, S3, and S4. The preganglionic parasympathetic fibers travel in **pelvic splanchnic nerves** to reach the **detrusor muscle**.
  - Sympathetic innervation is through fibers derived from L1 through L2 (**lumbar splanchnics**). These fibers supply the **trigone muscle** and the **internal urethral sphincter**.
- **Muscles**
  - The **detrusor muscle** forms most of the smooth-muscle walls of the bladder and contracts during emptying of the bladder (micturition). The contraction of these muscles is under control of the parasympathetic fibers of the **pelvic splanchnics** (S2, 3, 4)
  - The **internal urethral sphincter** (sphincter vesicae) is smooth-muscle fibers that enclose the origin of the urethra at the **neck of the bladder**. These muscles are under control of the sympathetic fibers of the lower thoracic and **lumbar splanchnics** (T11-L2) and are activated during the filling phase of the bladder to prevent urinary leakage.
  - The **external urethral sphincter** (sphincter urethrae) is the voluntary skeletal muscle component of the urogenital diaphragm that encloses the urethra and is **relaxed** during micturition (voluntary muscle of micturition). The external sphincter is innervated by perineal branches of the **pudendal nerve**.

The **male urethra** is a muscular tube approximately 20 cm in length. The urethra in men extends from the neck of the bladder through the prostate gland (prostatic urethra) to the urogenital diaphragm of the perineum (membranous urethra), and then to the external opening of the glans (penile or spongy urethra).

The male urethra is anatomically divided into 3 portions: prostatic, membranous, and spongy (penile). The **distal spongy urethra** of the male is derived from the ectodermal cells of the glans penis.

The **female urethra** is approximately 4 cm in length and extends from the neck of the bladder to the external urethral orifice of the vulva.

URINARY HISTOLOGY AND FUNCTION

The urinary system consists of 2 kidneys, 2 ureters, the bladder, and the urethra.

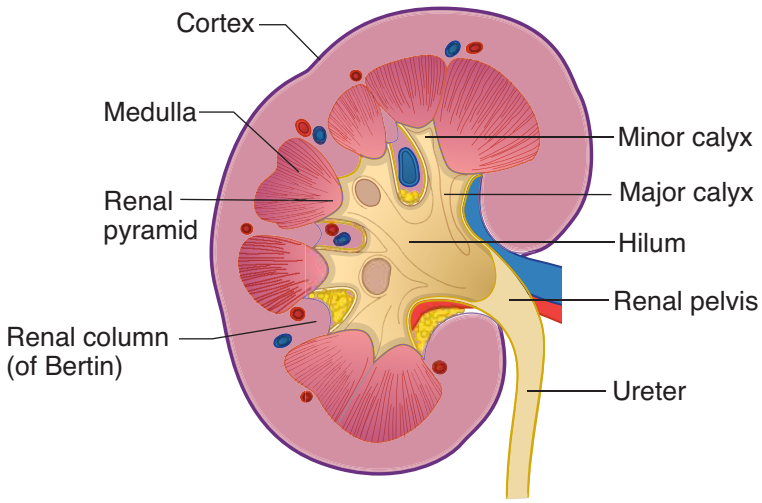

Figure II-3-40. Organization of the Kidney

Urinary Functions

The urinary system functions in the removal of waste products from blood. The kidney also functions in fluid balance, salt balance, and acid-base balance. The kidney functions as an endocrine gland; it produces and releases renin, which leads to an increase in extracellular fluid volume; erythropoietin, which stimulates erythropoiesis; and prostaglandins, which act as vasodilators.

A sagittal section through the center of a kidney shows a capsule (connective tissue) surrounding and protecting the organ, a wide band of cortex showing radial striations and the presence of glomeruli, and a medulla in the shape of an inverted pyramid. The medulla in turn shows an outer and inner zone. The blunted tip of the pyramid, called the **papilla**, borders a space that is surrounded by calices of the ureter. The collecting ducts are invaginations of the papilla's epithelium and the urine drains from their open ends into the calices.

Table II-3-7. Basic Functions of the Kidneys

Fluid balance	Maintain normal extracellular fluid (ECF) and intracellular fluid (ICF) volumes
Electrolytes	Balance excretion with intake to maintain normal plasma concentrations
Wastes	Excrete metabolic wastes (nitrogenous products, acids, toxins, etc.)
Fuels	Reabsorb metabolic fuels (glucose, lactate, amino acids, etc.)
Blood pressure	Regulate ECF volume for the long-term control of blood pressure
Acid–base	Regulate absorption and excretion of H^+ and HCO_3^- to control acid–base balance

Organization of the Kidney

The cortex is divided into lobules, and contains nephron elements mixed with vascular elements and stroma (a small amount of connective tissue). At the center of each lobule is a medullary ray, containing tubules that are parallel to each other and oriented radially in the cortex. The tubules in the medullary rays are continuous with those in the medulla. Along the 2 edges of each lobule are glomeruli, located along 1 or 2 rows. Radially oriented arterioles and venules with a large lumen are located at the edges of the lobules.

The medulla is comprised of radially arranged straight tubules which run from cortex to papilla, vascular elements, and stroma (a small amount of connective tissue). The medulla is divided into 2 zones. A wide strip in proximity to the cortex, the outer medulla contains profiles of tubules with different appearances. The inner medulla has fewer profiles of similar tubes.

Blood Circulation

The renal artery enters the kidney at the hilum, near the ureter. The artery branches into interlobar arteries, which travel to the medulla–cortex border remaining outside the medullary pyramids. The vessels branch into arcuate arteries (and veins) that follow the edge of the cortex. The arcuate arteries branch into interlobular arterioles that travel tangentially in the cortex at the edges of the lobules. Intralobular arterioles, feeding the glomeruli, branch off the interlobular arterioles at each renal corpuscle.

The kidneys receive 25% of total cardiac output, 1,700 liters in 24 hours. Each intralobular arteriole enters a renal corpuscle at the vascular pole as afferent arteriole and forms a convoluted tuft of capillaries (the glomerulus). A second arteriole (the efferent arteriole) exits the corpuscle. This is a unique situation due to the fact that the pressure remains high in the glomerulus in order to allow filtration.

The efferent arterioles carrying blood out of the glomeruli make a second capillary bed. This second capillary bed has lower blood pressure than the glomerulus and it connects to venules at its distal end. The arteriole-capillary-arteriole-capillary-vein sequence in the kidney is unique in the body. The efferent arterioles from glomeruli in the upper cortex divide into a complex capillary system in the cortex.

NEPHRON

The functional unit within the kidney is the nephron. Each kidney contains 1–1.3 million nephrons. Nephrons connect to collecting ducts, and collecting ducts receive urine from several nephrons and converge with each other before opening to and letting the urine flow out of the kidney. The nephron and the collecting duct form the uriniferous tubule.

The nephron is a tube about 55 mm in length in the human kidney. It starts at one end with Bowman's capsule, which is the enlarged end of the nephron. Bowman's capsule has been invaginated by a tuft of capillaries of the glomerulus so that it has 2 layers: the visceral layer is in direct contact with the capillary endothelium, and the parietal layer surrounds an approximately spherical urinary space. Bowman's capsule and glomerulus of capillaries form a renal corpuscle.

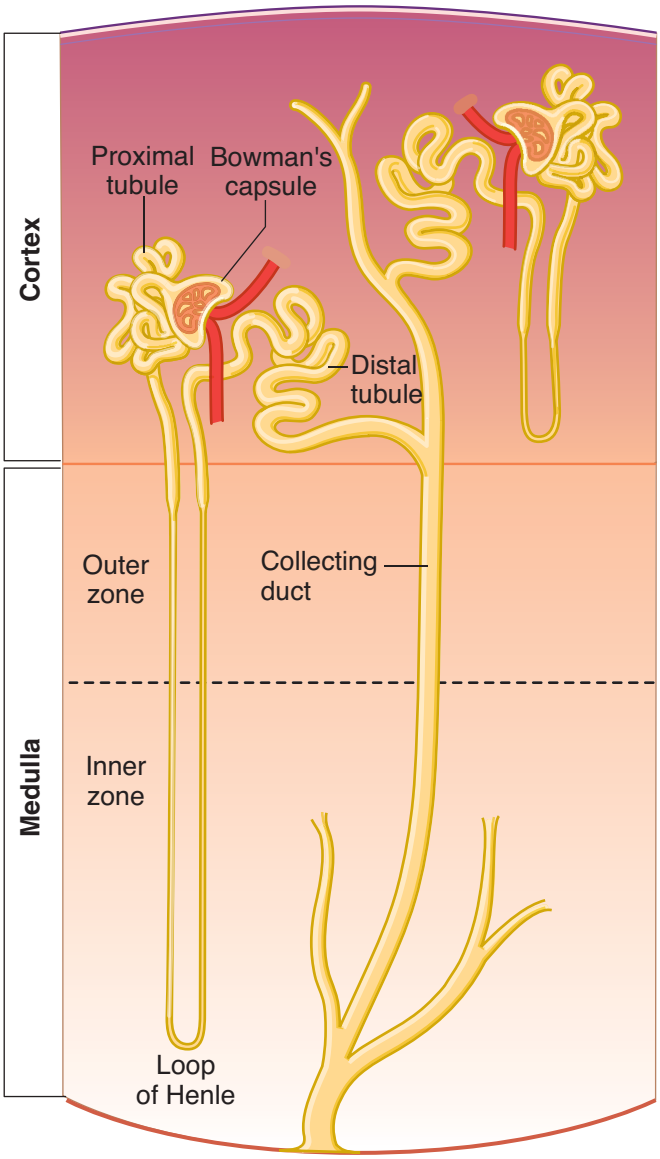

Figure II-3-41. Nephron

Renal Corpuscle

The parietal layer of Bowman's capsule is continuous with the walls of the proximal convoluted tubule (PCT). The visceral layer cells are called podocytes and have a complex shape; the cell body has extensive primary and secondary foot processes which surround the blood vessels. The foot processes of the podocytes lie a basal lamina that is shared by capillary endothelial cells. The podocyte foot processes almost completely cover the capillary surfaces, leaving small slits in between.

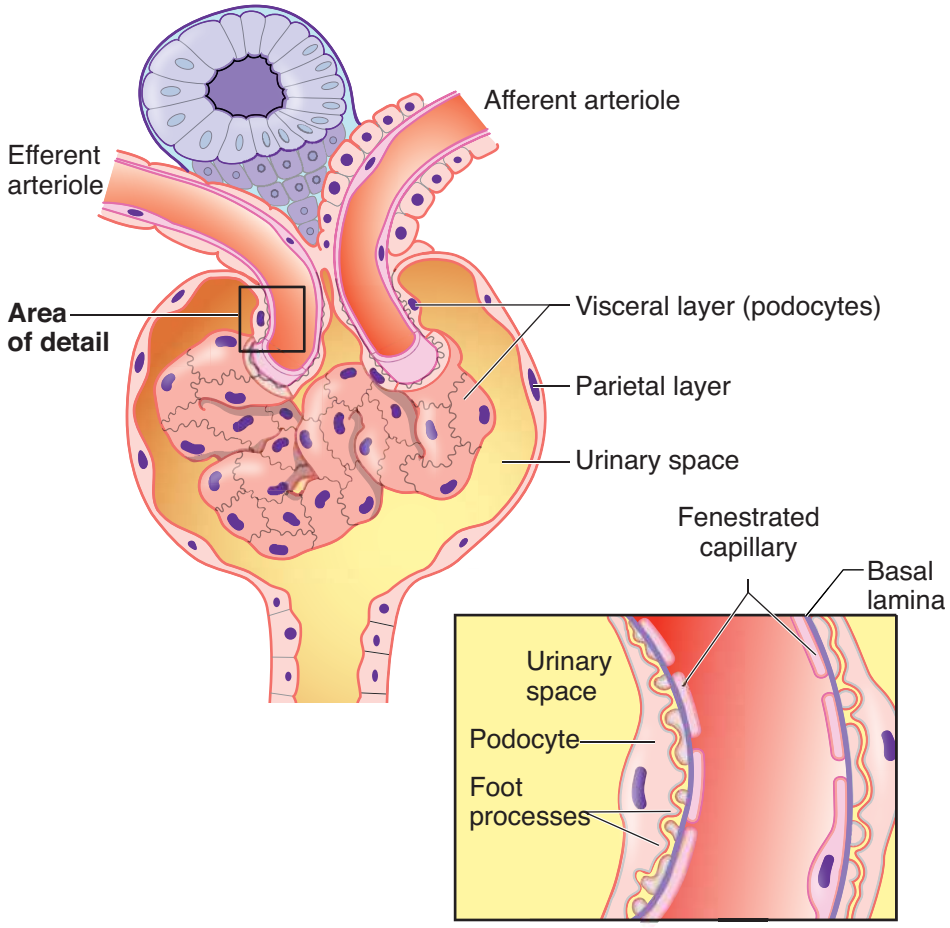

Figure II-3-42. Renal Corpuscle and Bowman's Capsule

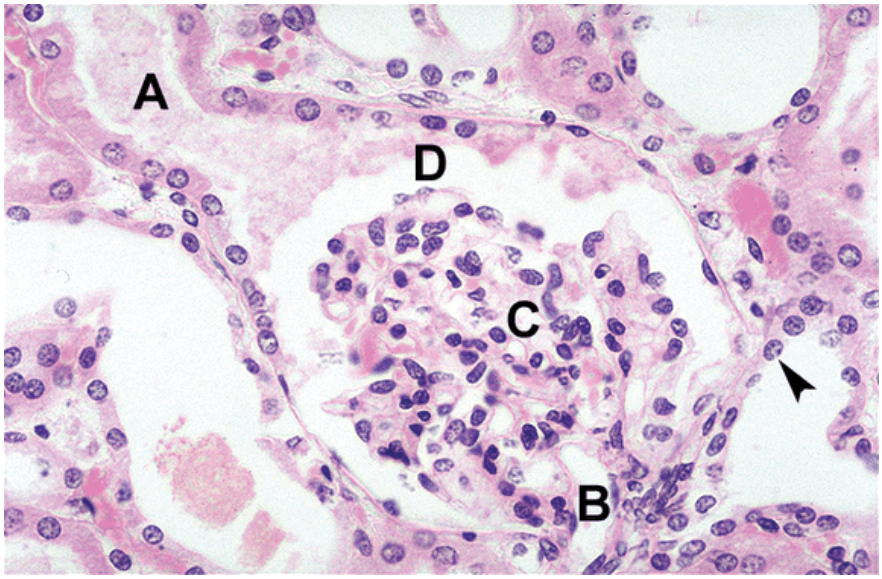

Copyright McGraw-Hill Companies. Used with permission.

Figure II-3-43. Renal corpuscle proximal tubule (A), vascular pole (B), glomerulus (C), and urinary space (D)
Simple cuboidal epithelium of the distal tubule (arrowhead)

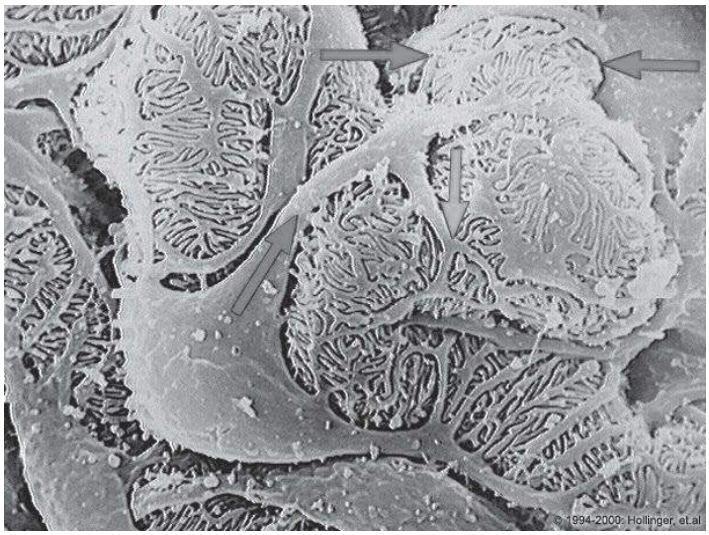

From the IMC, © 2010 DxR Development Group, Inc. All rights reserved.

Figure II-3-44. Scanning electron micrograph demonstrating podocytes with their processes (arrows)

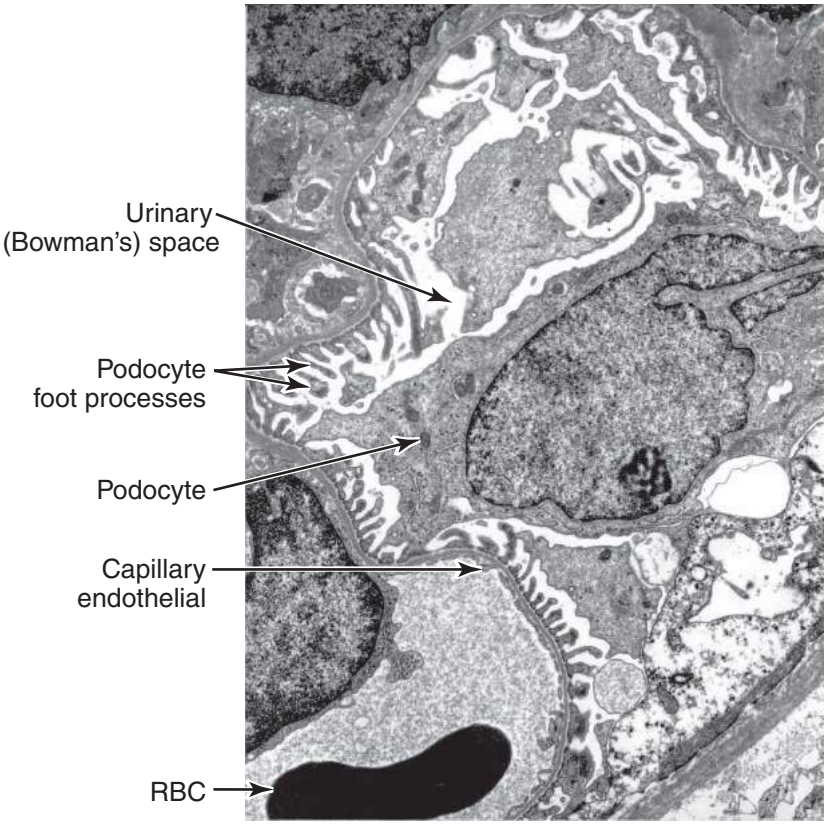

From the IMC, © 2010 DxR Development Group, Inc. All rights reserved.

Figure II-3-45. Transmission electron micrograph demonstrating podocytes

Blood plasma is filtered from the lumen of the capillary to the urinary space across the combined capillary endothelium-podocyte complex. Fenestrations in the endothelium are large (50–100 nm) and occupy 20% of the capillary surface. Fenestrations block the exit of cells, but allow free flow of plasma. The shared basal lamina of podocytes and endothelium constitutes the first, coarser filtration barrier; it blocks the passage of molecules larger than 70 kD.

The thin diaphragms covering the slit openings between the podocyte foot processes constitute a more selective filter. The slits are composed of elongated proteins which arise from the surface of the adjacent foot process cell membranes and join in the center of the slit, in a zipper-like configuration. The width of the junction between 2 adjacent podocytes varies between 20 and 50 nm, possibly as a function of perfusion pressures of the glomerulus.

Podocyte foot processes are motile (they contain actin and myosin). They are connected to each other by the slit diaphragm and to the basal lamina. The slit diaphragm molecular complex is associated with the actin cytoskeleton. Alterations in composition and/or arrangement of these complexes are found in many forms of human and experimental diseases.

Proximal Convoluted Tubule

The proximal convoluted tubule (PCT) opens at the urinary pole of Bowman's capsule. The PCT follows a circuitous path and ends with a straight segment that connects to the loop of Henle. PCT cells are tall, and they have a pink cytoplasm, long apical microvilli, and extensive basal invaginations. Numerous large mitochondria are located between the basal invaginations. The lateral borders of adjacent cells are extensively interdigitated. These characteristics are typical of cells involved in active transport. The lumen of the PCT is frequently clouded by microvilli which do not preserve well during the histologic preparation process.

Loop of Henle

The loop of Henle has a smaller diameter than the PCT and has descending and ascending limbs which go in opposite directions. Some loops of Henle have a wider segment before the distal tubule. The straight and convoluted segments of the distal convoluted tubule (DCT) follow. The straight portions of the PCT and DCT have traditionally been assigned to the loop of Henle (constituting the thick ascending and descending limbs) but they are now thought to be part of the PCT and DCT to which they are more similar. The special disposition of the loops of Henle descending and ascending branches, coupled with their specific transport and permeability properties, allow them to operate as "countercurrent multipliers," creating a gradient of extracellular fluid tonicity in the medulla. This is used to modulate urine tonicity and final volume.

Distal Convoluted Tubule

The DCT comes back to make contact with its own glomerulus, and then connects to the collecting tubule, which receives urine from several nephrons and is open at its far end. The epithelium of DCT, loops of Henle, and collecting ducts have variable thicknesses and more or less well-defined cell borders. Some have limited surface microvilli. In general, these tubes either do much less active transport than the PCT or are involved only in passive water movements.

Collecting Ducts

Collecting ducts are lined by principal cells and intercalated cells. The cell outline of these cells is more distinct than that of the PCT or the DCT. Principal cells respond to aldosterone.

Mesangial Cells

Mesangial cells (also known as Polkissen or Lacis cells) are located between capillaries, under the basal lamina but outside the capillary lumen. There is no basal lamina between mesangial and endothelial cells. Mesangial cells are phagocytic and may be involved in the maintenance of the basal lamina. Abnormalities of mesangial cells are detected in several diseases resulting in clogged and/or distorted glomeruli.

Note

Renal cortex and medullary fibroblasts (interstitial cells) produce erythropoietin.

Note

Diuretics act by inhibiting Na^+ resorption, leading to an increase in Na^+ and water excretion.

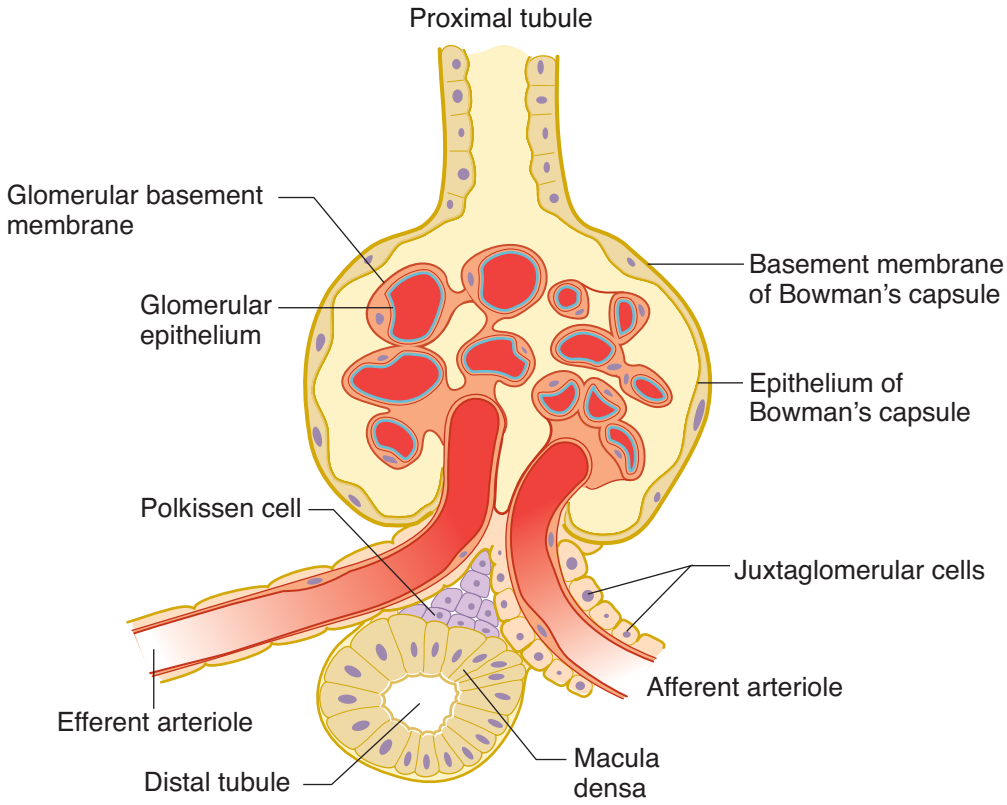

Figure II-3-46. Renal Corpuscle and Juxtaglomerular Apparatus

Juxtaglomerular Complex

The juxtaglomerular (JG) complex is a complex comprising JG apparatus (in the wall of the afferent arteriole), the macula densa (a special domain of the DCT), and a group of mesangial cells. The JG cells are modified smooth-muscle cells which secrete renin.

The macula densa is formed by tall cuboidal cells in the wall of the DCT which detect sodium levels in the tubular fluid.

PELVIS

Embryology of the Reproductive System

Table II-3-8. Embryology of Reproductive System

Male and Female Development			
Adult Female and Male Reproductive Structures Derived From Precursors of the Indifferent Embryo			
Adult Female	**Indifferent Embryo**	**Adult Male**	
Ovary, follicles, rete ovarii	Gonads	Testes, seminiferous tubules, rete testes	
	TDF $\xrightarrow{+}$		
Uterine tubes, uterus, cervix, and upper part of vagina	← Paramesonephric ducts	Appendix of testes	
	MIF $\xrightarrow{-}$		
Duct of Gartner	Mesonephric ducts	Epididymis, ductus deferens, seminal vesicle, ejaculatory duct	
	Testosterone $\xrightarrow{+}$		
Clitoris	Genital tubercle	Glans and body of penis	**DHT**
Labia minora	Urogenital folds	Ventral aspect of penis	
Labia majora	Labioscrotal swellings	Scrotum	

Abbreviations: DHT, dihydrotestosterone; MIF, Müllerian-inhibiting factors; TDF, testes-determining factor

Congenital Reproductive Anomalies

Female Pseudointersexuality

- 46,XX genotype
- Have ovarian (but no testicular) tissue and masculinization of the female external genitalia
- Most common cause is **congenital adrenal hyperplasia**, a condition in which the fetus produces excess androgens

Male Pseudointersexuality

- 46,XY genotype
- Testicular (but no ovarian) tissue and stunted development of male external genitalia
- Most common cause is inadequate production of dihydrotestosterone due to a 5α-reductase deficiency

5α-reductase 2 deficiency

- Caused by a mutation in the **5α-reductase 2 gene** that renders 5α-reductase 2 enzyme underactive in catalyzing the conversion of testosterone to dihydrotestosterone
- *Clinical findings:* underdevelopment of the penis and emission of sperm (microphallus, hypospadias, and bifid scrotum) and prostate. The epididymis, ductus deferens, seminal vesicle, and ejaculatory duct are normal
- At puberty, these patients undergo virilization due to an increased **T: DHT ratio**.

Complete androgen insensitivity (CAIS, or testicular feminization syndrome)

- Occurs when a fetus with a 46,XY genotype develops testes and female external genitalia with a rudimentary vagina; the uterus and uterine tubes are generally absent
- Testes may be found in the labia majora and are surgically removed to circumvent malignant tumor formation.
- Individuals present as normal-appearing females, and their psychosocial orientation is female despite their genotype.
- Most common cause is a mutation in the **androgen receptor (AR) gene** that renders the AR inactive.

Abnormalities of the Penis and Testis

Hypospadias

- Occurs when the urethral folds fail to fuse completely, resulting in the external urethral orifice opening onto the **ventral** surface of the penis.
- Generally associated with a poorly developed penis that curves ventrally, known as **chordee.**

Epispadias

- Occurs when the external urethral orifice opens onto the **dorsal** surface of the penis.
- Generally associated with exstrophy of the bladder.

Undescended testes (cryptorchidism)

Occurs when the testes fail to descend into the scrotum. Normally occurs within 3 months after birth.

- Bilateral cryptorchidism results in sterility.
- The undescended testes may be found in the abdominal cavity or in the inguinal canal.

Hydrocele of the testes

Occurs when a small patency of the processus vaginalis remains so that peritoneal fluid can flow into the processus vaginalis. Results in a fluid-filled cyst near the testes.

Pelvic and Urogenital Diaphragms

The **pelvic and urogenital diaphragms** are 2 important skeletal muscle diaphragms that provide support of the pelvic and perineal structures. They are each innervated by branches of the pudendal nerve.

- The **pelvic diaphragm** forms the muscular floor of the pelvis and separates the pelvic cavity from the perineum. The pelvic diaphragm is a strong support for the pelvic organs and transmits the distal parts of the genitourinary system and GI tract from the pelvis to the perineum.
  - The diaphragm is formed by 2 layers of fascia and the 2 muscles: the **levator ani** and coccygeus.
  - The **puborectalis** component of the levator ani muscle forms a muscular sling around the anorectal junction, marks the boundary between the rectum and anal canal, and is important in fecal continence.
- The muscular **urogenital diaphragm** is located in the perineum inferior to the pelvic diaphragm. It is formed by 2 muscles (**sphincter urethrae** and deep transverse perineus muscles) which extend horizontally between the 2 ischiopubic rami.
  - The diaphragm is penetrated by the urethra in the male and the urethra and vagina in the female.
  - The sphincter urethrae muscle serves as an **external urethral sphincter** (voluntary muscle of micturition) which surrounds the membranous urethra and maintains urinary continence.

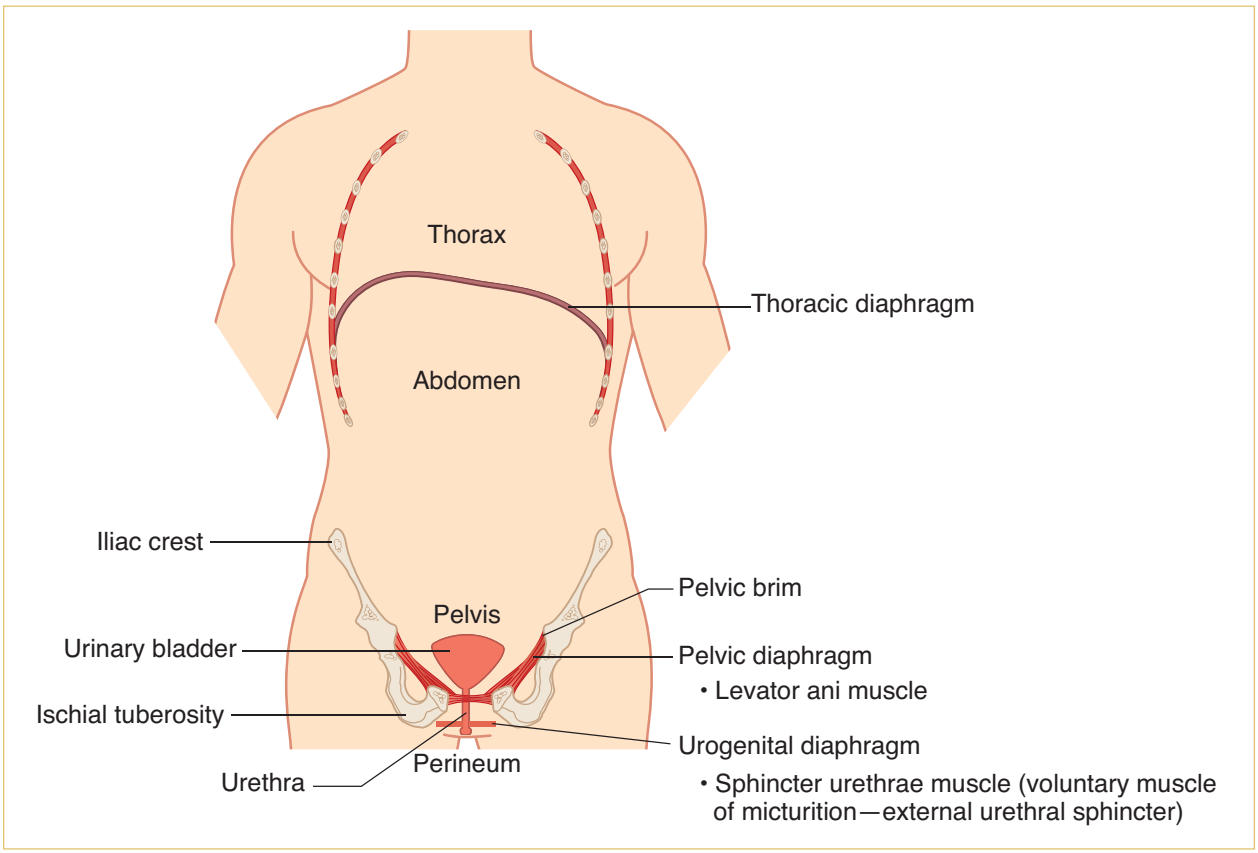

Figure II-3-47. Pelvic Diaphragm

Male Pelvic Viscera

The position of organs and peritoneum in the male pelvis is illustrated below.

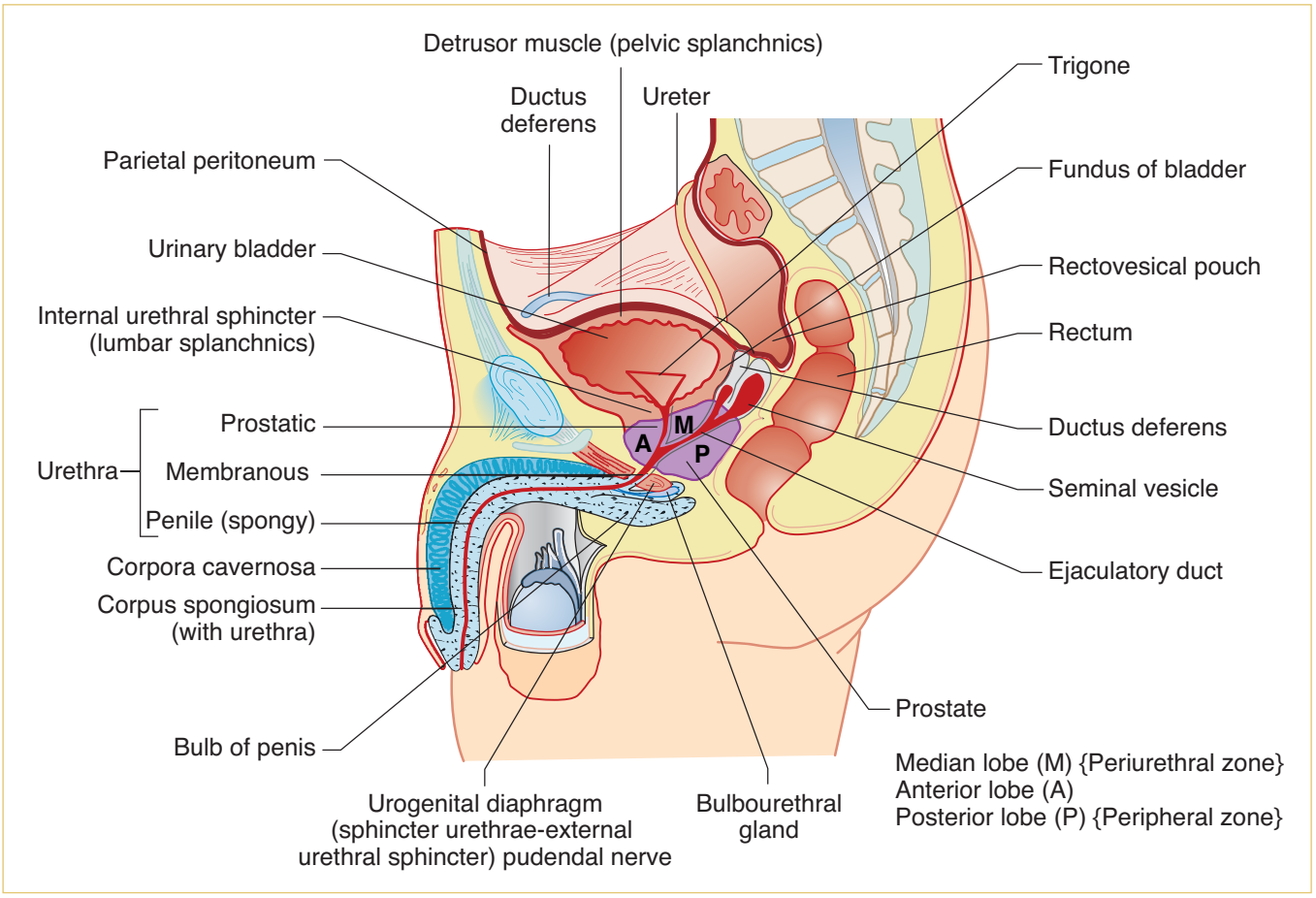

Figure II-3-48. Male Pelvis

Clinical Correlate

Hyperplasia of the Prostate

An enlarged prostate gland will compress the urethra. The patient will complain of the urge to urinate often and has difficulty with starting urination.

Because the prostate gland is enclosed in a dense connective tissue capsule, hypertrophy will compress the prostatic portion of the urethra.

Female Pelvic Viscera

The position of organs and peritoneum in the female pelvis is illustrated below.

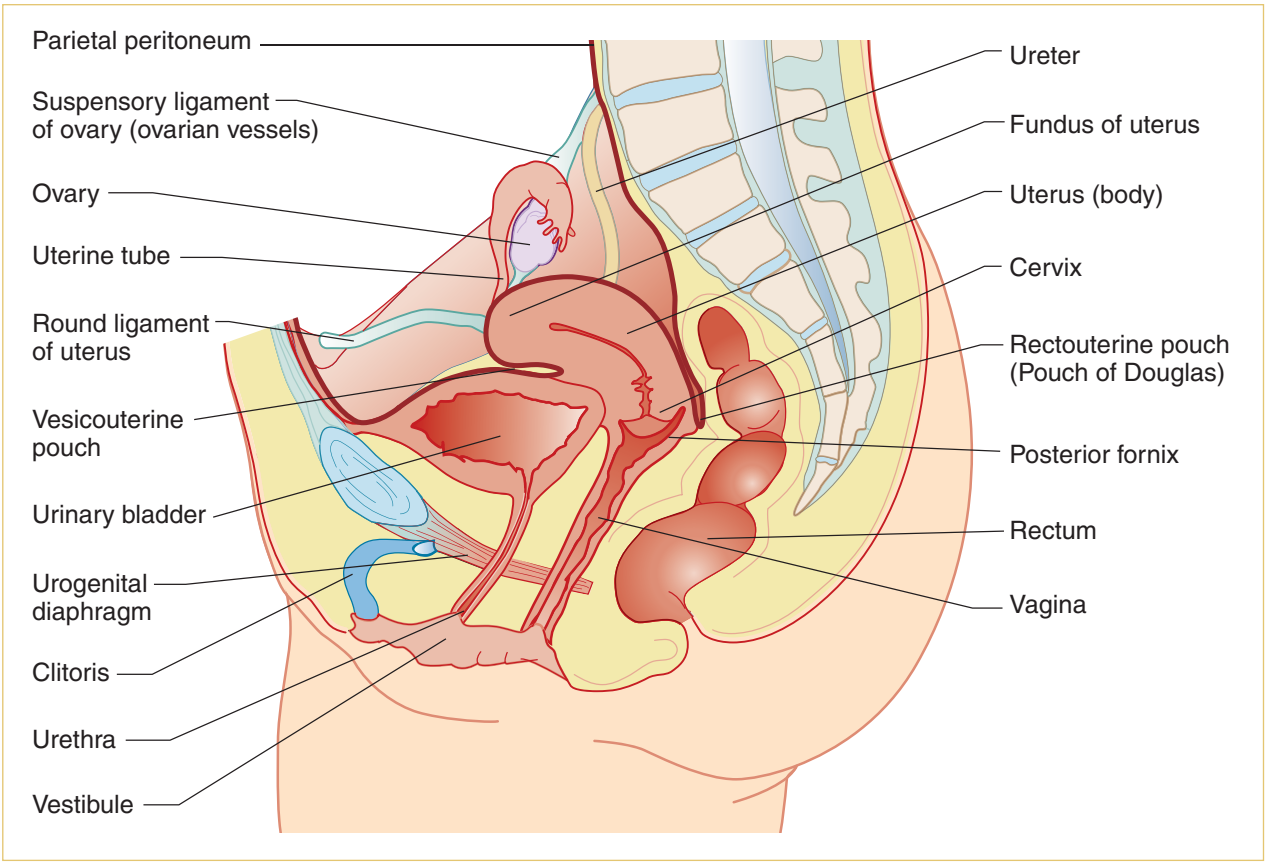

Figure II-3-49. Female Pelvis

Clinical Correlate

The ureter courses just medial to the suspensory ligament of the ovary and must be protected when ligating the ovarian vessels.

Clinical Correlate

Support for pelvic viscera is provided by the pelvic and urogenital diaphragms, perineal membrane, perineal body, and the transverse (cardinal) cervical and uterosacral ligaments. Weakness of support structures may result in **prolapse** of the uterus into the vagina or **herniation** of the bladder or rectum into the vagina.

Clinical Correlate

The ureter passes **inferior** to the uterine artery 1 to 2 centimeters from the cervix ("water under the bridge") and must be avoided during surgical procedures.

Uterus and Broad Ligament

A posterior view of the female reproductive tract is shown below.

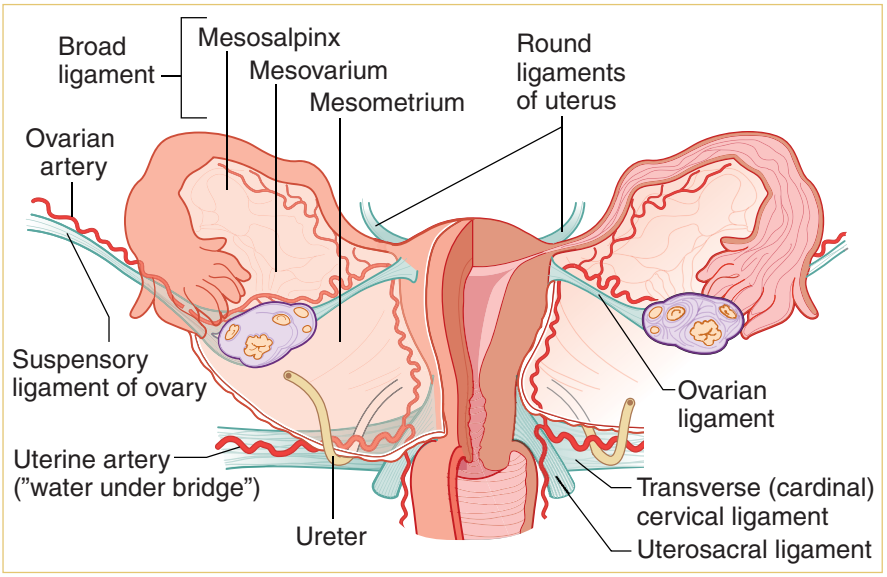

Figure II-3-50. Broad Ligament

PERINEUM

The **perineum** is the diamond-shaped outlet of the pelvis located below the pelvic diaphragm. It is divided by a transverse line between the ischial tuberosities into the **anal** and **urogenital triangles**.

- The sensory and motor innervation to the perineum is provided by the **pudendal nerve** (S2, 3, 4) of the sacral plexus.
- The blood supply is provided by the **internal pudendal artery,** a branch of the internal iliac artery.
- The pudendal nerve and vessels cross the ischial spine posteriorly to enter the perineum.

Clinical Correlate

A **pudendal nerve block** to anesthetize the perineum is performed as the pudendal nerve crosses posterior to the **ischial spine**.

Anal Triangle

The **anal triangle** is posterior and contains the **anal canal** surrounded by the fat-filled **ischioanal fossa**. The anal canal is guarded by a smooth-muscle **internal anal sphincter** innervated by the ANS and an **external anal sphincter** of skeletal muscle innervated by the pudendal nerve. The pudendal canal transmitting the pudendal nerve and internal pudendal vessels is found on the lateral aspect of the ischioanal fossa.

Urogenital Triangle

The **urogenital triangle** forms the anterior aspect of the perineum and contains the superficial and root structures of the external genitalia. The urogenital triangle is divided into **superficial** and **deep perineal spaces (pouches)**.

The **superficial perineal pouch** is located between the **perineal membrane** of the urogenital diaphragm and the **superficial perineal (Colles') fascia**. It contains:

- Crura of penis or clitoris: erectile tissue
- Bulb of penis (in the male): erectile tissue; contains urethra
- Bulbs of vestibule (in the female): erectile tissue in lateral walls of vestibule
- Ischiocavernosus muscle: skeletal muscle that covers crura of penis or clitoris
- Bulbospongiosus muscle: skeletal muscle that covers bulb of penis or bulb of vestibule
- Greater vestibular (Bartholin) gland (in female only): homologous to Cowper gland

The **deep perineal pouch** is formed by the fasciae and muscles of the **urogenital diaphragm**. It contains:

- Sphincter urethrae muscle—serves as voluntary external sphincter of the urethra
- Deep transverse perineal muscle
- Bulbourethral (Cowper) gland (in the male only)—duct enters bulbar urethra

Note

The **bulbourethral (Cowper) glands** are located in the **deep perineal pouch** of the male.

The **greater vestibular (Bartholin) glands** are located in the **superficial perineal pouch** of the female.

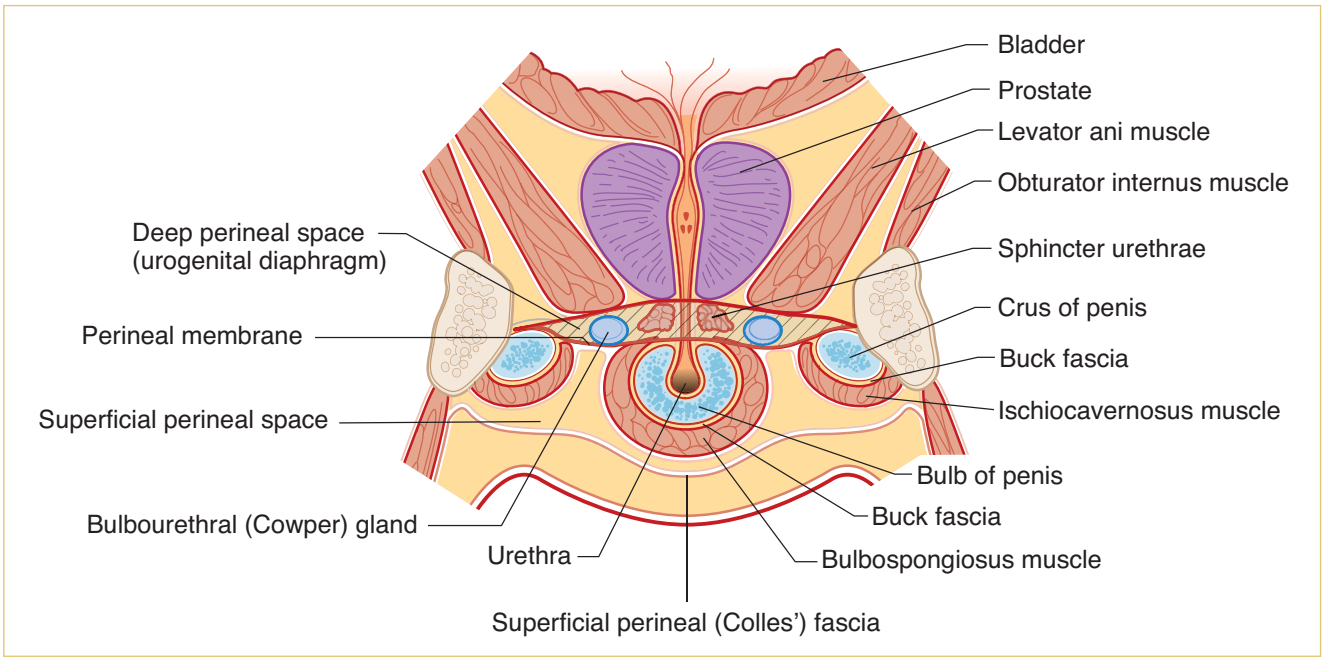

Figure II-3-51. Superficial and Deep Perineal Pouches of Male

External Genitalia

Male

Crura of penis are continuous with the corpora cavernosa of the penis.

Bulb of penis is continuous with corpus spongiosus of the penis (contains urethra).

Corpora cavernosa and corpus spongiosus form the shaft of the penis.

In the male, injury to the bulb of the penis (blue arrow) may result in extravasation of urine from the urethra into the superficial perineal space. From this space, urine may pass into the scrotum, into the penis, and onto the anterior abdominal wall in the plane deep to Scarpa fascia (green arrows).

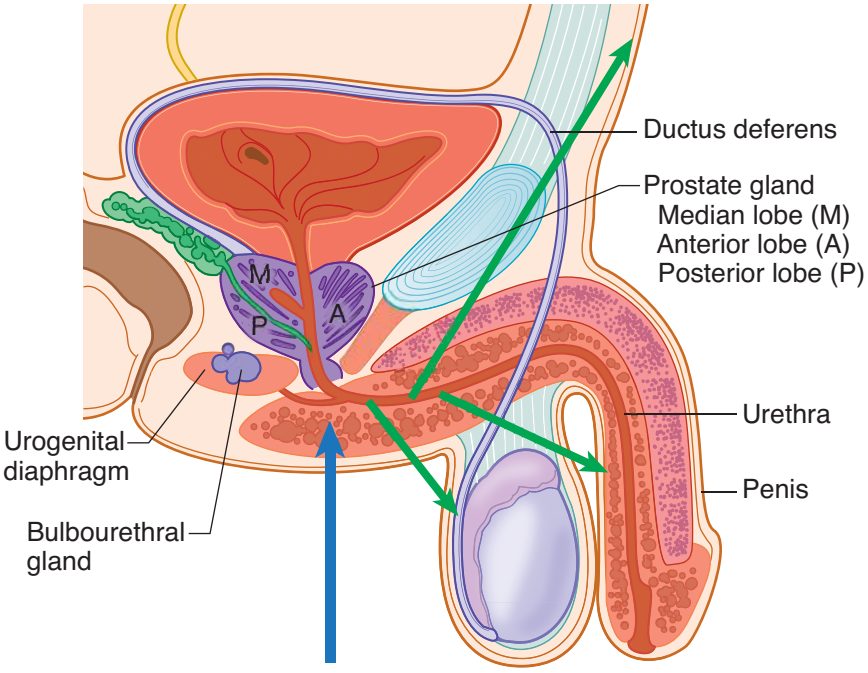

Figure II-3-52. Male Urethra

Female

Crura of the clitoris are continuous with the corpora cavernosa of the clitoris.

Bulbs of vestibule are separated from the vestibule by the labia minora.

Urethra and vagina empty into the vestibule.

Duct of greater vestibular glands enters the vestibule.

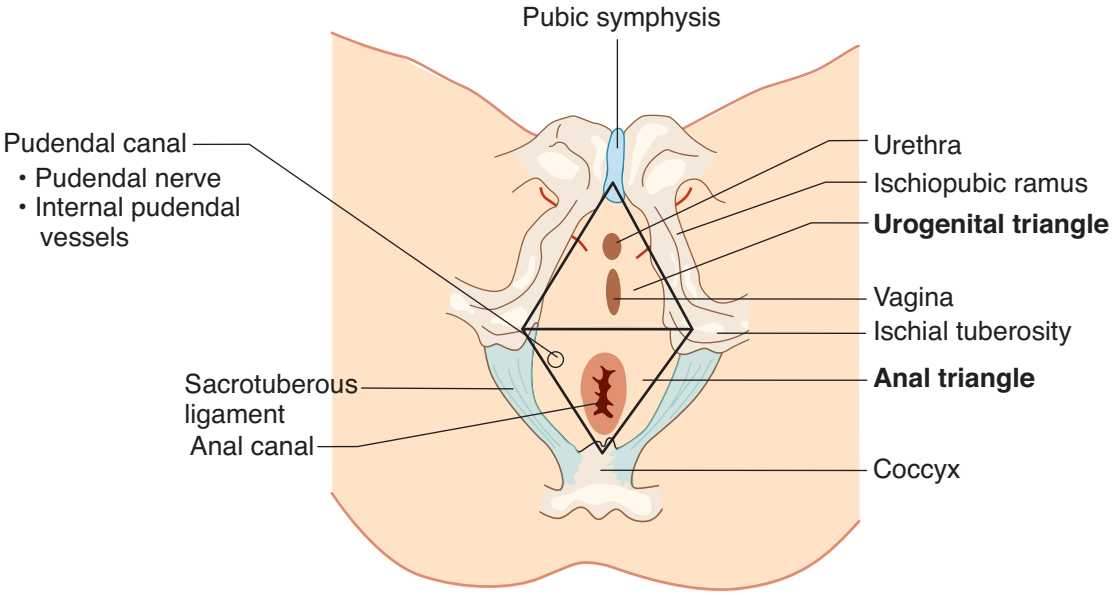

Figure II-3-53. Perineum of Female

Pelvic and Perineal Innervation

The **pudendal nerve (S2, S3, S4 ventral rami) and its branches** innervate the skeletal muscles in the pelvic and urogenital diaphragms, the external anal sphincter and the sphincter urethrae, skeletal muscles in both perineal pouches, and the skin that overlies the perineum.

MALE REPRODUCTIVE HISTOLOGY

Testis

The testis is surrounded by a dense fibrous capsule called the **tunica albuginea**. The tunica albuginea is continuous with many of the interlobular septa that divide the testis into approximately 250 pyramidal compartments (testicular lobules).

Within each lobule are 1-4 tubes, **seminiferous tubules**, where spermatozoa are produced. Each tubule is a coiled, non-branching closed loop that is 150–200 μm in diameter and 30–70 cm in length. Both ends of each tubule converge on the rete testes. The seminiferous tubules contain spermatogenic cells, Sertoli cells, and a well-defined basal lamina.

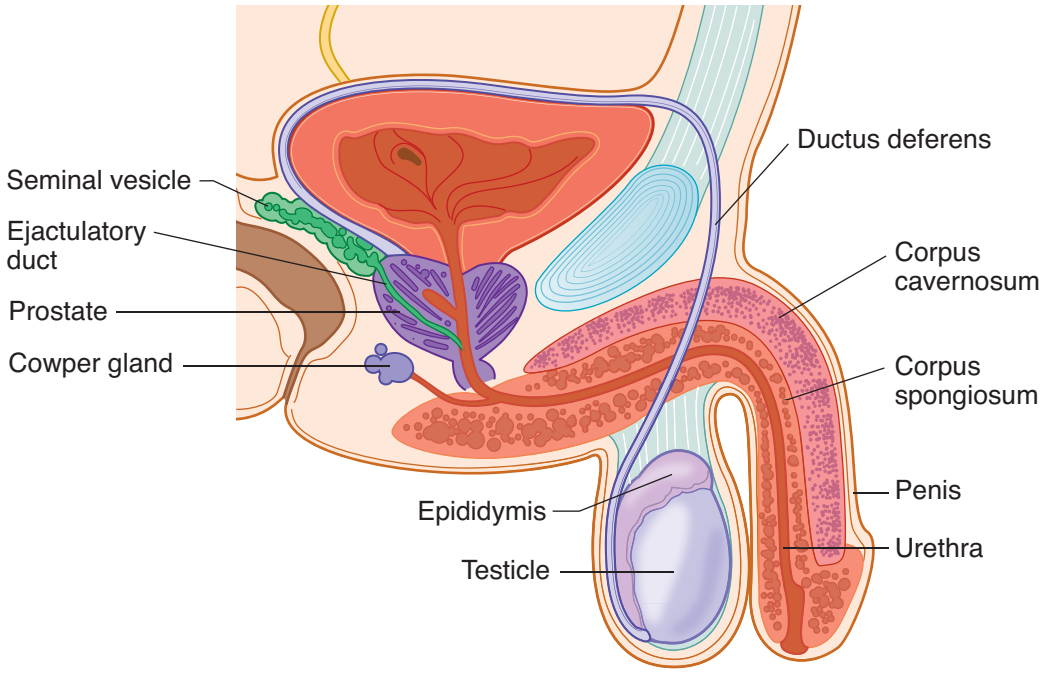

Figure II-3-54. Male Reproductive System

Note

The blood–testis barrier is formed by tight junctions between Sertoli cells and protects primary spermatocytes and their progeny.

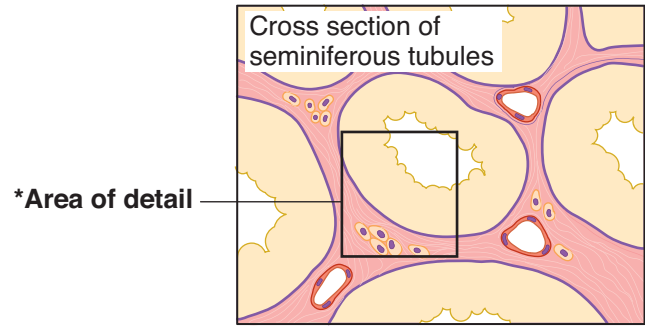

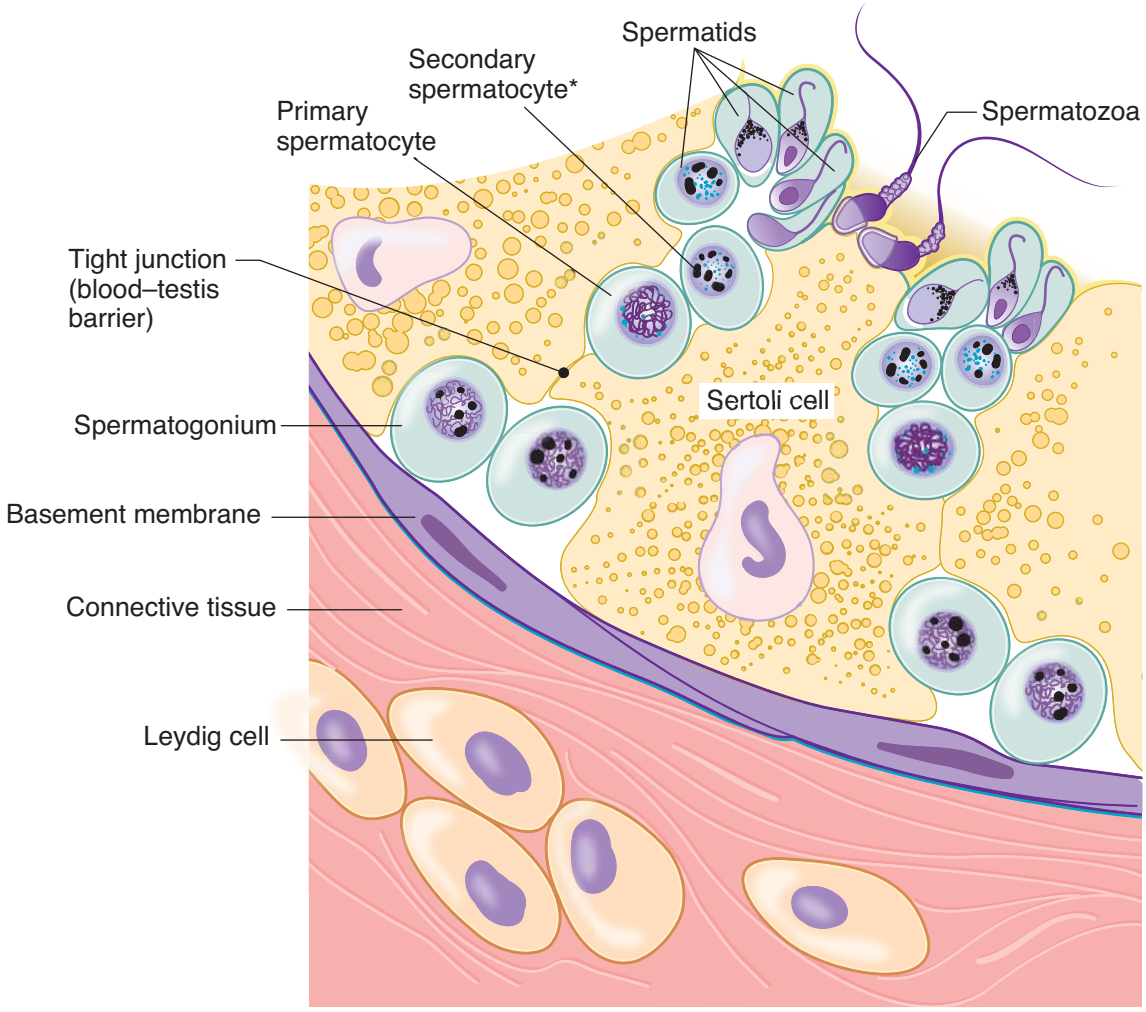

*least likely to be seen

Figure II-3-55. Seminiferous Tubule Diagram

Spermatogenesis

The spermatogenic cells (germinal epithelium) are stacked in 4 to 8 layers that occupy the space between the basement membrane and the lumen of the seminiferous tubule. The stem cells (**spermatogonia**) are adjacent to the basement membrane. As the cells develop, they move from the basal to the luminal side of the tubule.

At puberty the stem cells resume mitosis, producing more stem cells as well as differentiated spermatogonia (type A and B) that are committed to meiosis. **Type B spermatogonia** differentiate into primary spermatocytes that enter meiosis. **Primary spermatocytes** (4n, diploid) pass through a long prophase (10 days to 2 weeks) and after the first meiotic division form 2 secondary spermatocytes (2n, haploid). The **secondary spermatocytes** rapidly undergo the second meiotic division in a matter of minutes **(and are rarely seen in histologic sections)** to produce the **spermatids** (1n, haploid).

The progeny of a single maturing spermatogonium remain connected to one another by cytoplasmic bridges throughout their differentiation into mature sperm.

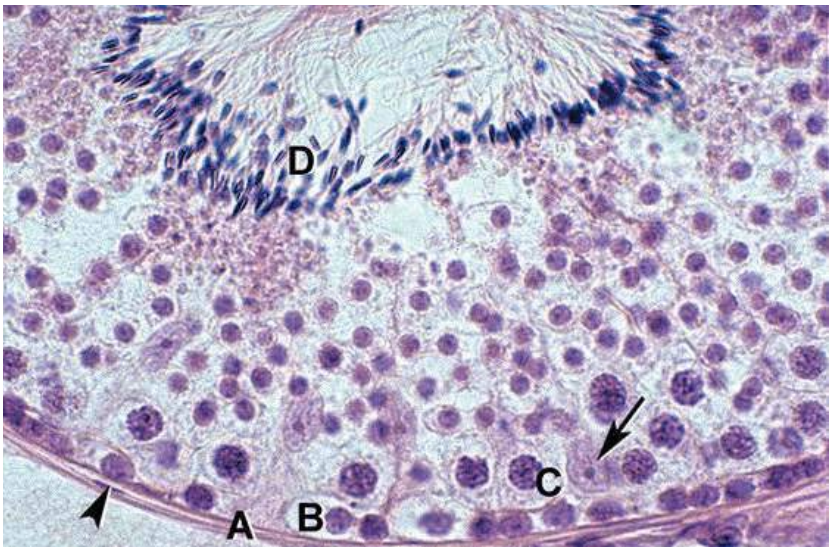

Copyright McGraw-Hill Companies. Used with permission.

Figure II-3-56. Seminiferous tubule surrounded by a basement membrane (A) and myoepithelial cells

Spermatogonia (B) lie on the basement membrane, primary spermatocytes (C), and spermatozoa (D) are inside the blood testis barrier. Sertoli cells (arrow) have elongated, pale-staining nuclei.

Spermiogenesis

Spermiogenesis transforms haploid spermatids into spermatozoa. This process of differentiation involves formation of the acrosome, condensation, and elongation of the nucleus; development of the flagellum; and loss of much of the cytoplasm.

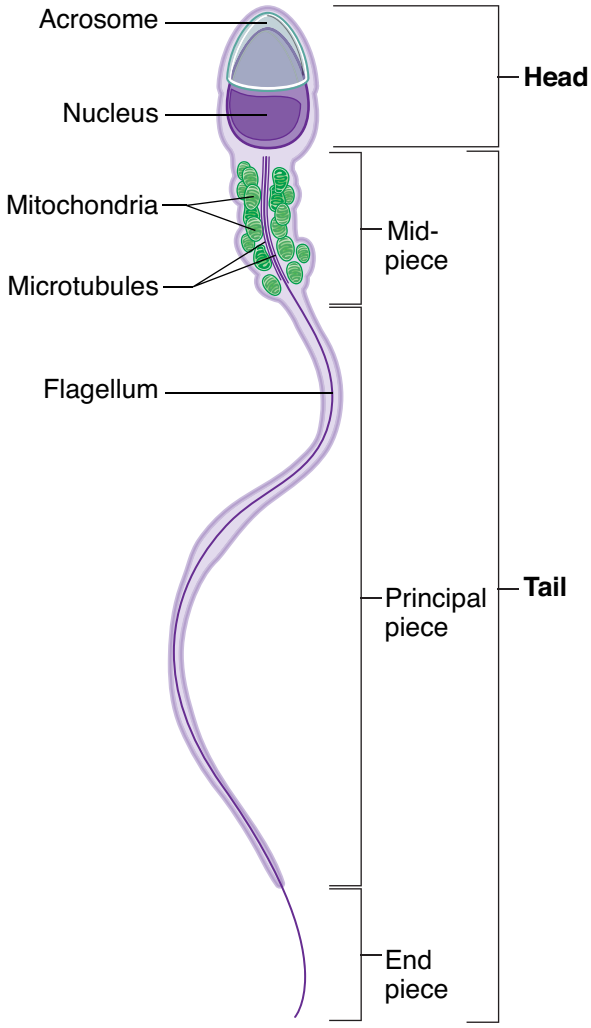

Figure II-3-57. Spermatozoan

The **acrosome**, which is located over the anterior half of the nucleus, is derived from the Golgi complex of the spermatid and contains several hydrolytic enzymes such as hyaluronidase, neuraminidase, and acid phosphatase; these enzymes dissociate cells of the corona radiata and digest the zona pellucida of the recently produced secondary oocyte.

The basic structure of a flagellum is similar to that of a cilium. Movement is a result of the interaction among microtubules, ATP, and dynein.

Sertoli Cells and the Blood–Testis Barrier

Sertoli cells are tall columnar epithelial cells. These multifunctional cells are the predominant cells in the seminiferous tubule prior to puberty and in elderly men but comprise only 10% of the cells during times of maximal spermatogenesis.

- Irregular in shape; the base adheres to the basal lamina and the apical end extends to the lumen. The nucleus tends to be oval with the long axis oriented perpendicular to the basement membrane.
- The cytoplasmic extensions make contact with neighboring Sertoli cells via tight junctions, forming the **blood–testis barrier** by separating the seminiferous tubule into a basal and an adlumenal compartment.
- Do not divide during the reproductive period.
- Support, protect, and provide nutrition to the developing spermatozoa. During spermiogenesis, the excess spermatid cytoplasm is shed as residual bodies that are phagocytized by Sertoli cells. They also phagocytize germ cells that fail to mature.
- Secrete **androgen-binding protein** that binds testosterone and dihydrotestosterone. High concentrations of these hormones are essential for normal germ-cell maturation. The production of androgen-binding protein is stimulated by **follicle-stimulating hormone** (FSH receptors are on Sertoli cells).
- Secrete **inhibin**, which suppresses FSH synthesis.
- Produce anti-Müllerian hormone during fetal life that suppresses the development of female internal reproductive structures.

The blood–testis barrier is a network of Sertoli cells which divides the seminiferous tubule into a basal compartment (containing the spermatogonia and the earliest primary spermatocytes) and an adlumenal compartment (containing the remaining spermatocytes and spermatids). The basal compartment has free access to material found in blood, while the more advanced stages of spermatogenesis are protected from blood-borne products by the **barrier** formed by the tight junctions between the Sertoli cells. The primary spermatocytes traverse this barrier by a mechanism not yet understood.

Interstitial Tissues of the Testis

The interstitial tissue lying between the seminiferous tubules is a loose network of connective tissue composed of fibroblasts, collagen, blood and lymphatic vessels, and **Leydig cells** (also called interstitial cells). The Leydig cells synthesize testosterone.

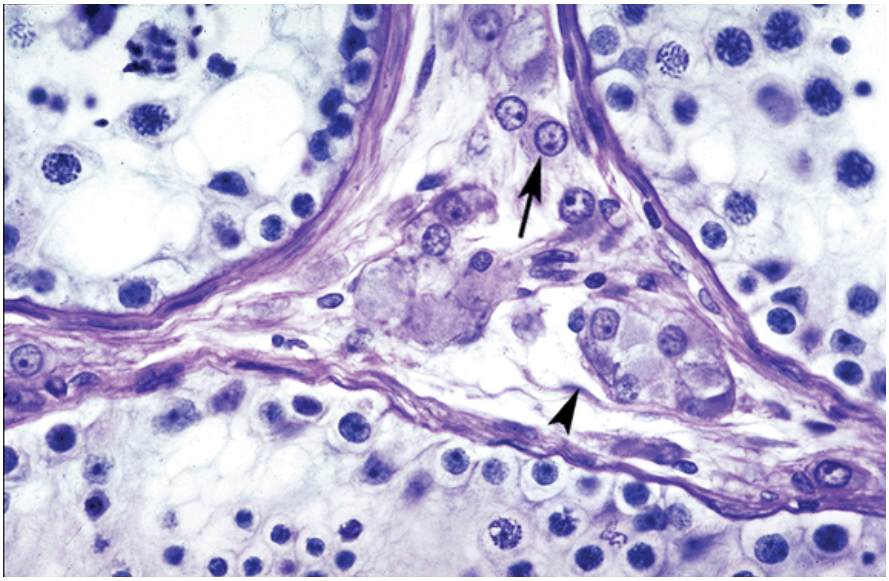

Copyright McGraw-Hill Companies. Used with permission.

Figure II-3-58. Interstitium between seminiferous tubules contains Leydig cells (arrow) and fibroblasts (arrowhead)

Genital Ducts

The seminiferous tubules empty into the **rete testis** and then into 10–20 **ductuli efferente**s. The ductuli are lined by a single layer of epithelial cells, some of which are ciliated. The ciliary action propels the nonmotile spermatozoa. The non-ciliated cells reabsorb some of the fluid produced by the testis. A thin band of smooth muscle surrounds each ductus.

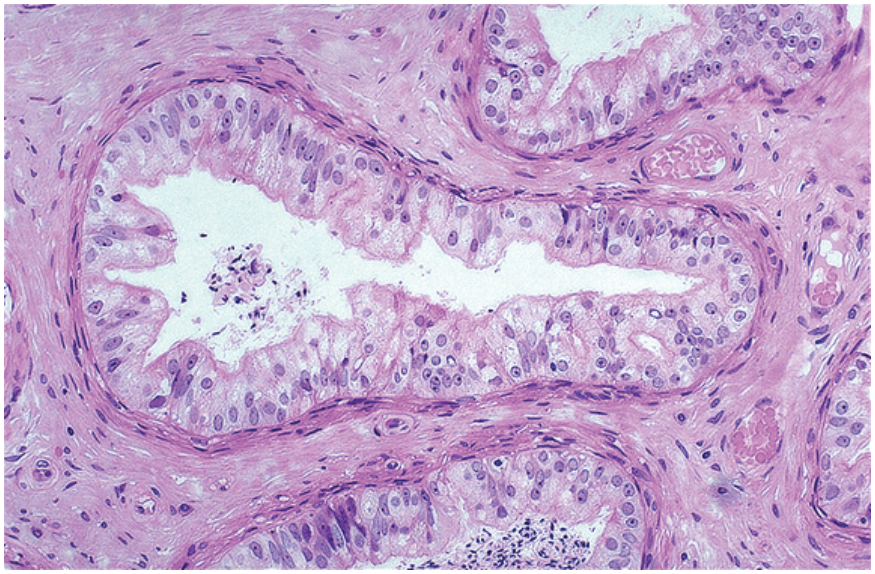

Copyright McGraw-Hill Companies. Used with permission.

Figure II-3-59. Efferent ductules with ciliated cuboidal and columnar cells

The spermatozoa pass from the ducti efferentes to the **epididymis**. The major function of this highly convoluted duct (approximately 5 m long) is the accumulation, storage, and maturation of spermatozoa. It is in the **epididymis** that the spermatozoa become motile. The epididymis is lined with a pseudostratified columnar epithelium which contains stereocilia (tall microvilli) on the luminal surface. This epithelium resorbs testicular fluid, phagocytizes residual bodies and poorly formed spermatozoa, and secretes substances thought to play a role in the maturation of spermatozoa.

Copyright McGraw-Hill Companies. Used with permission.

Figure II-3-60. Epididymis lined by pseudostratified columnar epithelium with stereocilia (arrow)

The **ductus (vas) deferens** conducts spermatozoa from the epididymis to the ejaculatory duct and then into the prostatic **urethra**. The ductus (vas) deferens is a thick walled muscular tube consisting of an inner and outer layer of longitudinal smooth muscle and an intermediate circular layer. Vasectomy or the bilateral ligation of the vas deferens prevents movement of spermatozoa from the epididymis to the urethra.

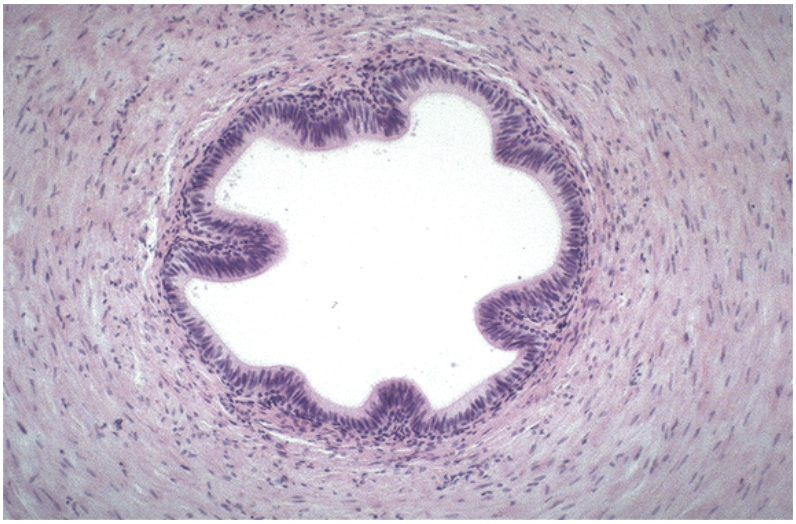

Copyright McGraw-Hill Companies. Used with permission.

Figure II-3-61. Ductus deferens with thick layers of smooth muscle

Accessory Glands

The **seminal vesicles** are a pair of glands situated on the posterior and inferior surfaces of the bladder. These highly convoluted glands have a folded mucosa lined with pseudostratified columnar epithelium. The columnar epithelium is rich in secretory granules that displace the nuclei to the cell base.

The seminal vesicles produce a secretion that constitutes approximately 70% of human ejaculate and is rich in spermatozoa-activating substances such as fructose, citrate, prostaglandins, and several proteins. Fructose, which is a major nutrient for sperm, provides the energy for motility. The duct of each seminal vesicle joins a ductus deferens to form an ejaculatory duct. The ejaculatory duct traverses the prostate to empty into the prostatic urethra.

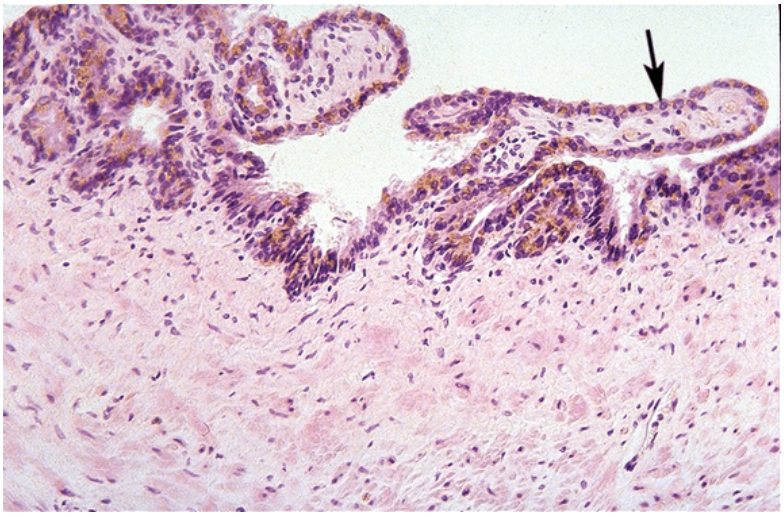

Copyright McGraw-Hill Companies. Used with permission.

Figure II-3-62. Seminal vesicle showing mucosal folds lined with pseudostratified columnar epithelium (arrow)

The **prostate** is a collection of 30–50 branched tubuloalveolar glands whose ducts empty into the urethra. The prostate is surrounded by a fibroelastic capsule that is rich in smooth muscle. There are 2 types of glands in the prostate, periurethral submucosal glands and the main prostatic glands in the periphery. Glandular epithelium is pseudostratified columnar with pale, foamy cytoplasm and numerous secretory granules. The products of the secretory granules include acid phosphatase, citric acid, fibrinolysin, and other proteins.

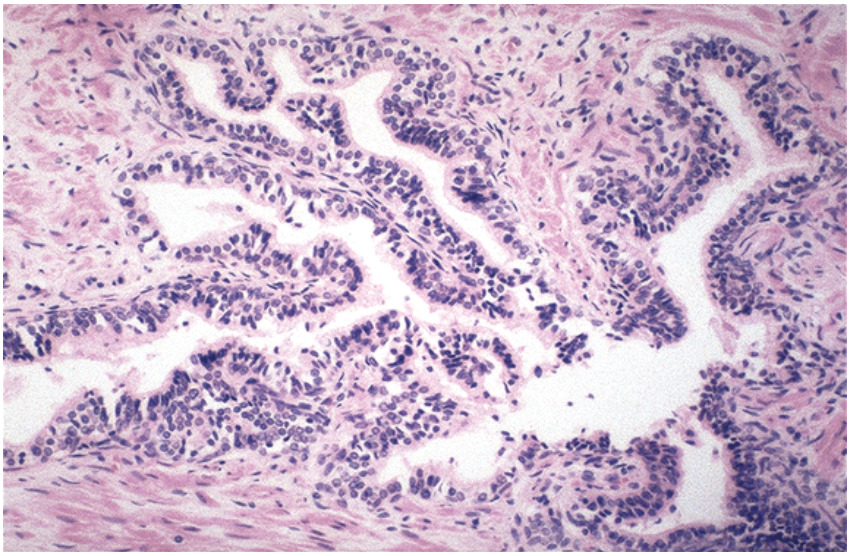

Copyright McGraw-Hill Companies. Used with permission.

Figure II-3-63. Prostate with tubuloalveolar glands lined by pseudostratified columnar epithelium

Table II-3-9. Male Reproductive Physiology

Penile Erection
Erection occurs in response to **parasympathetic** stimulation (pelvic splanchnic nerves). **Nitric oxide** is released, causing relaxation of the corpus cavernosum and corpus spongiosum, which allows blood to accumulate in the trabeculae of erectile tissue.
Ejaculation
• **Sympathetic** nervous system stimulation (lumbar splanchnic nerves) mediates movement of mature spermatozoa from the epididymis and vas deferens into the ejaculatory duct. • Accessory glands such as the bulbourethral (Cowper) glands, prostate, and seminal vesicles secrete fluids that aid in sperm survival and fertility. • **Somatic motor efferents** (pudendal nerve) that innervate the bulbospongiosus and ischiocavernous muscles at the base of the penis stimulate the rapid ejection of semen out the urethra during ejaculation. Peristaltic waves in the vas deferens aid in a more complete ejection of semen through the urethra.

Clinical Correlate

- Injury to the bulb of the penis may result in extravasation of urine from the urethra into the superficial perineal space. From this space, urine may pass into the scrotum, into the penis, and onto the anterior abdominal wall.
- Accumulation of fluid in the scrotum, penis, and anterolateral abdominal wall is indicative of a laceration of either the membranous or penile urethra (deep to Scarpa fascia). This can be caused by trauma to the perineal region (saddle injury) or laceration of the urethra during catheterization.

FEMALE REPRODUCTIVE HISTOLOGY

Ovary

The paired **ovaries** have 2 major functions: to produce the female gametes and to produce the steroid hormones which prepare the endometrium for conception and maintain pregnancy should fertilization occur. The ovaries are 3 cm long, 1.5 cm wide, and 1 cm thick. They consist of a **medullary region**, which contains a rich vascular bed with a cellular loose connective tissue, and a **cortical region** where the ovarian follicles reside.

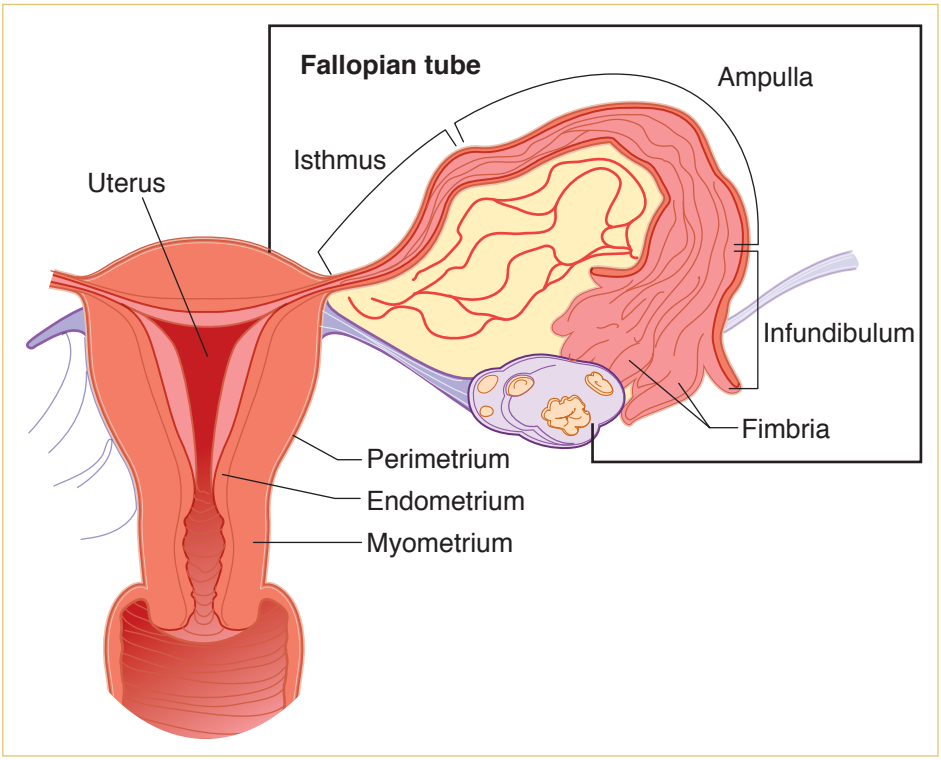

Figure II-3-64. Female Reproductive System

Folliculogenesis and Ovulation

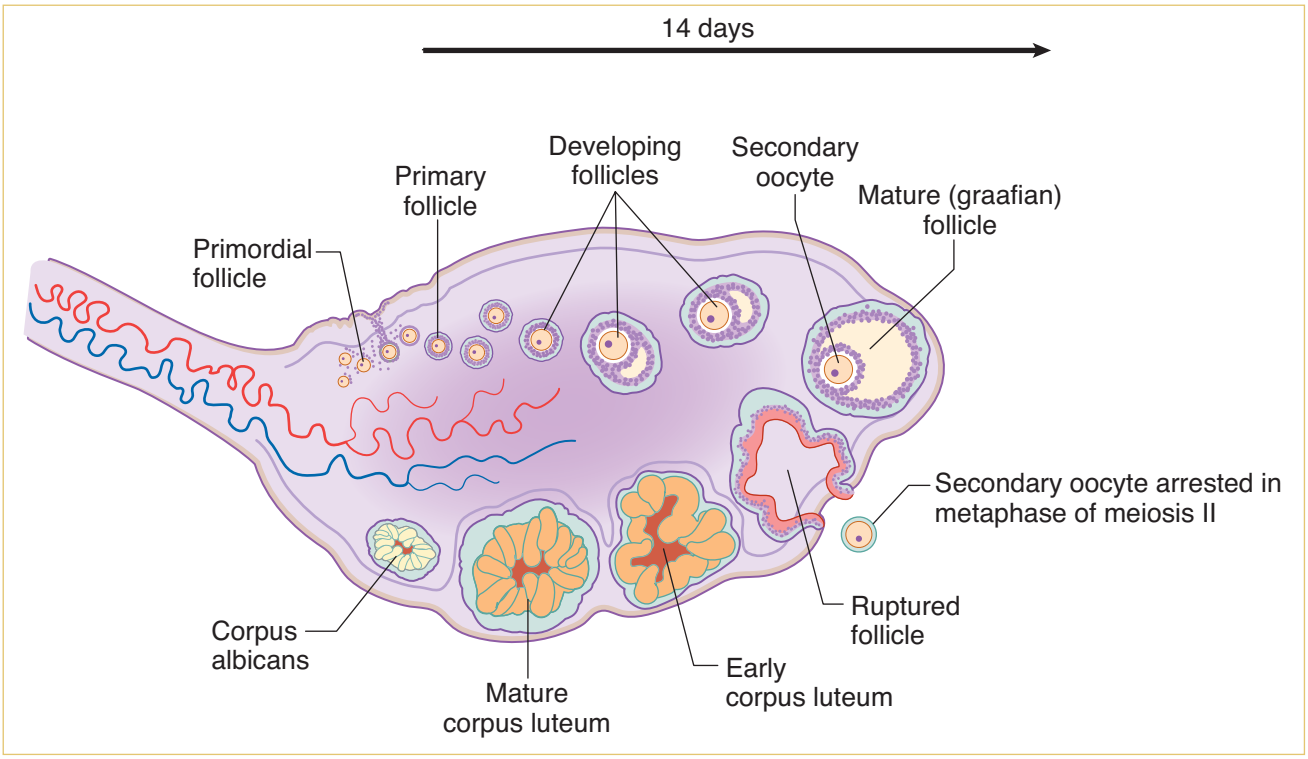

Figure II-3-65. Follicular Development

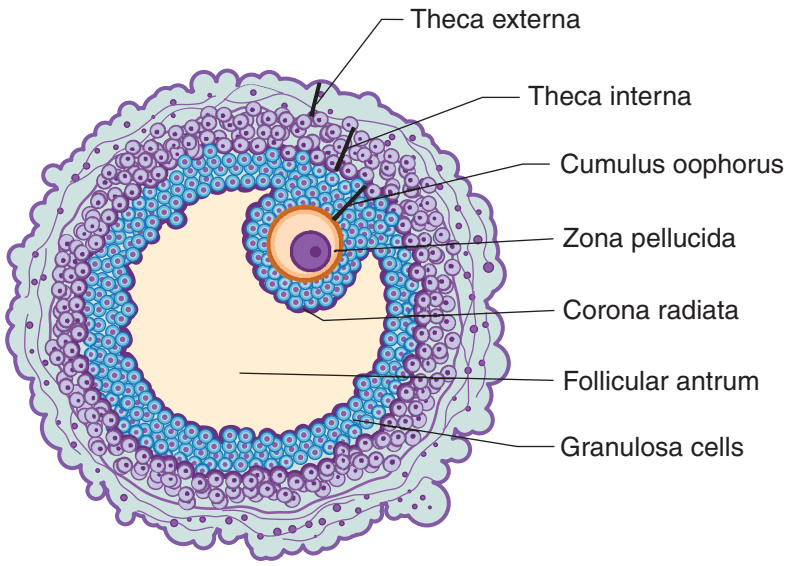

Figure II-3-66. Graafian Follicle

An **ovarian follicle** consists of an oocyte surrounded by one or more layers of follicular cells, the **granulosa cells**. In utero, each ovary initially contains 3 million primordial germ cells. Many undergo atresia as the number of follicles in a normal young adult woman is estimated to be 400,000. A typical woman will ovulate only around 450 ova during her reproductive years. All other follicles (with their oocytes) will fail to mature and will undergo atresia.

Before birth, primordial germ cells differentiate into oogonia that proliferate by mitotic division until they number in the millions. They all enter prophase of the first meiotic division in utero and become arrested (they are now designated as **primordial follicles**). The primordial follicles consist of a primary oocyte surrounded by a single layer of squamous follicular cells, which are joined to one another by desmosomes.

Around the time of sexual maturity, the primordial follicles undergo further growth to become **primary follicles** in which the oocyte is surrounded by 2 or more layers of cuboidal cells. In each menstrual cycle after puberty, several primary follicles enter a phase of rapid growth. The oocyte enlarges and the surrounding follicular cells (now called granulosa cells) proliferate. Gap junctions form between the granulosa cells. A thick layer of glycoprotein called the **zona pellucida** is secreted (probably by both the oocyte and granulosa cells) in the space between the oocyte and granulosa cells. Cellular processes of the granulosa cells and microvilli of the oocyte penetrate the zona pellucida and make contact with one another via gap junctions. Around this time the stroma surrounding the follicle differentiates into a cellular layer called the **theca folliculi**. These cells are separated from the granulosa cells by a thick basement membrane. As development proceeds, 2 zones are apparent in the theca: the **theca interna** (richly vascularized) and the **theca externa** (mostly connective tissue). Cells of the theca interna synthesize androgenic steroids that diffuse into the follicle and are converted to estradiol by the granulosa cells.

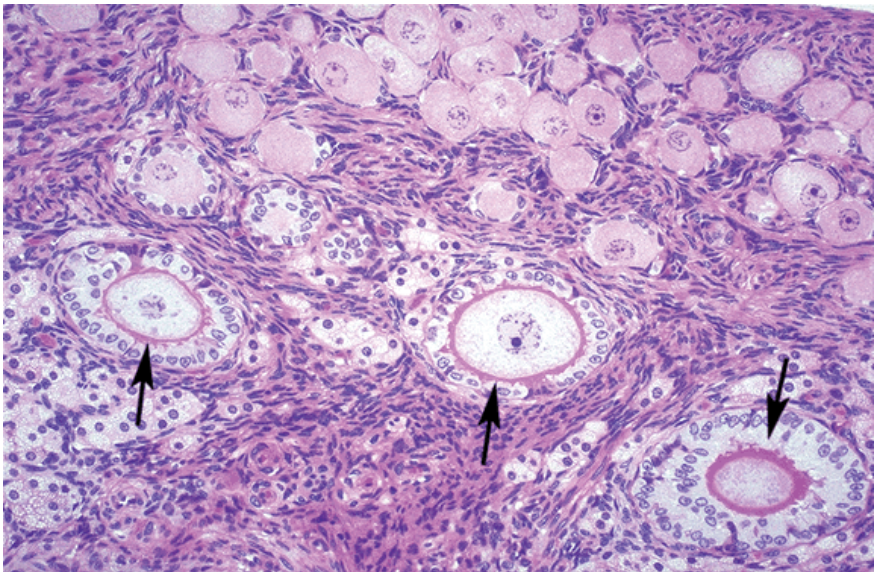

Copyright McGraw-Hill Companies. Used with permission.

Figure II-3-67. Ovary

Small primordial follicles are at top and 3 primary follicles (arrows) with cuboidal granulosa cells and a thin zona pellucida are below.

As the follicle grows, follicular **fluid containing** mainly plasma, glycosaminoglycans and steroids accumulates between the cells. The cavities containing the fluid coalesce and form a larger cavity, the **antrum**. At this point, when the antrum is present, the follicles are called **secondary follicles**. The oocyte is at its full size and it is situated in a thickened area of the granulosa called the **cumulus oophorus**.

The mature follicle (**graafian follicle**) completes the first meiotic division (haploid, 2N amount of DNA) just prior to ovulation. The first polar body contains little cytoplasm and remains within the zona pellucida. The Graafian follicle rapidly commences the second meiotic division where it arrests in metaphase awaiting ovulation and fertilization. The second meiotic division is not completed unless fertilization occurs. The fluid filled antrum has greatly enlarged in the Graafian follicle and the cumulus oophorus diminishes leaving the oocyte surrounded by the corona radiata. After ovulation, the corona radiata remains around the ovum where it persists throughout fertilization and for some time during the passage of the ovum through the oviduct.

Copyright McGraw-Hill Companies. Used with permission.

Figure II-3-68. Secondary follicle with an antrum
Follicle is surrounded by a corona radiata of granulosa cells (arrow) and by a zona pellucida.

Ovulation occurs approximately mid-cycle and is stimulated by a surge of luteinizing hormone secreted by the anterior pituitary. Ovulation consists of rupture of the mature follicle and liberation of the secondary oocyte (ovum) that will be caught by the infundibulum, the dilated distal end of the oviduct. The ovum remains viable for a maximum of 24 hours. Fertilization most commonly occurs in the ampulla of the oviduct. If not fertilized, the ovum undergoes autolysis in the oviduct.

After ovulation, the wall of the follicle collapses and becomes extensively infolded, forming a temporary endocrine gland called the **corpus luteum**. During this process, the blood vessels and stromal cells invade the previously avascular layer of granulosa cells and the granulosa cells and those of the theca interna

hypertrophy and form lutein cells (granulosa lutein cells and theca lutein cells). The granulosa lutein cells now secrete progesterone and estrogen and the theca lutein cells secrete androstenedione and progesterone. Progesterone prevents the development of new follicles, thereby preventing ovulation.

In the absence of pregnancy the corpus luteum lasts only 10–14 days. The lutein cells undergo apoptosis and are phagocytized by invading macrophages. The site of the corpus luteum is subsequently occupied by a scar of dense connective tissue, the **corpus albicans**.

When pregnancy does occur, human chorionic gonadotropin produced by the placenta will stimulate the corpus luteum for about 6 months and then decline. It continues to secrete progesterone until the end of pregnancy. The corpus luteum of pregnancy is large, sometimes reaching 5 cm in diameter.

Oviducts

The **oviduct** (Fallopian tube) is a muscular tube of ~12 cm in length. One end extends laterally into the wall of the uterus and the other end opens into the peritoneal cavity next to the ovary. The oviduct receives the ovum from the ovary, provides an appropriate environment for its fertilization, and transports it to the uterus. The **infundibulum** opens into the peritoneal cavity to receive the ovum. Finger-like projections (fimbriae) extend from the end of the tube and envelop the ovulation site to direct the ovum to the tube.

Adjacent to the infundibulum is the **ampulla**, where fertilization usually takes place. A slender portion of the oviduct called the **isthmus** is next to the ampulla. The **intramural segment** penetrates the wall of the uterus.

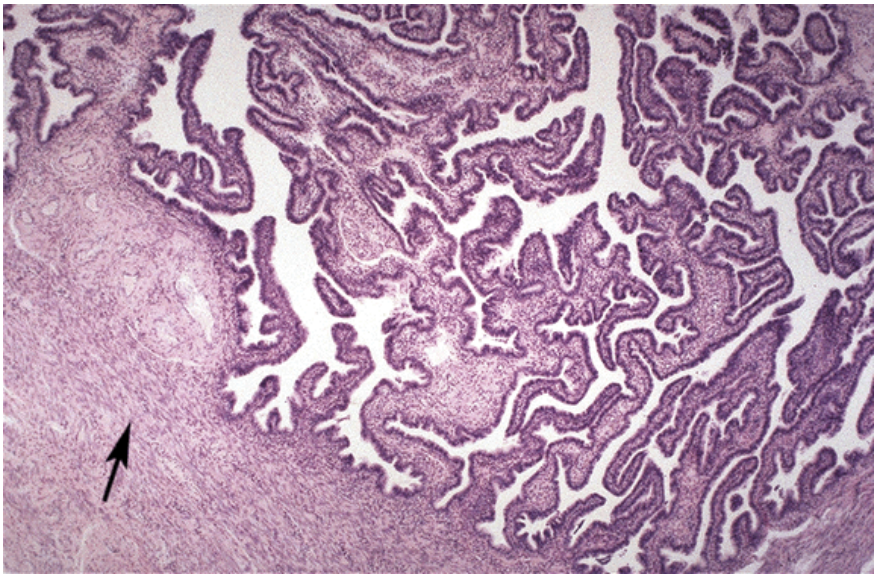

Copyright McGraw-Hill Companies. Used with permission.

Figure II-3-69. Oviduct with simple columnar epithelium and underlying layer of smooth muscle (arrow)

The wall of the oviduct has 3 layers: a mucosa, a muscularis, and a serosa composed of visceral peritoneum. The mucosa has longitudinal folds that are most numerous in the ampulla. The epithelium lining the mucosa is simple columnar. Some cells are ciliated and the others are secretory. The cilia beat toward the uterus, causing movement of the viscous liquid film (derived predominantly from the secretory cells) that covers the surface of the cells. The secretion has nutrient and protective functions for the ovum and promotes activation of spermatozoa. Movement of the liquid together with contraction of the muscle layer transports the ovum or fertilized egg (zygote) to the uterus.

Ciliary action is not essential, so women with **immotile cilia syndrome** (**Kartagener's syndrome**) will have a normal tubal transport of the ovum. The muscularis consists of smooth-muscle fibers in an inner circular layer and an outer longitudinal layer.

An **ectopic pregnancy** occurs when the fertilized ovum implants, most commonly in the wall of the ampulla of the oviduct. Partial development proceeds for a time but the tube is too thin and the embryo cannot survive. The vascular placental tissues that have penetrated the thin wall cause brisk bleeding into the lumen of the tube and peritoneal cavity when the tube bursts.

Uterus

The **uterus** is a pear-shaped organ that consists of a fundus which lies above the entrance sites of the oviducts; a **body** (**corpus**) which lies below the entry point of the oviducts and the internal os; a narrowing of the uterine cavity; and a lower cylindrical structure, the **cervix**, which lies below the internal os. The wall of the uterus is relatively thick and has 3 layers. Depending upon the part of the uterus, there is either an outer serosa (connective tissue and mesothelium) or adventitia (connective tissue). The 2 other layers are the **myometrium** (smooth muscle) and the **endometrium** (the mucosa of the uterus).

The myometrium is composed of bundles of smooth-muscle fibers separated by connective tissue. During pregnancy, the myometrium goes through a period of growth as a result of hyperplasia and hypertrophy. The endometrium consists of epithelium and lamina propria containing simple tubular glands that occasionally branch in their deeper portions. The epithelial cells are a mixture of ciliated and secretory simple columnar cells.

The endometrial layer can be divided into 2 zones. The **functionalis** is the part that is sloughed off at menstruation and replaced during each menstrual cycle, and the **basalis** is the portion retained after menstruation that subsequently proliferates and provides a new epithelium and lamina propria. The bases of the uterine glands, which lie deep in the basalis, are the source of the stem cells that divide and migrate to form the new epithelial lining.

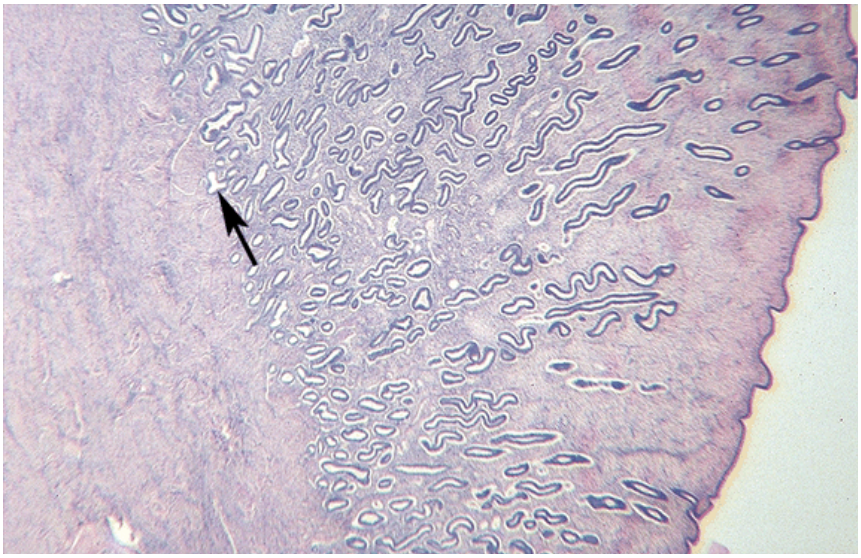

Copyright McGraw-Hill Companies. Used with permission.

Figure II-3-70. Uterine wall with endometrium

Simple tubular glands to the right of arrow and myometrium to the left of arrow

Vagina

The wall of the **vagina** has no glands and consists of 3 layers: the mucosa, a muscular layer, and an adventitia. The mucous found in the vagina comes from the glands of the uterine cervix. The epithelium of the mucosa is stratified squamous. This thick layer of cells contains glycogen granules and may contain some keratohyalin. The muscular layer of the vagina is composed of longitudinal bundles of smooth muscle.

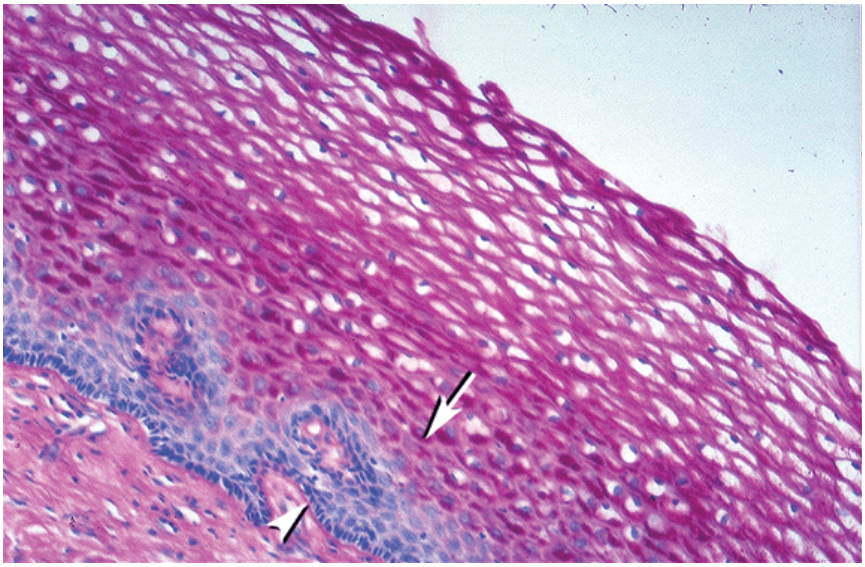

Copyright McGraw-Hill Companies. Used with permission.

Figure II-3-71. Vaginal epithelium with vacuolated stratified squamous epithelial cells that contain glycogen, which is removed during histological processing

Clinical Correlate

Breast cancer affects about 9% of women born in the United States. Most of the cancers (carcinomas) arise from epithelial cells of the lactiferous ducts.

Mammary Glands

The mammary glands enlarge significantly during pregnancy as a result of proliferation of alveoli at the ends of the terminal ducts. Alveoli are spherical collections of epithelial cells that become the active milk-secreting structures during lactation. The milk accumulates in the lumen of the alveoli and in the lactiferous ducts. Lymphocytes and plasma cells are located in the connective tissue surrounding the alveoli. The plasma cell population increases significantly at the end of pregnancy and is responsible for the secretion of IgA that confers passive immunity on the newborn.

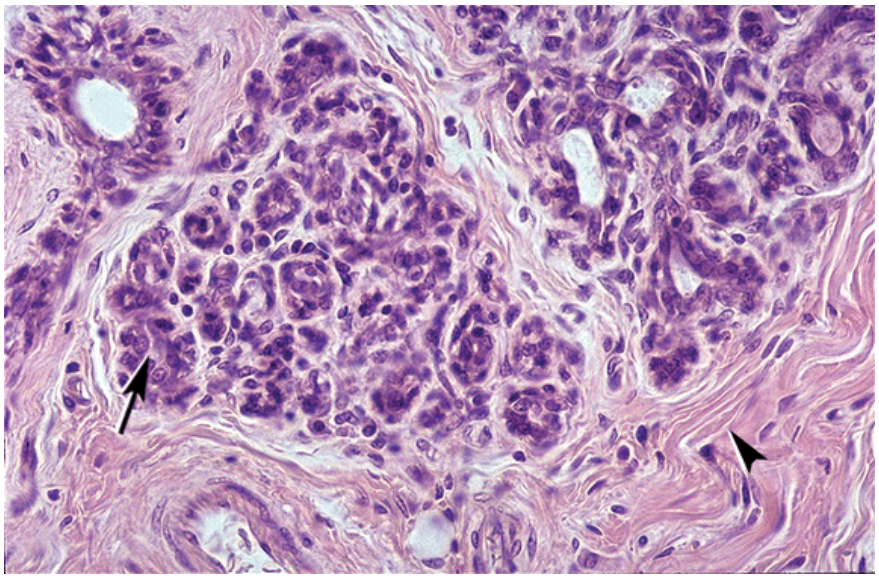

Copyright McGraw-Hill Companies. Used with permission.

Figure II-3-72. Breast tissue containing modified mammary gland tissue (arrow) surrounded by dense regular connective tissue (arrowhead)

RADIOLOGY OF THE ABDOMEN AND PELVIS

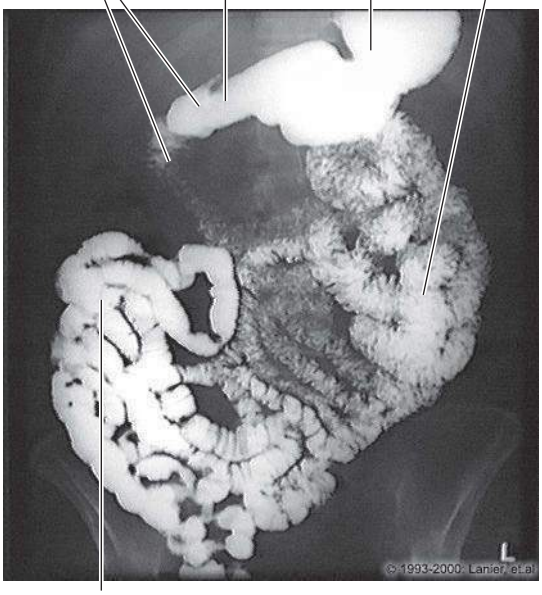

From the IMC, © 2010 DxR Development Group, Inc.
All rights reserved.

Figure II-3-73. Abdomen: Upper GI, Small Bowel

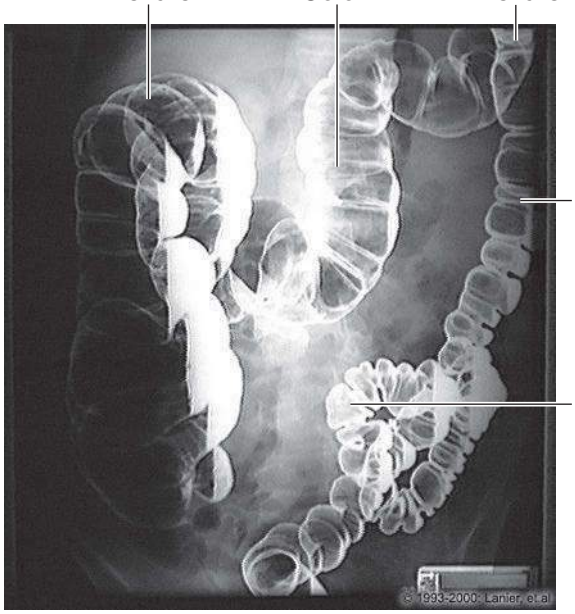

From the IMC, © 2010 DxR Development Group, Inc.
All rights reserved.

Figure II-3-74. Abdomen: Barium Enema

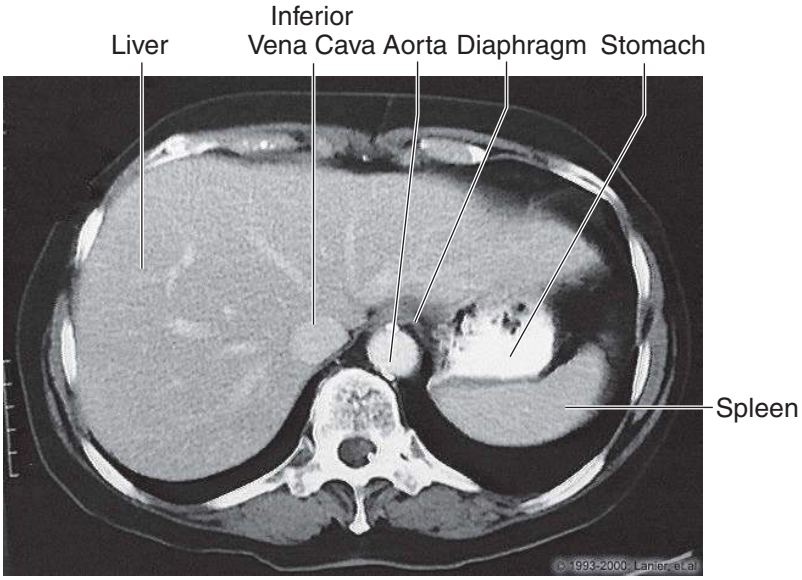

From the IMC, © 2010 DxR Development Group, Inc. All rights reserved.

Figure II-3-75. Abdomen: CT, T11

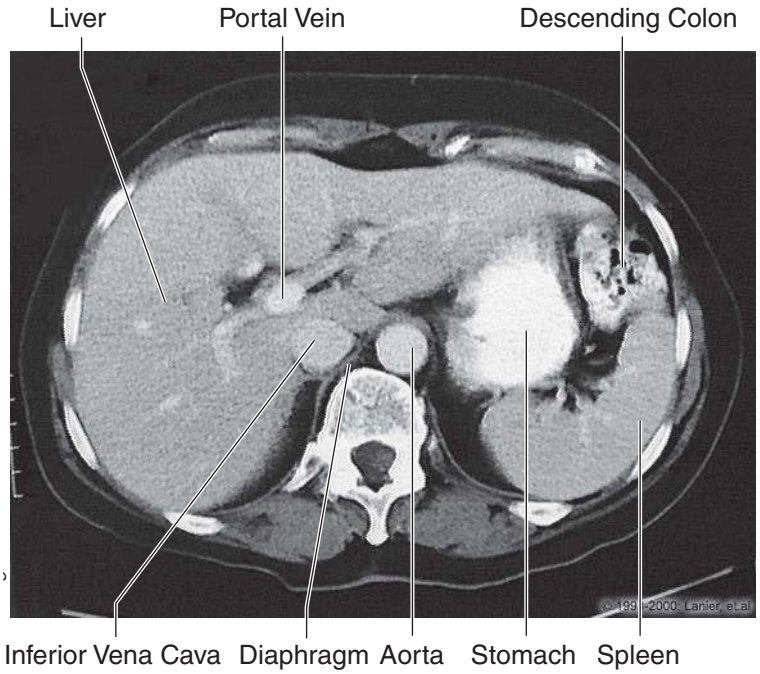

From the IMC, © 2010 DxR Development Group, Inc. All rights reserved.

Figure II-3-76. Abdomen: CT, T12

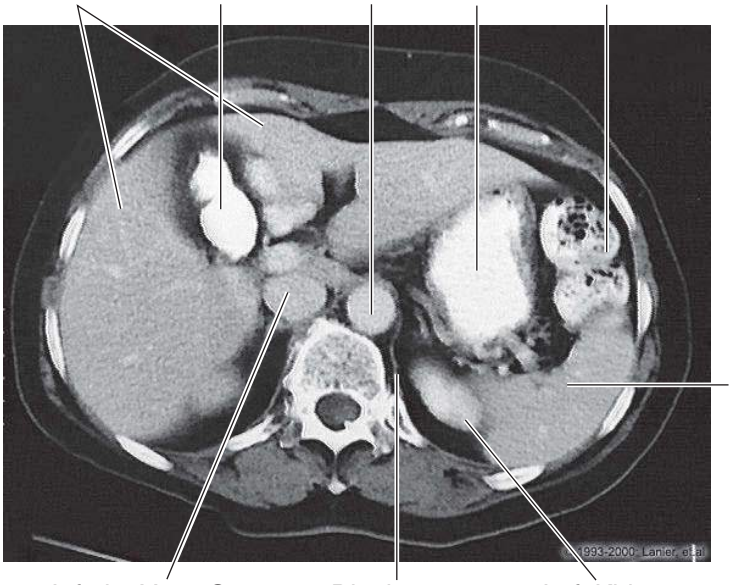

From the IMC, © 2010 DxR Development Group, Inc. All rights reserved.

Figure II-3-77. Abdomen: CT, T12

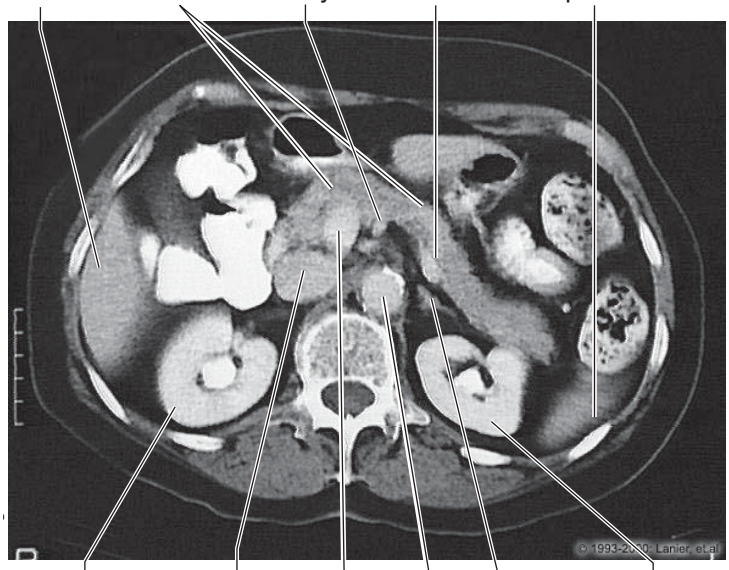

From the IMC, © 2010 DxR Development Group, Inc. All rights reserved.

Figure II-3-78. Abdomen: CT, L1

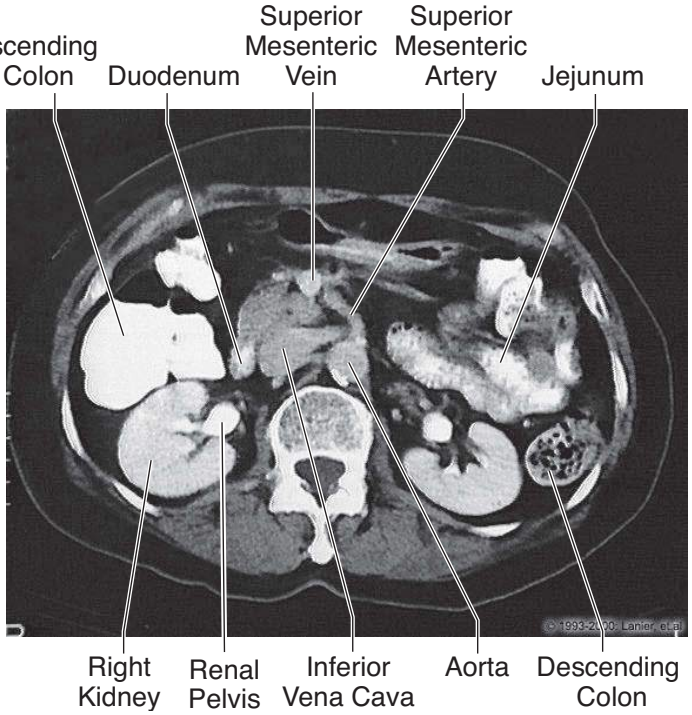

From the IMC, © 2010 DxR Development Group, Inc. All rights reserved.

Figure II-3-79. Abdomen: CT, L2

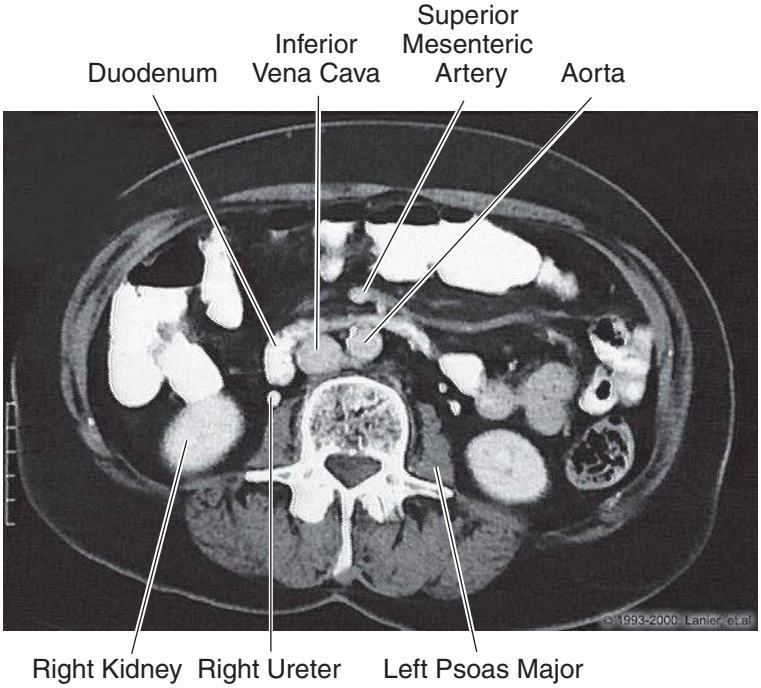

From the IMC, © 2010 DxR Development Group, Inc. All rights reserved.

Figure II-3-80. Abdomen: CT, L3

From the IMC, © 2010 DxR Development Group, Inc. All rights reserved.

Figure II-3-81. Abdomen: CT, L4

Upper Limb 4

Learning Objectives

- ❑ Solve problems concerning brachial plexus
- ❑ Answer questions about muscle innervation
- ❑ Solve problems concerning sensory innervation
- ❑ Solve problems concerning nerve injuries
- ❑ Solve problems concerning upper and lower brachial plexus lesions
- ❑ Use knowledge of lesions of branches of the brachial plexus
- ❑ Use knowledge of arterial supply and major anastomoses
- ❑ Solve problems concerning carpal tunnel
- ❑ Interpret scenarios on rotator cuff
- ❑ Use knowledge of radiology

BRACHIAL PLEXUS

The **brachial plexus** provides the motor and sensory innervation to the upper limb and is formed by the ventral rami of C5 through T1 spinal nerves. Five major nerves arise from the brachial plexus:

- The **musculocutaneous, median,** and **ulnar** nerves contain **anterior division fibers** and innervate muscles in the anterior arm, anterior forearm, and palmar compartments that function mainly as flexors.
- The **axillary** and **radial** nerves contain **posterior division fibers** and innervate muscles in the posterior arm and posterior forearm compartments that function mainly as extensors.

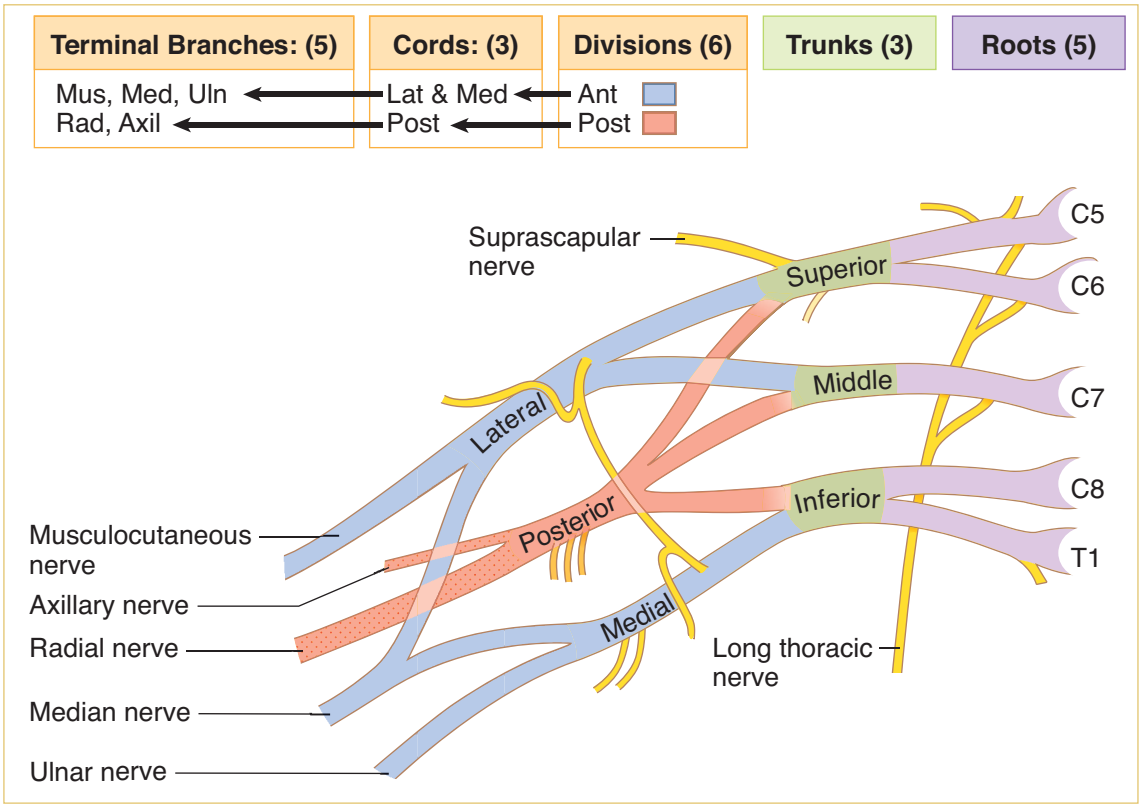

Figure II-4-1. Brachial Plexus

MUSCLE INNERVATION

Terminal Nerves of Upper Limbs

The motor innervation by the 5 terminal nerves of the arm muscles is summarized below.

Table II-4-1. Major Motor Innervations by the 5 Terminal Nerves

Terminal Nerve	Muscles Innervated	Primary Actions
Musculocutaneous nerve C5–6	All the muscles of the **anterior compartment** of the arm	Flex elbow Supination (biceps brachii)
Median nerve C5–T1	**A. Forearm** • **Anterior compartment** except 1.5 muscles by ulnar nerve (flexor carpi ulnaris and the ulnar half of the flexor digitorum profundus)	Flex wrist and all digits Pronation
	B. Hand • **Thenar compartment** • **Central compartment** Lumbricals: Digits 2 and 3	Opposition of thumb Flex metacarpophalangeal (MP) and extend interphalangeal (PIP and DIP) joints of digits 2 and 3
Ulnar nerve C8–T1	**A. Forearm** **Anterior Compartment:** 1 [1/2] muscles not innervated by the median nerve	Flex wrist (weak) and digits 4 and 5
	B. Hand • Hypothenar compartment • **Central compartment** – Interossei muscles: Palmar and Dorsal • Lumbricals: Digits 4 & 5 • Adductor pollicis	Dorsal – Abduct digits 2-5 (DAB) Palmar – Adduct digits 2-5 (PAD) Assist Lumbricals in MP flexion and IP extension digits 2–5 Flex MP and extend PIP & DIP joints of digits 4 and 5 Adduct the thumb
Axillary nerve C5–6	Deltoid Teres minor	Abduct shoulder—15°–110° Lateral rotation of shoulder
Radial nerve C5–T1	**Posterior compartment** muscles of the arm and forearm	Extend MP, wrist, and elbow Supination (supinator muscle)

Collateral Nerves

In addition to the 5 terminal nerves, there are several collateral nerves that arise from the brachial plexus proximal to the terminal nerves (i.e., from the rami, trunks, or cords). These nerves innervate proximal limb muscles (shoulder girdle muscles). Table II-4-2 summarizes the collateral nerves.

Table II-4-2. The Collateral Nerves of the Brachial Plexus

Collateral Nerve	Muscles or Skin Innervated
Dorsal scapular nerve	Rhomboids
Long thoracic nerve	Serratus anterior—protracts and rotates scapula superiorly
Suprascapular nerve C5–6	Supraspinatus—abduct shoulder 0–15° Infraspinatus—laterally rotate shoulder
Lateral pectoral nerve	Pectoralis major
Medial pectoral nerve	Pectoralis major and minor
Upper subscapular nerve	Subscapularis
Middle subscapular (thoracodorsal) nerve	Latissimus dorsi
Lower subscapular nerve	Subscapularis and teres major
Medial brachial cutaneous nerve	Skin of medial arm
Medial antebrachial cutaneous nerve	Skin of medial forearm

Segmental Innervation to Muscles of Upper Limbs

The **segmental innervation** to the muscles of the upper limbs has a **proximal–distal gradient**, i.e., the more proximal muscles are innervated by the higher segments (C5 and C6) and the more distal muscles are innervated by the lower segments (C8 and T1). Therefore, the intrinsic shoulder muscles are innervated by C5 and C6, the intrinsic hand muscles are innervated by C8 and T1, the distal arm and proximal forearm muscles are innervated by C6 and C7, and the more distal forearm muscles are innervated by C7 and C8.

SENSORY INNERVATION

The skin of the palm is supplied by the median and ulnar nerves. The **median** supplies the lateral 3½ digits and the adjacent area of the lateral palm and the thenar eminence. The **ulnar** supplies the medial 1½ digits and skin of the hypothenar eminence. The **radial** nerve supplies skin of the dorsum of the hand in the area of the first dorsal web space, including the skin over the anatomic snuffbox.

Palm sensation is not affected by carpal tunnel syndrome; the superficial palmar cutaneous branch of median nerve passes superficial to the carpal tunnel.

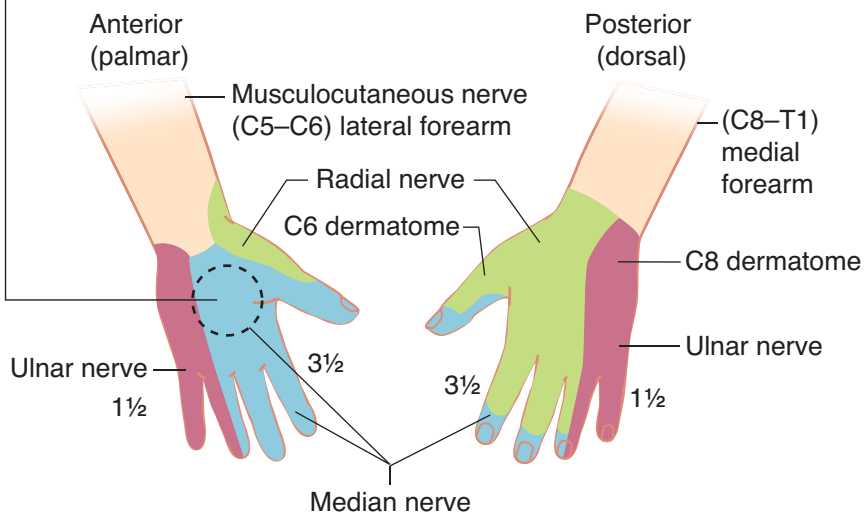

Figure II-4-2. Sensory Innervation of the Hand and Forearm

NERVE INJURIES

Follow clues in the exam questions as to the location of the injury. An injury will manifest in symptoms distal to the site of injury.

Muscle–Nerve Lesions

Without specifically naming all the muscles, assign a function to the various compartments of the limbs.

Example: posterior arm = extension of the forearm and shoulder

List the nerve(s) that innervate those muscles or that area.

Example: posterior arm = radial nerve

You have an area of the limb, a function of the muscles within that area, and a nerve responsible for that function.

Now you can damage a nerve and note what function(s) is lost or weakened.

UPPER AND LOWER BRACHIAL PLEXUS LESIONS

Upper (C5 and C6) Brachial Plexus Lesion: Erb-Duchenne Palsy (Waiter's Tip Syndrome)

- Usually occurs when the head and shoulder are forcibly separated (e.g., accident or birth injury or herniation of disk)

- Trauma will damage **C5** and **C6** spinal nerves (roots) of the upper trunk.
- Primarily affects the **axillary, suprascapular, and musculocutaneous nerves** with the loss of intrinsic muscles of the shoulder and muscles of the anterior arm.
- The arm is medially rotated and adducted at the shoulder: loss of **axillary** and **suprascapular** nerves. The unopposed latissimus dorsi and pectoralis major muscles pull the limb into adduction and medial rotation at the shoulder.
- The forearm is extended and pronated: loss of **musculocutaneous** nerve.
- **Sign is "waiter's tip."**
- Sensory loss on lateral forearm to base of thumb: loss of musculocutaneous nerve

Lower (C8 and T1) Brachial Plexus Lesion: Klumpke's Paralysis

- Usually occurs when the upper limb is forcefully abducted above the head (e.g., grabbing an object when falling, thoracic outlet syndrome or birth injury)
- Trauma will injure the **C8 and T1** spinal nerve roots of inferior trunk.
- Primarily affects the ulnar nerve and the intrinsic muscles of the hand with a weakness of the median innervated muscles of the hand
- Sign is combination of "**claw hand**" and "ape hand" (median nerve).
- May include a Horner syndrome.
- Sensory loss on medial forearm and medial 1½ digits

Table II-4-3. Lesions of Roots of Brachial Plexus

Lesioned Root	C5	C6	C8	T1
Dermatome paresthesia	Lateral border of upper arm	Lateral forearm to thumb	Medial forearm to little finger	Medial arm to elbow
Muscles affected	Deltoid Rotator cuff Serratus anterior Biceps Brachioradialis	Biceps Brachioradialis Brachialis Supinator	Finger flexors Wrist flexors Hand muscles	Hand muscles
Reflex test	—	Biceps tendon	—	—
Causes of lesions	Upper trunk compression	Upper trunk compression	Lower trunk compression	Lower trunk compression

LESIONS OF BRANCHES OF THE BRACHIAL PLEXUS

- Sensory deficits precede motor weakness
- Proximal lesions: more signs

Radial Nerve

Axilla: (Saturday night palsy or using crutches)

- Loss of extension at the elbow, wrist and MP joints
- Weakened supination
- Sensory loss on posterior arm, forearm, and dorsum of thumb
- Distal sign is **"wrist drop."**

Mid-shaft of humerus at radial groove or lateral elbow (lateral epicondyle or radial head dislocation)

- Loss of forearm extensors of the wrist and MP joints
- Weakened supination
- Sensory loss on the posterior forearm and dorsum of thumb
- Distal sign is **"wrist drop."**

Note: Lesions of radial nerve distal to axilla, elbow extension are spared.

Wrist: laceration

- No **motor loss**
- Sensory loss only on dorsal aspect of thumb (first dorsal web space)

Median Nerve

Elbow: (Supracondylar fracture of humerus)

- Weakened wrist flexion (with ulnar deviation)
- Loss of pronation
- Loss of digital flexion of lateral 3 digits resulting in the inability to make a complete fist; sign is "**hand of benediction**"
- Loss of thumb opposition (opponens pollicis muscle); sign is **ape (simian) hand**
- Loss of first 2 lumbricals
- Thenar atrophy (flattening of thenar eminence)
- Sensory loss on palmar surface of the lateral hand and the palmar surfaces of the lateral 3½ digits

Note: A lesion of median nerve at elbow results in the "hand of benediction" and "ape hand."

Wrist: carpal tunnel or laceration

- Loss of thumb opposition (opponens pollicis muscle); sign is **ape or simian hand**
- Loss of first 2 lumbricals
- Thenar atrophy (flattening of thenar eminence)
- Sensory loss on the palmar surfaces of lateral 3½ digits. Note sensory loss on lateral palm may be spared.

Note: Lesions of median nerve at the wrist present without benediction hand and with normal wrist flexion, digital flexion, and pronation.

Ulnar Nerve

Elbow (medial epicondyle), wrist (lacerations), or fracture of hook of hamate

- Loss of hypothenar muscles, third and fourth lumbricals, all interossei and adductor pollicis
- With elbow lesion there is minimal weakening of wrist flexion with radial deviation
- Loss of **abduction** and **adduction of digits 2–5** (interossei muscles)
- Weakened interphalangeal (IP) extension of digits 2–5 (more pronounced in digits 4 and 5)
- Loss of thumb adduction
- Atrophy of the hypothenar eminence
- Sign is **"claw hand."** Note that clawing is greater with a wrist lesion.
- Sensory loss on medial 1½ digits

Axillary Nerve

Fracture of the surgical neck of the humerus or inferior dislocation of the shoulder

- Loss of abduction of the arm to the horizon
- Sensory lost over the deltoid muscle

Musculocutaneous Nerve

- Loss of elbow flexion and weakness in supination
- Loss of sensation on lateral aspect of the forearm

Long Thoracic Nerve

- Often damaged during a radical mastectomy or a stab wound to the lateral chest (nerve lies on superficial surface of serratus anterior muscle).

- Loss of abduction of the arm above the horizon to above the head
- Sign of **"winged scapula"**; patient unable to hold the scapula against the posterior thoracic wall

Suprascapular Nerve

- Loss of shoulder abduction between 0 and 15 degrees (supraspinatus muscle)
- Weakness of lateral rotation of shoulder (infraspinatus muscle)

Table II-4-4. Effects of Lesions to Branches of the Brachial Plexus

Lesioned Nerve	Axillary (C5, C6)	Musculo-cutaneous (C5, C6, C7)	Radial (C5, C6, C7, C8)	Median (C6, C7, C8, T1)	Ulnar (C8, T1)
Altered sensation	Lateral arm	Lateral fore-arm	Dorsum of hand over first dorsal interosseous and anatomic snuffbox	Lateral 3½ digits; lateral palm	Medial 1½ digits; medial palm
Motor weakness	Abduction at shoulder	Flexion of forearm Supination	Wrist extension Metacarpo-pha-langeal extension Supination	Wrist flexion Finger flexion Pronation Thumb opposition	Wrist flexion Finger spreading Thumb adduction Finger extension
Common sign of lesion	—	—	Wrist drop	Ape hand Hand of benediction Ulnar deviation at wrist	Claw hand Radial deviation at wrist
Causes of lesions	Surgical neck fracture of humerus Dislocated humerus	Rarely le-sioned	Saturday night palsy Midshaft fracture of humerus Subluxation of radius Dislocated hu-merus	Carpal tunnel compression Supracondylar fracture of humerus Pronator teres syndrome	Fracture of medial epicondyle of humerus Fracture of hook of hamate Fracture of clavicle

ARTERIAL SUPPLY AND MAJOR ANASTOMOSES

Arterial Supply to the Upper Limb

Subclavian artery

Branch of brachiocephalic trunk on the right and aortic arch on the left.

Axillary artery

- From the first rib to the posterior edge of the teres major muscle
- Three major branches:
  - Lateral thoracic artery—supplies mammary gland; runs with long thoracic nerve
  - Subscapular artery—collateral to shoulder with suprascapular branch of subclavian artery
  - Posterior humeral circumflex artery—at surgical neck with axillary nerve

Brachial artery

Profunda brachii artery with radial nerve in radial groove—at midshaft of humerus

Radial artery

Deep palmar arch

Ulnar artery

- Common interosseus artery
- Superficial palmar arch

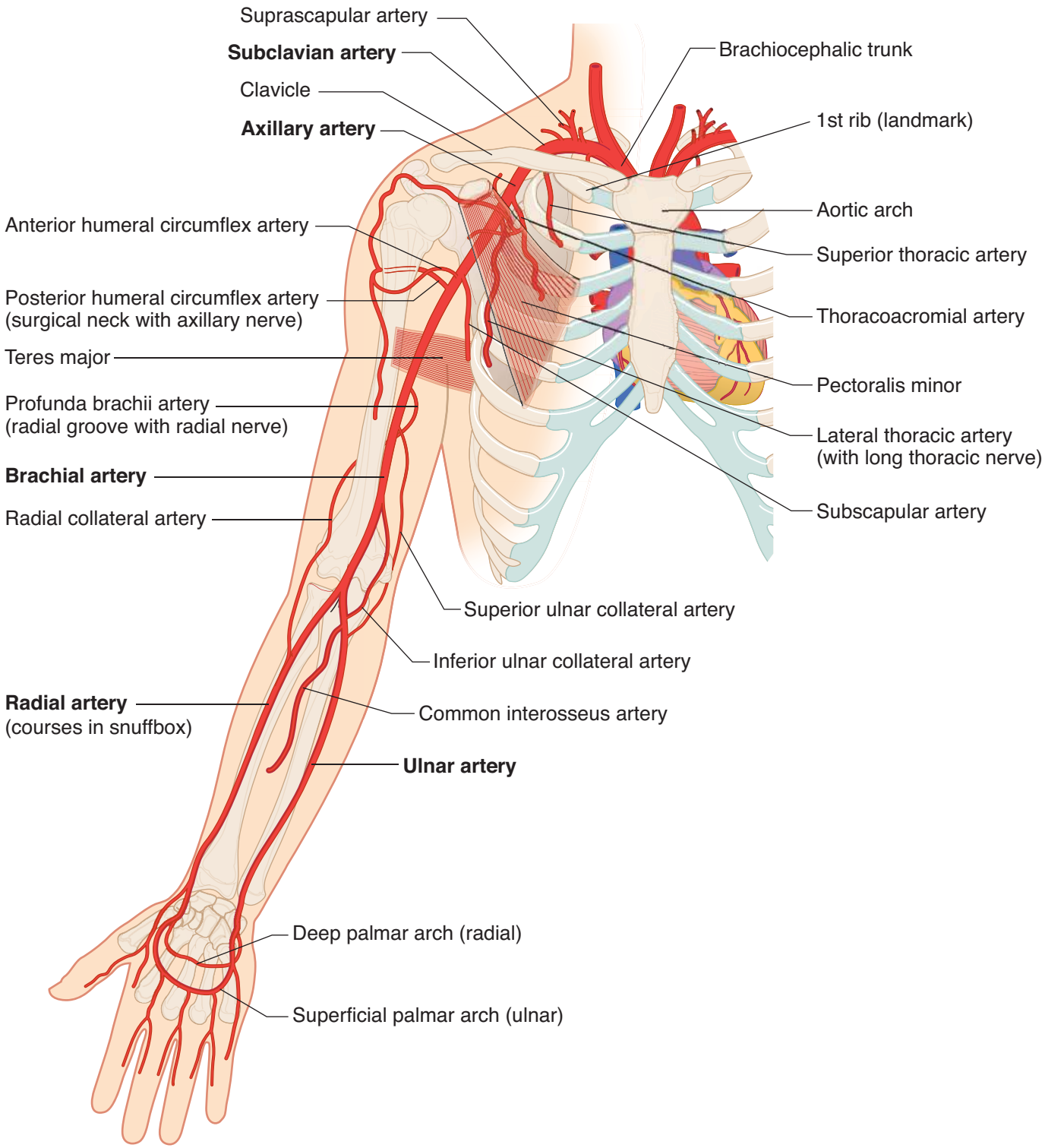

Figure II-4-3. Arterial Supply to the Upper Limb

Collateral Circulation

Shoulder

Subscapular branch of axillary and suprascapular branch of subclavian arteries

Hand

Superficial and deep palmar arches

CARPAL TUNNEL

The carpal tunnel is the fibro-osseous tunnel located on the ventral aspect of the wrist. The tunnel is bounded **anteriorly** by the **flexor retinaculum** and **posteriorly** by the proximal row of **carpal bones (lunate)**.

- The carpal tunnel transmits 9 tendons and the radial and ulnar bursae (4 tendons of the **flexor digitorum superficialis**, 4 tendons of the **flexor digitorum profundus**, and the tendon of the **flexor pollicis longus**) and the **median nerve**.
- There are **no** blood vessels or any branches of the radial or ulnar nerves in the carpal tunnel.

Carpal Tunnel Syndrome

Entrapment of the median nerve and other structures in the carpal tunnel due to any condition that reduces the space results in **carpal tunnel syndrome**. The median nerve is the only nerve affected and the patient will present with atrophy of the thenar compartment muscles and weakness of the thenar muscles (opposition of the thumb—**ape hand**).

There is also **sensory loss** and numbness on the palmar surfaces of the **lateral 3½ digits**. The skin on the lateral side of the palm (thenar eminence) is spared because the **palmar cutaneous branch of the median nerve** which supplies the lateral palm, enters the hand **superficial** to the flexor retinaculum and does not course through the carpal tunnel.

Clinical Correlate

Carpal tunnel syndrome compresses the median nerve.

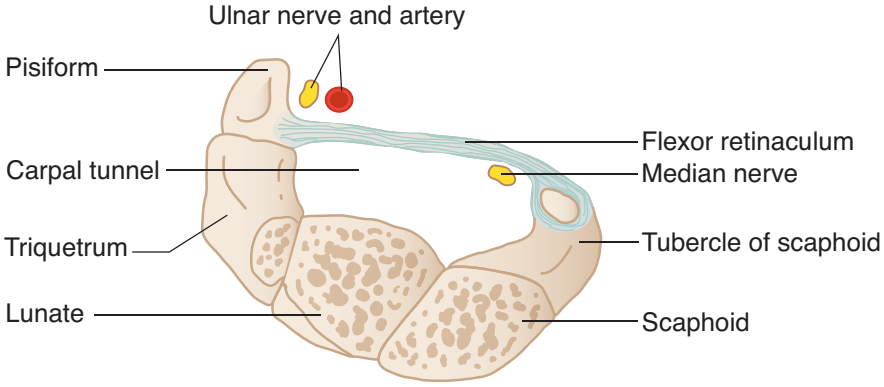

Figure II-4-4. Carpal Tunnel at Proximal Row of Carpal Bones

ROTATOR CUFF

The tendons of rotator cuff muscles strengthen the glenohumeral joint and include the **supraspinatus, infraspinatus, teres minor,** and **subscapularis** (**SITS**) muscles. The tendons of the muscles of the rotator cuff may become torn or inflamed.

The tendon of the **supraspinatus** is most commonly affected. Patients with rotator cuff tears experience pain anteriorly and superiorly to the glenohumeral joint during abduction

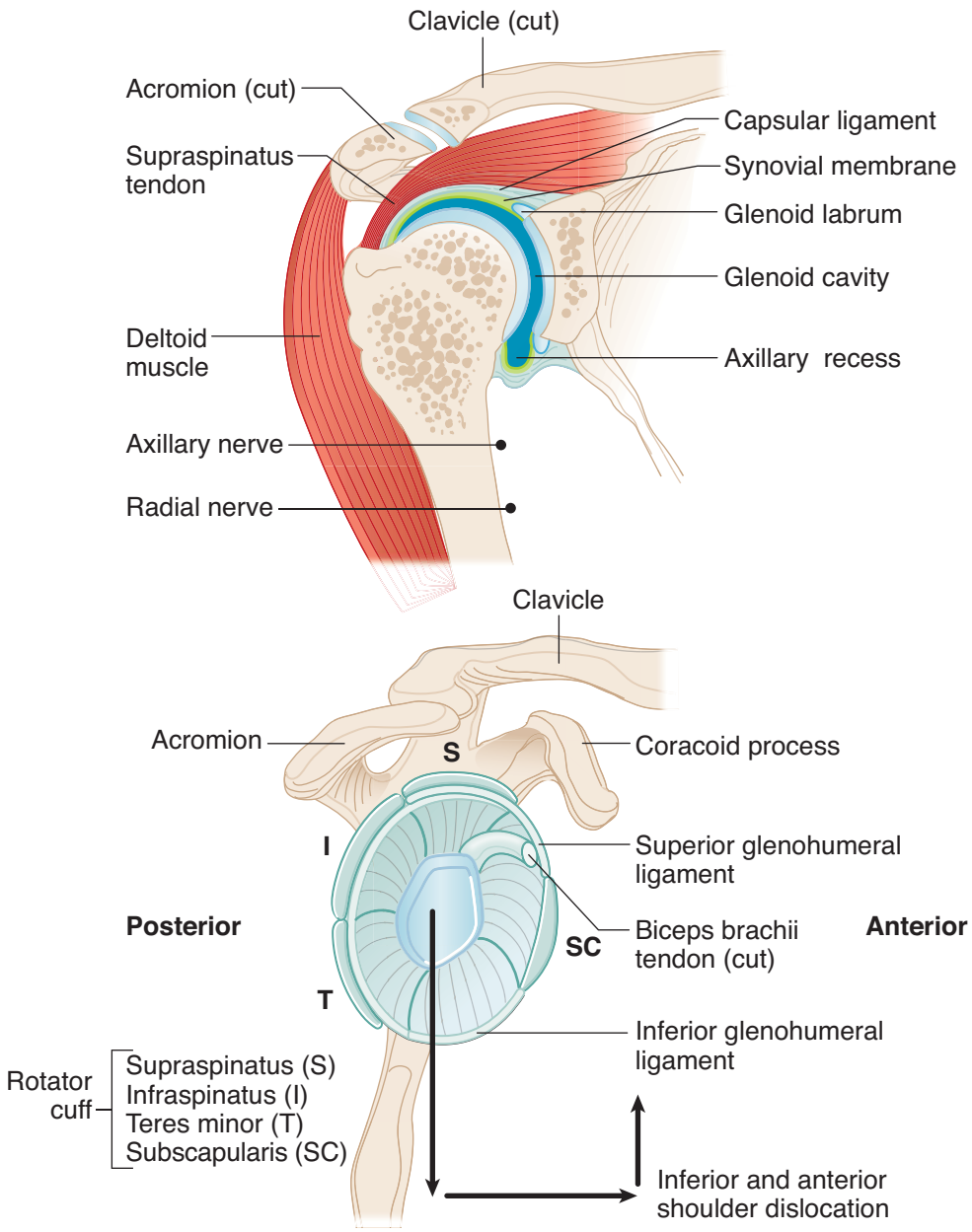

Figure II-4-5. Rotator Cuff

Clinical Correlate

Humeral Head Dislocation

Dislocation of the humeral head from the glenohumeral joint typically occurs through the inferior portion of the joint capsule where the capsule is the slackest and is not reinforced by a rotator cuff tendon (Figure II-4-5). After inferior dislocation, the humeral head is pulled superiorly and comes to lie anterior to the glenohumeral joint.

Dislocation may injure the **axillary** or **radial** nerve.

Clinical Correlate

A rupture or tear of the rotator cuff follows chronic use of the shoulder or a fall with an abducted upper limb. The **supraspinatus muscle** is the most frequently damaged muscle of the rotator cuff.

Clinical Correlate

Humeral Surgical Neck Fracture

The axillary nerve accompanies the posterior humeral circumflex artery as it passes around the surgical neck of the humerus. A fracture in this area could lacerate both the artery and nerve.

Mid-Shaft (Radial Groove) Humeral Fracture

The radial nerve accompanies the profunda brachii artery. Both could be damaged as a result of a mid-shaft humeral fracture.

RADIOLOGY

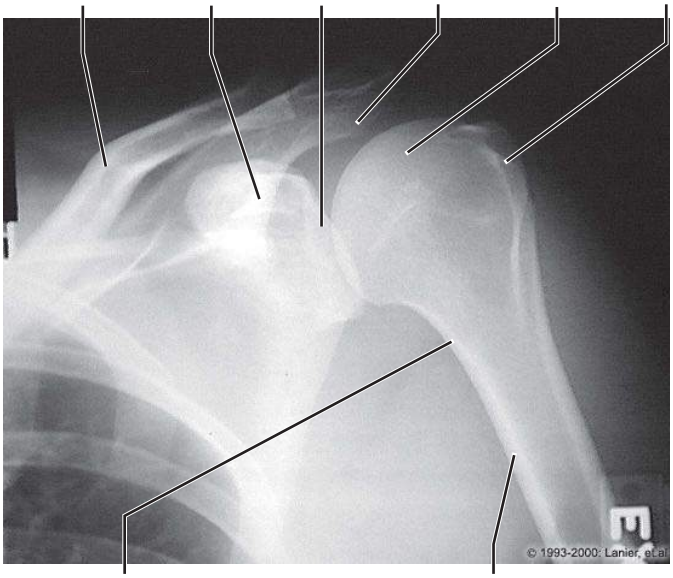

From the IMC, © 2010 DxR Development Group, Inc. All rights reserved.

Figure II-4-6. Upper Extremities: Anteroposterior View of Shoulder (External Rotation)

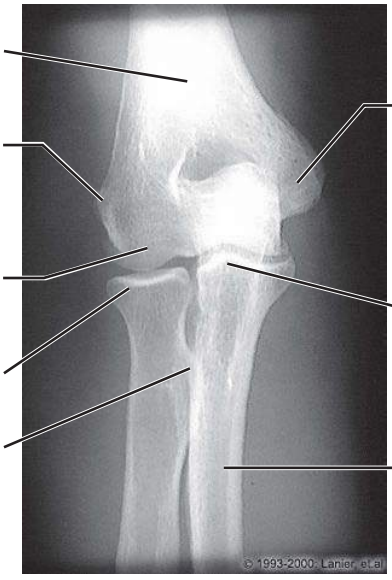

From the IMC, © 2010 DxR Development Group, Inc. All rights reserved.

Figure II-4-7. Upper Extremities: Anteroposterior View of Elbow

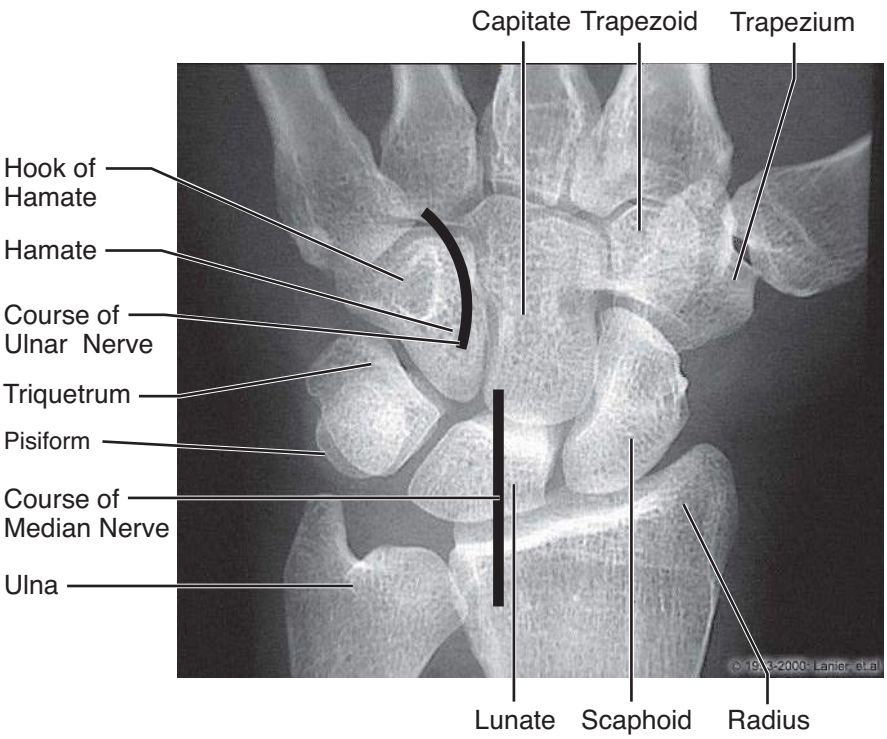

From the IMC, © 2010 DxR Development Group, Inc. All rights reserved.

Figure II-4-8. Upper Extremities: Posteroanterior View of Wrist

Clinical Correlate

The **scaphoid** is the most frequently fractured of the carpal bones. This fracture may separate the proximal head of the scaphoid from its blood supply (which enters the bone at the distal head) and may result in **avascular necrosis** of the proximal head.

The **lunate** is the most commonly dislocated carpal bone (it dislocates anteriorly into the carpal tunnel and may compress the median nerve).

Clinical Correlate

- **Carpal tunnel syndrome** results from compression of the median nerve within the tunnel.
- A fall on the outstretched hand may **fracture the hook of the hamate**, which may damage the ulnar nerve as it passes into the hand.

Lower Limb 5

Learning Objectives

- ❑ Explain information related to lumbosacral plexus
- ❑ Solve problems concerning nerve injuries and abnormalities of gait
- ❑ Demonstrate understanding of arterial supply and major anastomoses
- ❑ Use knowledge of femoral triangle
- ❑ Demonstrate understanding of hip
- ❑ Explain information related to knee joint
- ❑ Use knowledge of ankle joint
- ❑ Solve problems concerning radiology

LUMBOSACRAL PLEXUS

The **lumbosacral plexus** provides the motor and sensory innervation to the lower limb and is formed by ventral rami of the L2 through S3 spinal nerves.

The major nerves of the plexus are:

- **Femoral nerve**: posterior divisions of L2 through L4
- **Obturator nerve**: anterior divisions of L2 through L4
- **Tibial nerve**: anterior divisions of L4 through S3
- **Common fibular nerve**: posterior divisions of L4 through S2
- **Superior gluteal nerve**: posterior divisions of L4 through S1
- **Inferior gluteal nerve**: posterior divisions of L5 through S2

The tibial nerve and common fibular nerve travel together through the gluteal region and thigh in a common connective tissue sheath; together, they are called the **sciatic nerve**.

The common fibular nerve divides in the proximal leg into the **superficial and deep fibular nerve**.

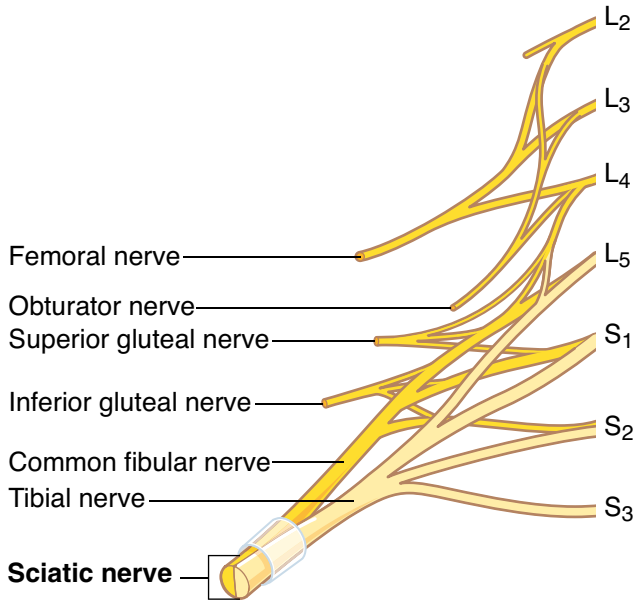

Figure II-5-1. Lumbosacral Plexus

Terminal Nerves of Lumbosacral Plexus

The terminal nerves of the lumbosacral plexus are described below.

Table II-5-1. Terminal Nerves of Lumbosacral Plexus

Terminal Nerve	Origin	Muscles Innervated	Primary Actions
Femoral nerve	L2–L4 posterior divisions	Anterior compartment of thigh (quadriceps femoris, sartorius, pectineus)	Extend knee Flex hip
Obturator nerve	L2–L4 anterior divisions	Medial compartment of thigh (gracilis, adductor longus, adductor brevis, anterior portion of adductor magnus)	Adduct thigh Medially rotate thigh
Tibial nerve	L4–S3 anterior divisions	Posterior compartment of thigh (semimembranosus, semitendinosus, long head of biceps femoris, posterior portion of adductor magnus) Posterior compartment of leg (gastrocnemius, soleus, flexor digitorum longus, flexor hallucis longus, tibialis posterior) Plantar muscles of foot	Flex knee Extend thigh Plantar flex foot (S1–2) Flex digits Inversion
Common fibular nerve	L4–S2 posterior divisions	Short head of biceps femoris	Flex knee
Superficial fibular nerve		Lateral compartment of leg (fibularis longus, fibularis brevis)	Eversion
Deep fibular nerve		Anterior compartment of leg (tibialis anterior, extensor hallucis, extensor digitorum, fibularis tertius)	Dorsiflex foot (L4–5) Extend digits Inversion

Collateral Nerves of Lumbosacral Plexus

The collateral nerves of the lumbosacral plexus (to the lower limb) are summarized below.

Table II-5-2. Collateral Nerves of Lumbosacral Plexus

Collateral Nerve	Origin	Muscles or Skin Innervated	Primary Actions
Superior gluteal nerve	L4–S1 posterior divisions	Gluteus medius, gluteus minimus, tensor fasciae latae	Stabilize pelvis Abduct hip
Inferior gluteal nerve	L5–S2 posterior divisions	Gluteus maximus	Extension of hip Lateral rotation of thigh
Nerve to superior gemellus and obturator internus	L5–S2 posterior divisions	Superior gemellus, obturator internus	Lateral rotation of thigh
Nerve to inferior gemellus and quadratus femoris	L4–S1 posterior divisions	Inferior gemellus, quadratus femoris	Lateral rotation of thigh
Lateral femoral cutaneous nerve	L2–L3 posterior divisions	Skin of anterolateral thigh	—
Posterior femoral cutaneous nerve	S1–S2 posterior divisions and S2–S3 anterior divisions	Skin of posterior thigh	—

Segmental Innervation to Muscles of Lower Limb

The **segmental innervation** to the muscles of the lower limb has a **proximal–distal gradient,** i.e., the more proximal muscles are innervated by the higher segments and the more distal muscles are innervated by the lower segments.

- Muscles that cross the **anterior side of the hip** are innervated by **L2 and L3**
- Muscles that cross the **anterior side of the knee** are innervated by **L3 and L4**
- Muscles that cross the **anterior side of the ankle** are innervated by **L4 and L5 (dorsiflexion)**
- Muscles that cross the **posterior side of the hip** are innervated by **L4 and L5**
- Muscles that cross the **posterior side of the knee** are innervated by **L5 and S1**
- Muscles that cross the **posterior side of the ankle** are innervated by **S1 and S2 (plantar flexion)**

NERVE INJURIES AND ABNORMALITIES OF GAIT

Superior Gluteal Nerve

- Weakness in abduction of the hip
- Impairment of gait; patient cannot keep pelvis level when standing on one leg.
- Sign is "Trendelenburg gait."

Inferior Gluteal Nerve

- Weakened hip extension
- Difficulty rising from a sitting position or climbing stairs

Femoral Nerve

- Weakened hip flexion
- Weakened extension of the knee
- Sensory loss on the anterior thigh, medial leg, and foot

Obturator Nerve

- Loss of adduction of the thigh as well as sensory loss on medial thigh

Sciatic Nerve

- Weakened extension of the thigh
- Loss of flexion of the knee
- Loss of all functions below the knee
- Sensory loss on the posterior thigh, leg (except medial side), and foot

Tibial nerve only

- Weakness in flexion of the knee
- Weakness in plantar flexion
- Weakened inversion
- Sensory loss on the leg (except medial) and plantar foot

Common fibular nerve (neck of fibula)

Produces a combination of deficits of lesions of the deep and superficial fibular nerves

Deep fibular nerve

- Weakened inversion
- Loss of extension of the digits

Clinical Correlate

The **common fibular nerve** crosses the lateral aspect of the knee at the neck of the fibula, where it is the most frequently damaged nerve of the lower limb. Patients will present with loss of dorsiflexion at the ankle (**foot drop**), loss of **eversion**, and sensory loss on the lateral surface of the leg and the dorsum of the foot.

Clinical Correlate

The **common fibular nerve** may be compressed by the **piriformis muscle** when the nerve passes through the piriformis instead of inferior to the muscle with the tibial nerve. **Piriformis syndrome** results in motor and sensory loss to the lateral and anterior compartments of the leg.

- Loss of dorsiflexion ("foot drop")
- Sensory loss limited to skin of the first web space between the great and second toes

Superficial fibular nerve

- Loss of eversion of the foot
- Sensory loss on anterolateral leg and dorsum of the foot, except for the first web space

Sensory Innervation of the Lower Leg and Foot

- The lateral leg and the dorsum of the foot are supplied mainly by the **superficial fibular nerve**, with the exception of the first dorsal web space, which is supplied by the **deep fibular nerve**.
- The sole of the foot is supplied by the **lateral** and **medial plantar branches** of the **tibial nerve**.
- The sural nerve (a combination of both peroneal and tibial branches) supplies the posterior leg and lateral side of the foot.
- The **saphenous nerve** (a branch of the femoral nerve) supplies the medial leg and medial foot.

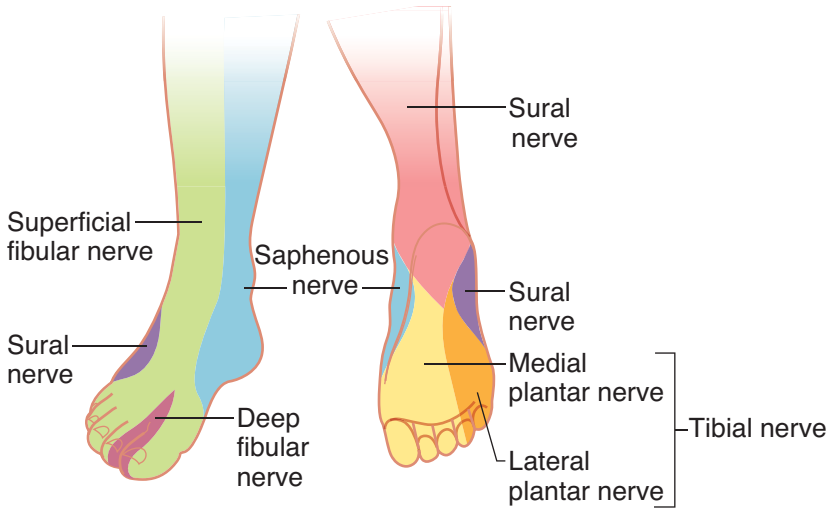

Figure II-5-2. Sensory Innervation of the Lower Leg and Foot

Clinical Correlate

The **sciatic nerve** is often damaged following posterior hip dislocation. A complete sciatic nerve lesion results in sensory and motor deficits in the posterior compartment of the thigh and all functions below the knee.

ARTERIAL SUPPLY AND MAJOR ANASTOMOSES

The obturator artery supplies the medial compartment of the thigh.

- **External iliac artery**
- **Femoral artery**
  - Profunda femoris artery
    - Medial circumflex femoral artery—supplies head of femur (avascular necrosis)
    - Lateral circumflex femoral artery
    - Perforating arteries—supplies posterior compartment of thigh
- **Popliteal artery:** supplies knee joint
  - Anterior tibial artery: courses with deep fibular nerve in anterior compartment of leg
    - Dorsalis pedis artery: pulse on dorsum of foot lateral to extensor hallucis longus tendon; used to note quality of blood supply to foot
  - Posterior tibial artery: courses with tibial nerve in posterior compartment of leg and passes posterior to the medial malleolus
    - Fibular artery: supplies lateral compartment of leg
    - Plantar arterial arch
    - Lateral plantar artery
    - Medial plantar artery

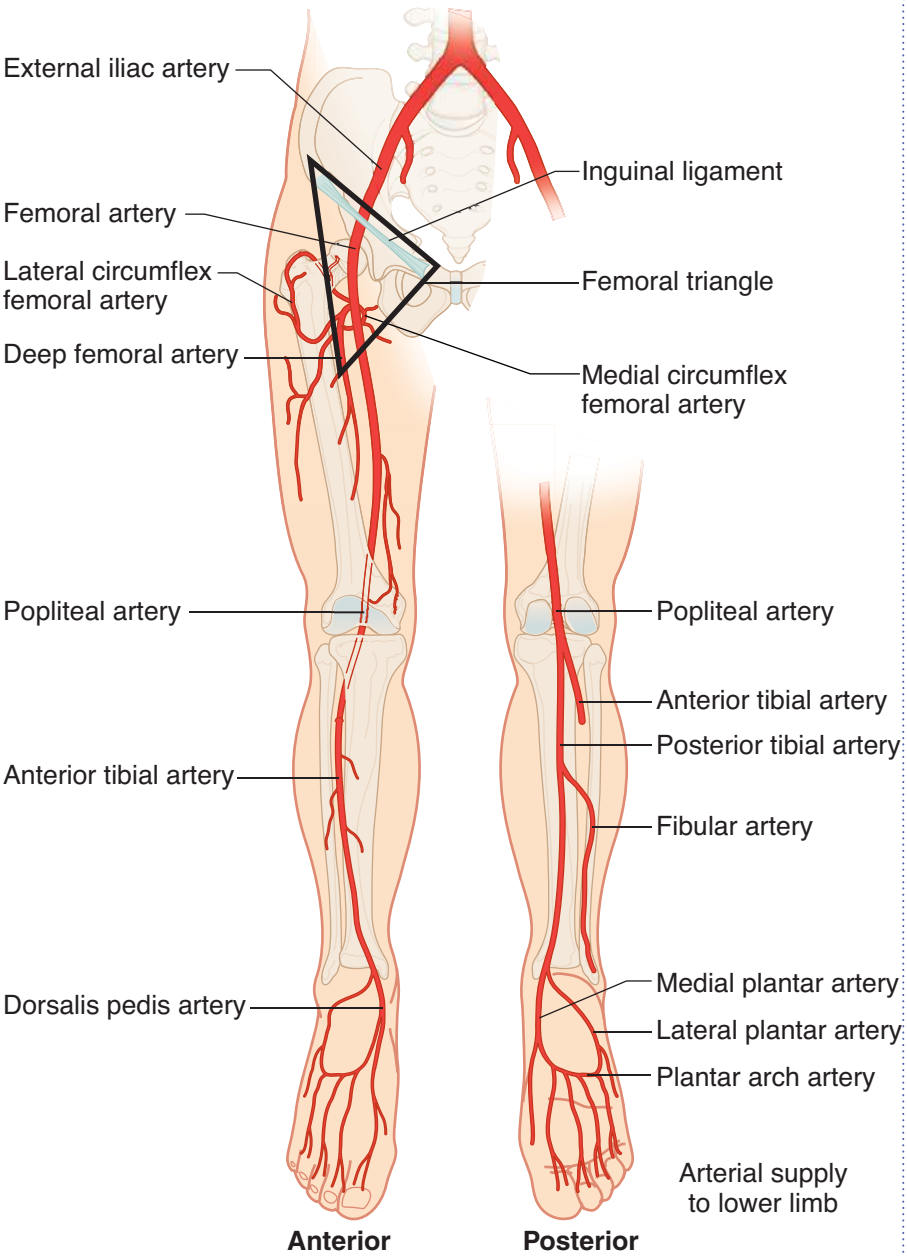

Figure II-5-3. Arterial Supply to Lower Limb

FEMORAL TRIANGLE

The femoral triangle is bounded by the inguinal ligament, and the sartorius and adductor longus muscles. Within the triangle are the femoral sheath (containing the femoral artery and vein and canal) and the femoral nerve (which is outside of the femoral sheath).

Passing under the inguinal ligament (from lateral to medial) are the femoral nerve, femoral artery, femoral vein, an empty space within the femoral sheath called the femoral canal, and inguinal lymph nodes within the femoral canal (NAVEL). The femoral canal is the site of **femoral hernias**.

Clinical Correlate

Tibial shaft fractures can cause lacerations of the anterior or posterior tibial arteries, producing either anterior or posterior **compartment syndromes.**

HIP

The hip joint is formed by the **head of the femur** and the **acetabulum.**

The fibrous capsule of the hip joint is reinforced by 3 ligamentous thickenings: **iliofemoral ligament, ischiofemoral ligament,** and **pubofemoral ligament.**

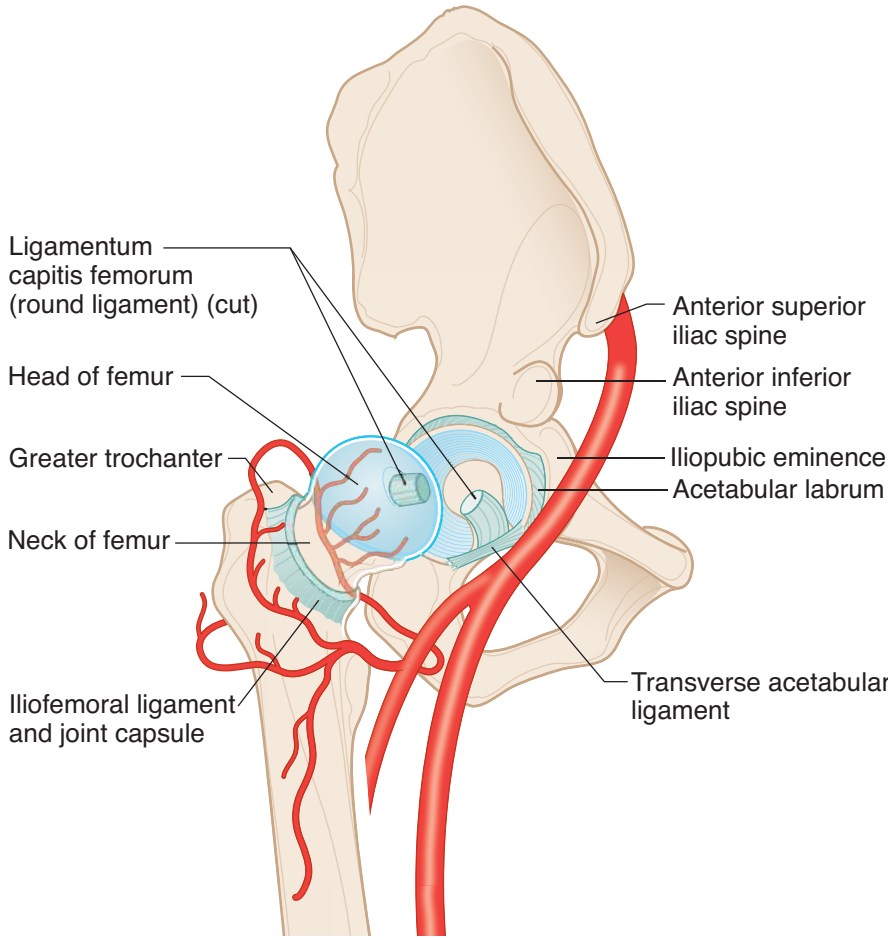

Figure II-5-4. Hip

Most of the blood supply to the head of the femur (arising mostly from the medial femoral circumflex artery) ascends along the neck of the femur. Fracture of the femoral neck can compromise this blood supply and lead to **avascular necrosis of the head of the femur.**

KNEE JOINT

The knee joint is a synovial joint formed by the articulations of the **medial and lateral femoral condyles**, the **medial and lateral tibial condyles**, and the **patella**. The primary movement at the knee joint is flexion and extension of the leg.

The knee joint is a weight-bearing joint and its stability depends on the muscles (quadriceps and hamstring muscles) that cross the joint. The knee is strengthened by several sets of ligaments.

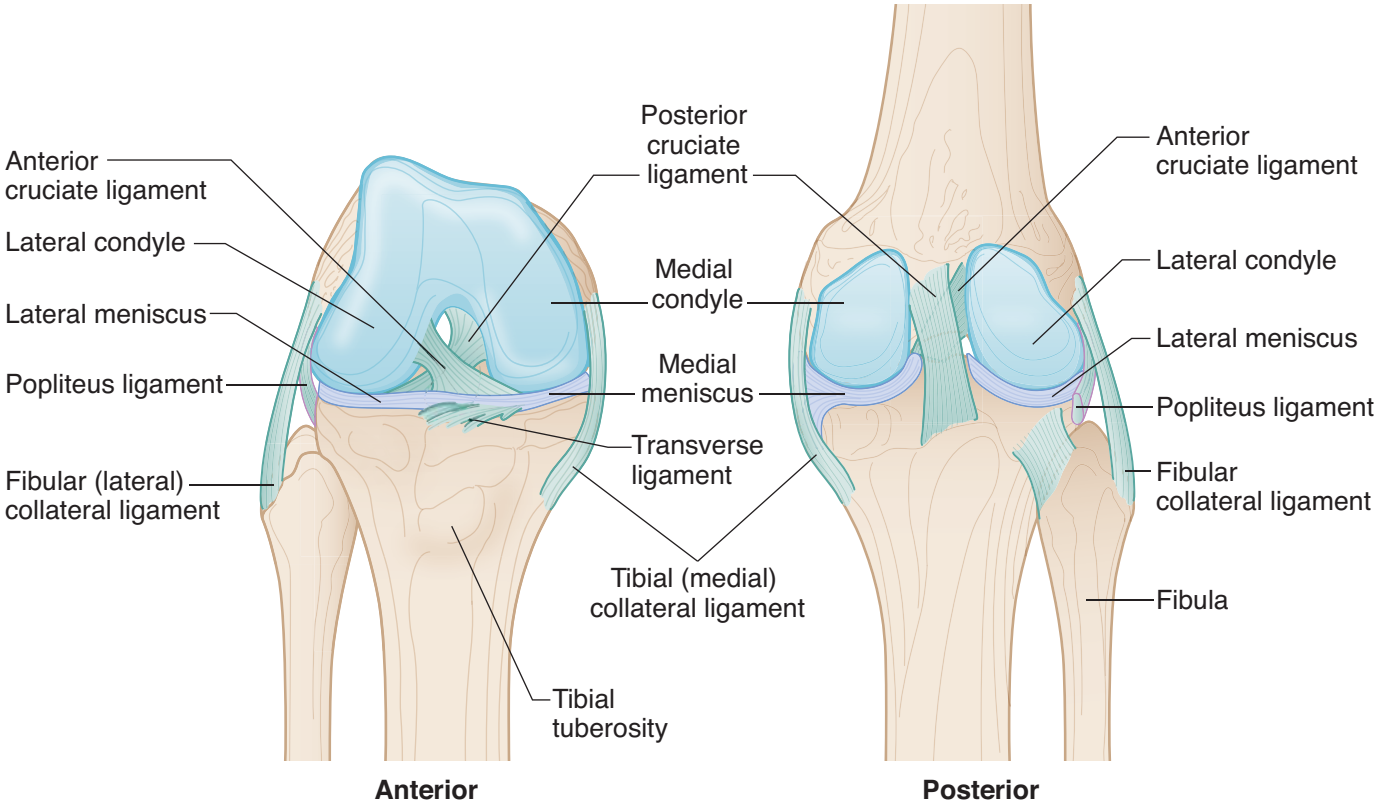

Figure II-5-5. Structures of the Knee

Tibial (Medial) and Fibular (Lateral) Collateral Ligaments

Tibial collateral ligament extends from the medial epicondyle of the femur inferiorly to attach to the medial aspect of the tibia. It is firmly attached to the capsule and medial meniscus. The tibial ligament prevents **lateral displacement** (abduction) of the tibia under the femur.

Fibular collateral ligament extends from the lateral condyle of the femur inferiorly to attach to the head of the fibula and is not attached to the lateral meniscus. The fibular ligament prevents **medial displacement** (adduction) of the tibia under the femur.

The collateral ligaments are taut with knee extension.

Clinical Correlate

The tibial collateral ligament is the most frequently torn ligament at the knee, commonly seen following lateral trauma to the knee.

Clinical Correlate

The tests for the integrity of the anterior and posterior cruciate ligaments are the **anterior and posterior drawer signs.** Tearing of the anterior cruciate ligaments allows the tibia to be easily pulled **forward** (anterior drawer sign). Tearing of the posterior cruciate ligament allows the tibial to be easily pulled **posteriorly** (posterior drawer sign).

Anterior and Posterior Cruciate Ligaments

These are intracapsular ligaments but are located outside the synovial membrane.

- **Anterior cruciate ligament** (ACL) attaches to the anterior aspect of the tibia and courses superiorly, posteriorly, and laterally to attach to the lateral condyle of the femur. The anterior ligament prevents **anterior displacement** of the tibia under the femur. Tension on the ACL is greatest when the knee is extended and resists hyperextension. It is weaker than the posterior cruciate ligament.
- **Posterior cruciate ligament** (PCL) attaches to the posterior aspect of the tibia and courses superiorly, anteriorly, and medially to attach to the medial condyle of the femur. The PCL prevents **posterior displacement** of the tibia under the femur. Tension on the PCL is greatest when the knee is flexed.

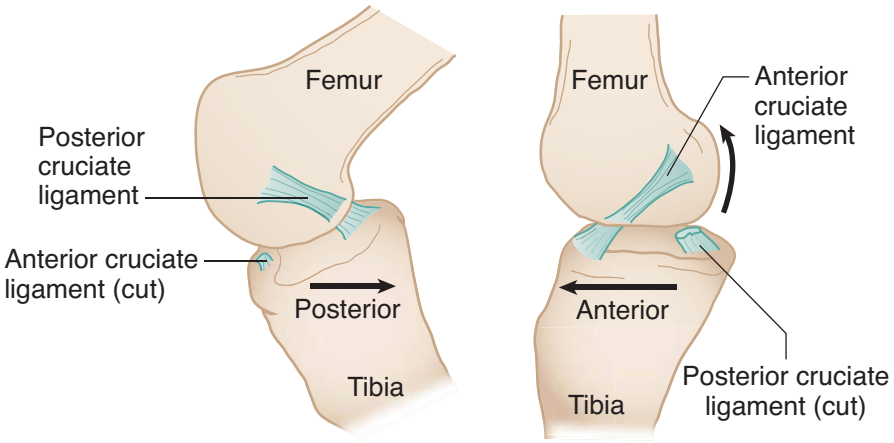

Figure II-5-6. Anterior and Posterior Cruciate Ligaments

Medial and Lateral Menisci

These are intracapsular wedges of fibrocartilage located between the articulating condyles that help make the articulating surfaces more congruent and also serve as shock absorbers.

- **Medial meniscus** is C-shaped and is firmly attached to the tibial collateral ligament. Therefore, it is less mobile and is more frequently injured than the lateral meniscus.
- **Lateral meniscus** is circular and more mobile. It is not attached to the fibular collateral ligament.

Common Knee Injuries

The 3 **most commonly injured structures at the knee** are the tibial collateral ligament, the medial meniscus, and the ACL (the terrible or unhappy triad)—injury usually results from a blow to the lateral aspect of the knee with the foot on the ground.

Patients with a **medial meniscus tear** have pain when the leg is medially rotated at the knee.

ANKLE JOINT

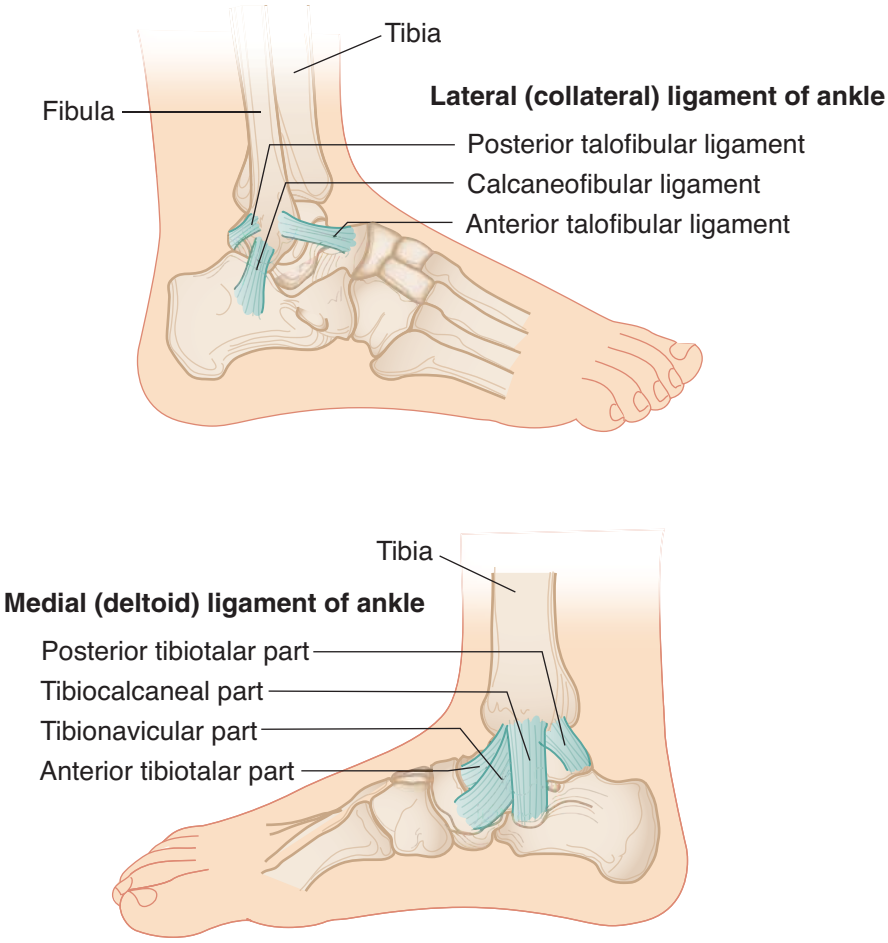

Figure II-5-7. Structures of the Ankle

Clinical Correlate

- Inversion sprains are most common.
- Anterior talofibular ligament is frequently damaged.

RADIOLOGY

From the IMC, © 2010 DxR Development Group, Inc.
All rights reserved.

Figure II-5-8. Lower Extremities: Anteroposterior View of Knee

From the IMC, © 2010 DxR Development Group, Inc.
All rights reserved.

Figure II-5-9. Lower Extremities: Lateral Knee

Head and Neck 6

Learning Objectives

- ❑ Explain information related to neck
- ❑ Answer questions about carotid and subclavian arteries
- ❑ Demonstrate understanding of embryology of the head and neck
- ❑ Solve problems concerning cranium
- ❑ Answer questions about cranial meninges and dural venous sinuses
- ❑ Use knowledge of intracranial hemorrhage
- ❑ Interpret scenarios on orbital muscles and their innervation

NECK

The **thoracic outlet** is the space bounded by the manubrium, the first rib, and T1 vertebra. The interval between the anterior and middle scalene muscles and the first rib **(scalene triangle)** transmits the structures coursing between the thorax, upper limb and lower neck. The triangle contains the **trunks of the brachial plexus** and the **subclavian artery**.

Thoracic outlet syndrome results from the compression of the **trunks of the brachial plexus and the subclavian artery** within the scalene triangle. Compression of these structures can result from tumors of the neck (Pancoast on apex of lung), a cervical rib or hypertrophy of the scalene muscles. The lower trunk of the brachial plexus (C8, T1) is usually the first to be affected. Clinical symptoms include the following:

- Numbness and pain on medial aspect of the forearm and hand
- Weakness of the muscles supplied by ulnar nerve in the hand (claw hand)
- Decreased blood flow into upper limb, indicated by weakened radial pulse

Compression can also affect the cervical sympathetic trunk (Horner's syndrome) and the recurrent laryngeal nerves (hoarseness).

Note

The subclavian vein and phrenic nerve (C 3, 4, and 5) are on the anterior surface of the anterior scalene muscle and are **not** in the scalene triangle.

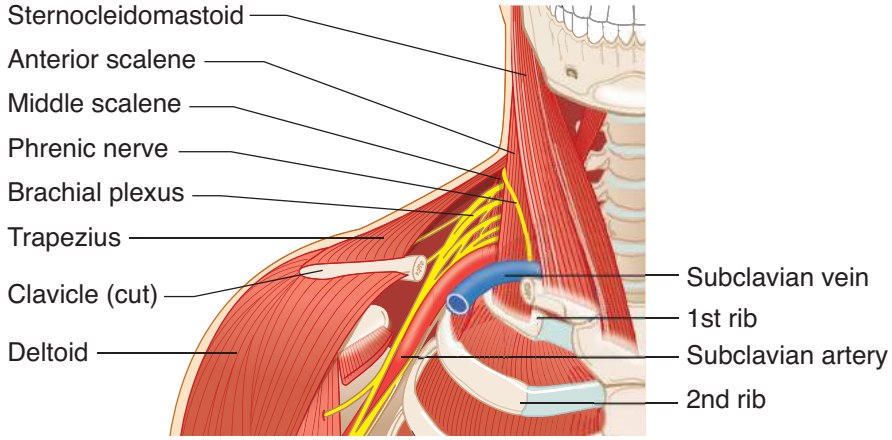

Figure II-6-1. Scalene Triangle of the Neck

CAROTID AND SUBCLAVIAN ARTERIES

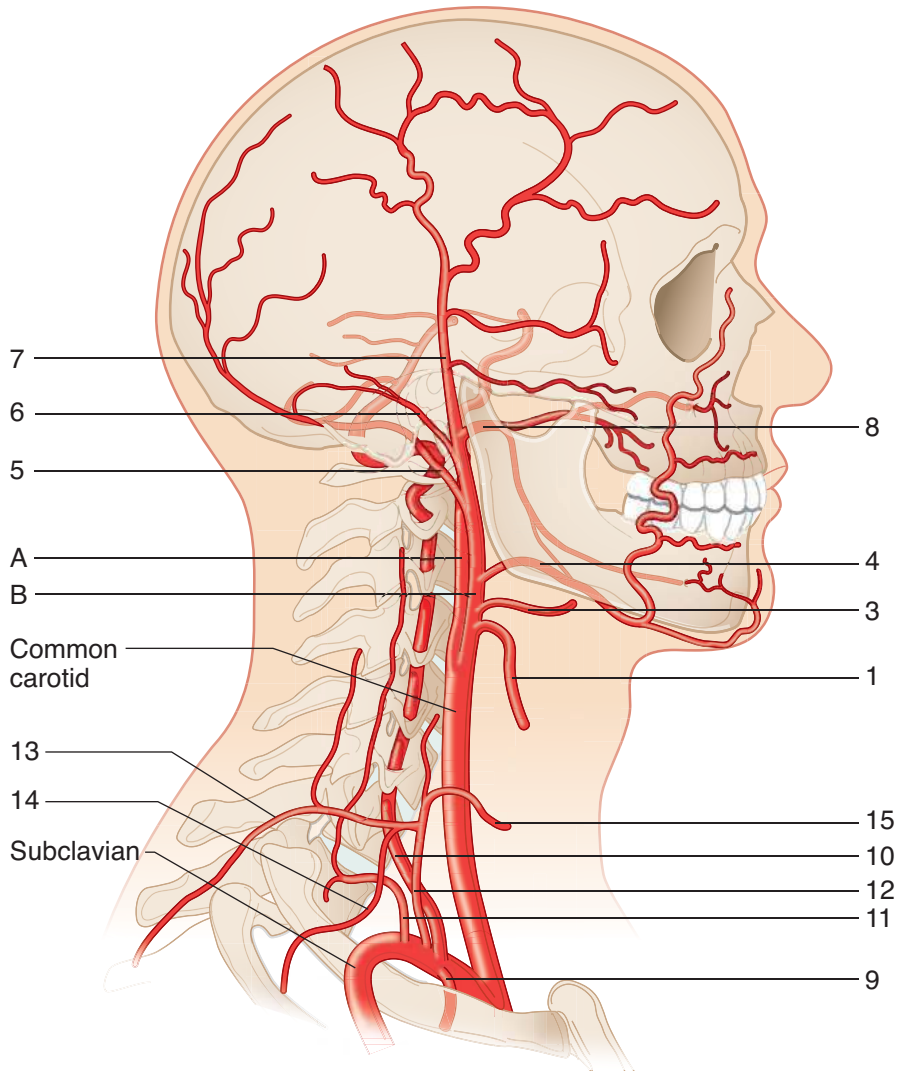

Common Carotid Artery
A. Internal carotid artery—ophthalmic artery and brain
B. External carotid artery
1. Superior thyroid
2. Ascending pharyngeal (not shown)
3. Lingual
4. Facial
5. Occipital
6. Posterior auricular
7. Superficial temporal
8. Maxillary—deep face; middle meningeal artery
Subclavian Artery
9. Internal thoracic—cardiac bypass
10. Vertebral—brain
11. Costocervical
12. Thyrocervical
13. Transverse cervical
14. Suprascapular—collaterals to shoulder
15. Inferior thyroid

Figure II-6-2. Arteries to the Head and Neck

Clinical Correlate

The most significant artery of the external carotid system is the middle meningeal artery. It arises from the maxillary artery in the infratemporal fossa and enters the skull through the foramen spinosum to supply skull and dura. Lacerations of this vessel result in an epidural hematoma.

EMBRYOLOGY OF THE HEAD AND NECK

Pharyngeal Apparatus

The pharyngeal apparatus consists of the following:

- **Pharyngeal arches** (1, 2, 3, 4, and 6) composed of **mesoderm and neural crest**
- **Pharyngeal pouches** (1, 2, 3, 4) lined with **endoderm**
- **Pharyngeal grooves or clefts** (1, 2, 3, and 4) lined **with ectoderm**

The anatomic associations relating to these structures in the fetus and adult are summarized below.

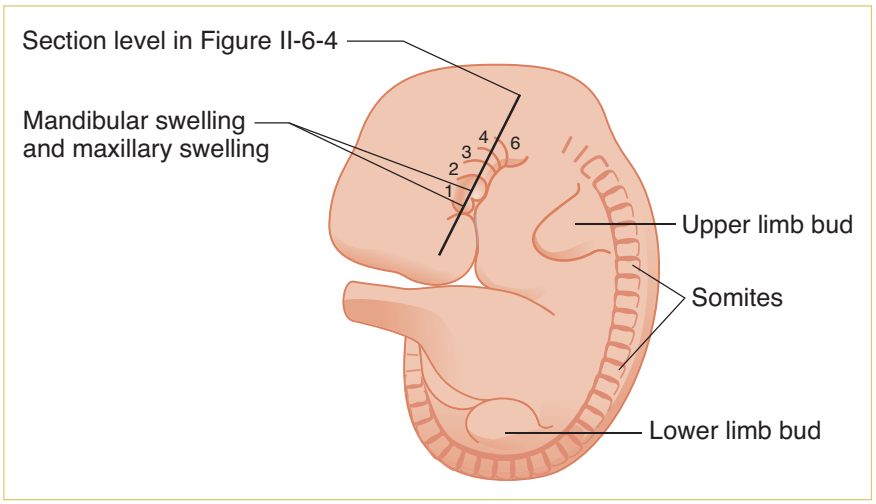

Figure II-6-3. Fetal Pharyngeal Apparatus

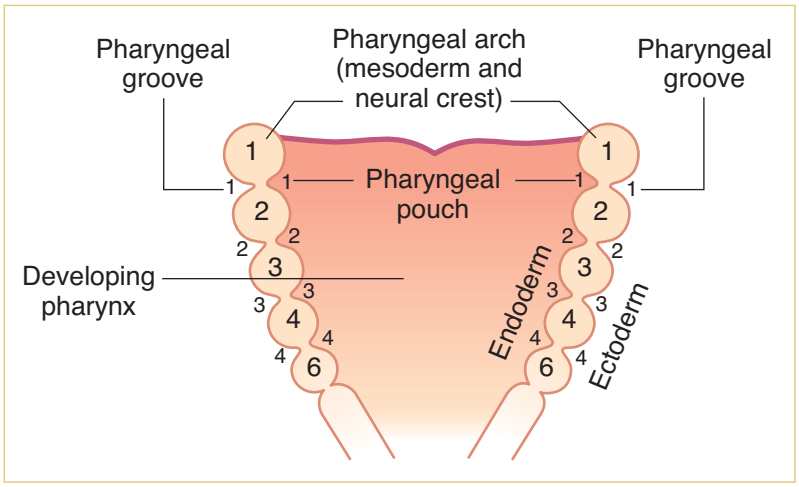

Figure II-6-4. Section through the Developing Pharynx

The components of the **pharyngeal arches** are summarized below.

Table II-6-1. Components of the Pharyngeal Arches

Arch	Nerve* (Neural Ectoderm)	Artery (Aortic Arch Mesoderm)	Muscle (Mesoderm)	Skeletal/Cartilage (Neural Crest)
1	Trigeminal: mandibular nerve		Four muscles of mastication: • Masseter • Temporalis • Lateral pterygoid • Medial pterygoid Plus: • Digastric (anterior belly) • Mylohyoid • Tensor tympani • Tensor veli palatini	Maxilla Mandible Incus Malleus
2	VII		Muscles of facial expression: Plus: • Digastric (posterior belly) • Stylohyoid • Stapedius	Stapes Styloid process Lesser horn and upper body of hyoid bone
3	IX	Right and left common carotid arteries Right and left internal carotid arteries	Stylopharyngeus muscle	Greater horn and lower body of hyoid bone
4	X – Superior laryngeal nerve – Pharyngeal branches	Right subclavian artery (right arch) Arch of aorta (left arch)	Cricothyroid muscle Soft palate Pharynx (5 muscles)	Thyroid cartilage
6	X Recurrent laryngeal nerve	Right and left pulmonary arteries Ductus arteriosus (left arch)	Intrinsic muscles of larynx (except cricothyroid muscle)	All other laryngeal cartilages

*Nerves are not derived from pharyngeal arch; they grow into the arch.

Note: The **ocular muscles** (III, IV, VI) and the **tongue muscles** (XII) do not derive from pharyngeal arch mesoderm but from mesoderm of the occipital somites (somitomeres).

The anatomic structures relating to the **pharyngeal pouches** are summarized below.

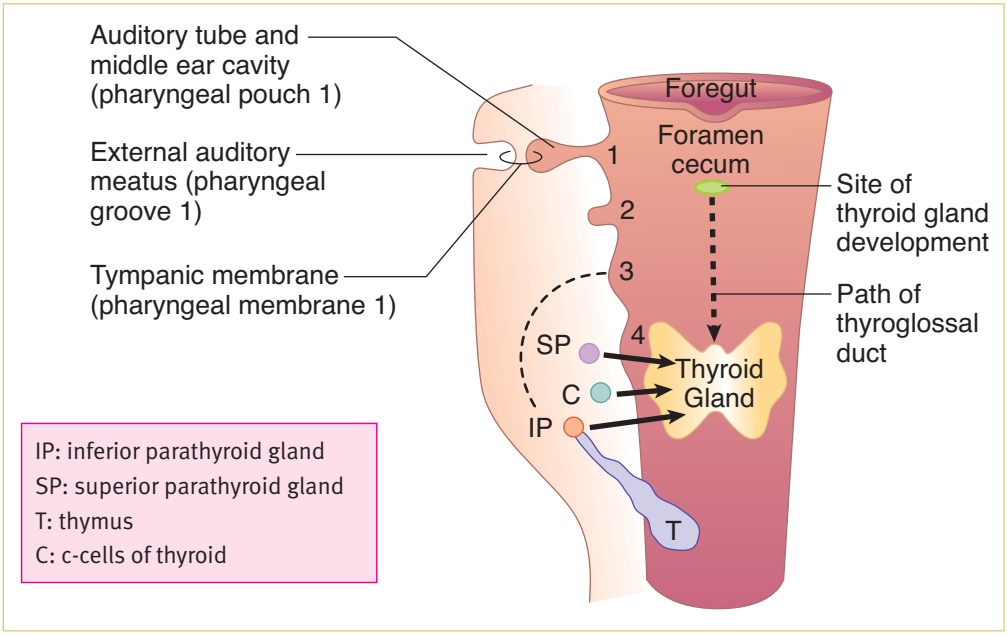

Figure II-6-5. Fetal Pharyngeal Pouches

The adult structures derived from the fetal pharyngeal pouches are summarized below.

Table II-6-2. Adult Structures Derived From the Fetal Pharyngeal Pouches

Pouch	Adult Derivatives
1	Epithelial lining of auditory tube and middle ear cavity
2	Epithelial lining of crypts of palatine tonsil
3	Inferior parathyroid (IP) gland Thymus (T)
4	Superior parathyroid (SP) gland C-cells of thyroid

*Neural crest cells migrate to form parafollicular C-cells of the thyroid.

Pharyngeal groove 1 gives rise to the epithelial lining of **external auditory meatus.** All other grooves are obliterated.

Clinical Correlate

Normally, the second, third, and fourth pharyngeal grooves are obliterated by overgrowth of the second pharyngeal arch. Failure of a cleft to be completely obliterated results in a branchial cyst or **lateral cervical cyst .**

Clinical Correlate

The **DiGeorge sequence** presents with immunologic problems and hypocalcemia, and may be combined with cardiovascular defects (persistent truncus arteriosus), abnormal ears, and micrognathia.

Thyroid Gland

The thyroid gland does not develop from a pharyngeal pouch. It develops from the **thyroid diverticulum,** which forms from the midline endoderm in the floor of the pharynx.

- The thyroid diverticulum migrates caudally to its adult anatomic position in the neck but remains connected to the foregut via the **thyroglossal duct,** which is later obliterated.
- The former site of the thyroglossal duct is indicated in the adult by the **foramen cecum**.

Tongue

The **anterior two-thirds of the tongue** is associated with **pharyngeal arches 1 and 2.** General sensation is carried by the lingual branch of the mandibular nerve (cranial nerve [CN] V). Taste sensation is carried by **chorda tympani of CN VII**.

The **posterior one third of the tongue** is associated with **pharyngeal arch 3.** General sensation and taste are carried by **CN IX.**

Most of the muscles of the tongue are innervated by CN XII.

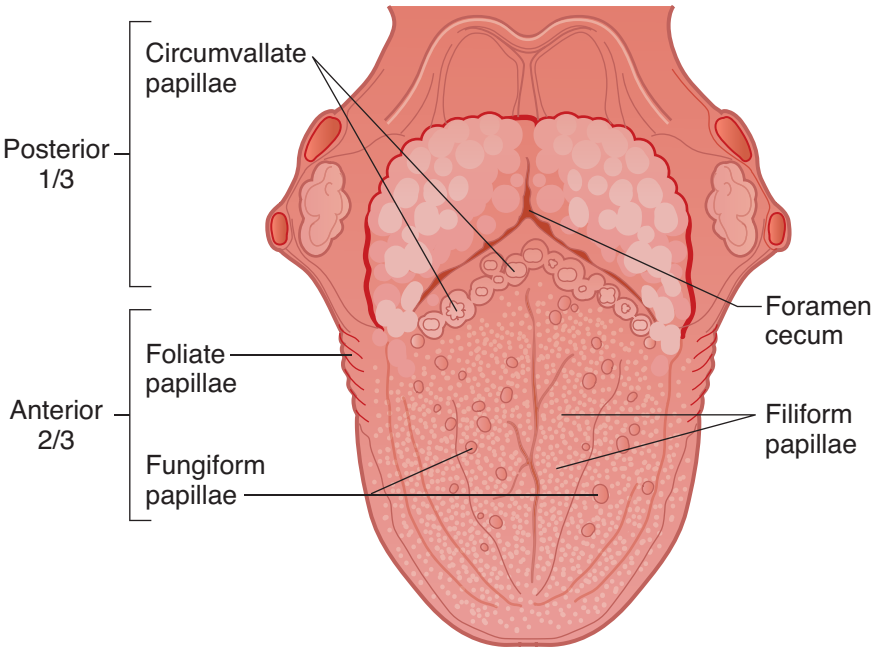

Sensory		
	General sensation	*Taste*
Post 1/3	IX	IX
Ant 2/3	V	VII
	Lingual branch of mandibular	Chorda tympani branch of VII nerve

Somatic Motor
CN XII innervates the intrinsic and extrinsic skeletal muscles of the tongue except palatoglossus muscle.

Figure II-6-6. Tongue

Clinical Correlate

Cleft lip occurs when the maxillary prominence fails to fuse with the medial nasal prominence.

Cleft palate occurs when the palatine shelves fail to fuse with each other or the primary palate.

Face and Palate

The **face** develops from 5 primordia of mesoderm (neural crest) of the first pharyngeal arch: a single frontonasal prominence, the pair of maxillary prominences, and the pair of mandibular prominences.

- The **intermaxillary segment** forms when the 2 medial nasal prominences of the frontonasal prominences fuse together at the midline and form the **philtrum of the lip** and the **primary palate**.
- The **secondary palate** forms from palatine shelves (maxillary prominence), which fuse in the midline, posterior to the incisive foramen.
- The primary and secondary palates fuse at the **incisive foramen** to form the definitive hard palate.

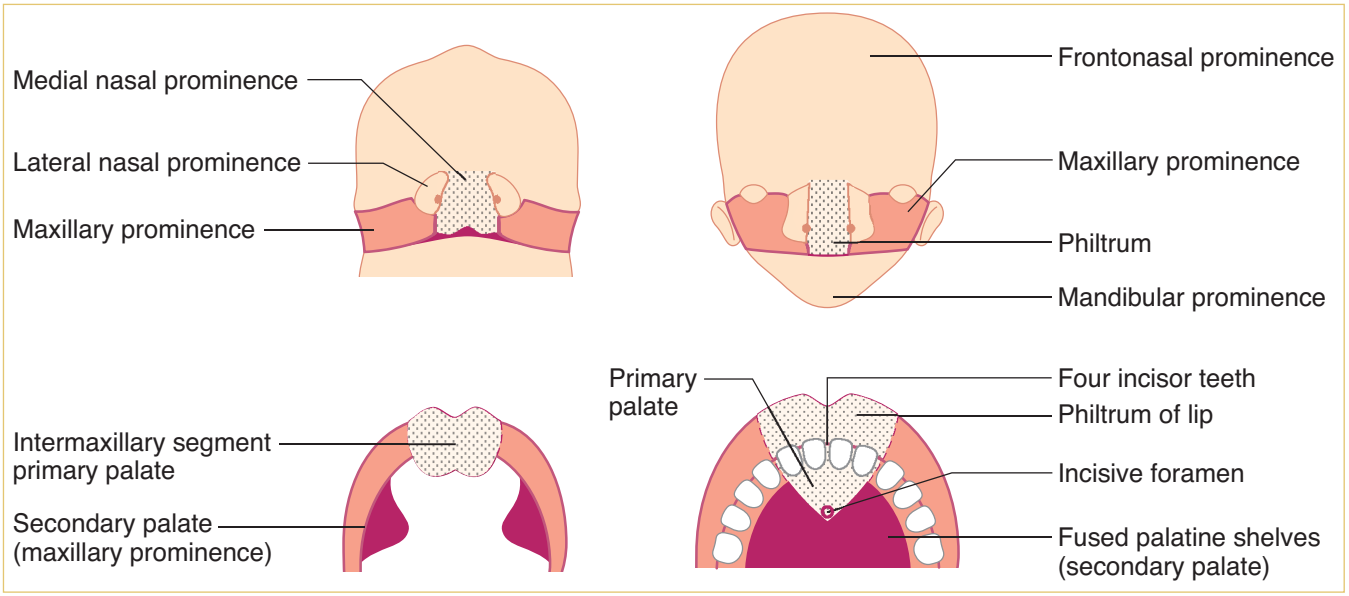

Figure II-6-7. Face and Palate Development

Clinical Correlate

First arch syndrome results from abnormal formation of pharyngeal arch 1 because of faulty migration of neural crest cells, causing facial anomalies. Two well-described syndromes are Treacher Collins syndrome and Pierre Robin sequence. Both defects involve neural crest cells.

Pharyngeal fistula occurs when pouch 2 and groove 2 persist, thereby forming a fistula generally found along the anterior border of the muscle.

Pharyngeal cyst occurs when pharyngeal grooves that are normally obliterated persist, forming a cyst usually located at the angle of the mandible.

Ectopic thyroid, parathyroid, or thymus results from abnormal migration of these glands from their embryonic position to their adult anatomic position. Ectopic thyroid tissue is found along the midline of the neck. Ectopic parathyroid or thymus tissue is generally found along the lateral aspect of the neck. May be an important issue during neck surgery.

Thyroglossal duct cyst or fistula occurs when parts of the thyroglossal duct persist, generally in the midline near the hyoid bone. The cyst may also be found at the base of the tongue (lingual cyst).

DiGeorge sequence occurs when pharyngeal pouches 3 and 4 fail to differentiate into the parathyroid glands and thymus. Neural crest cells are involved.

Clinical Correlate

Robin sequence presents with a triad of poor mandibular growth, cleft palate, and a posteriorly placed tongue.

Treacher Collins syndrome also presents with mandibular hypoplasia, zygomatic hypoplasia, down-slanted palpebral fissures, colobomas, and malformed ears.

Clinical Correlate

Cribriform plate fractures may result in dysosmia and rhinorrhea (CSF).

CRANIUM

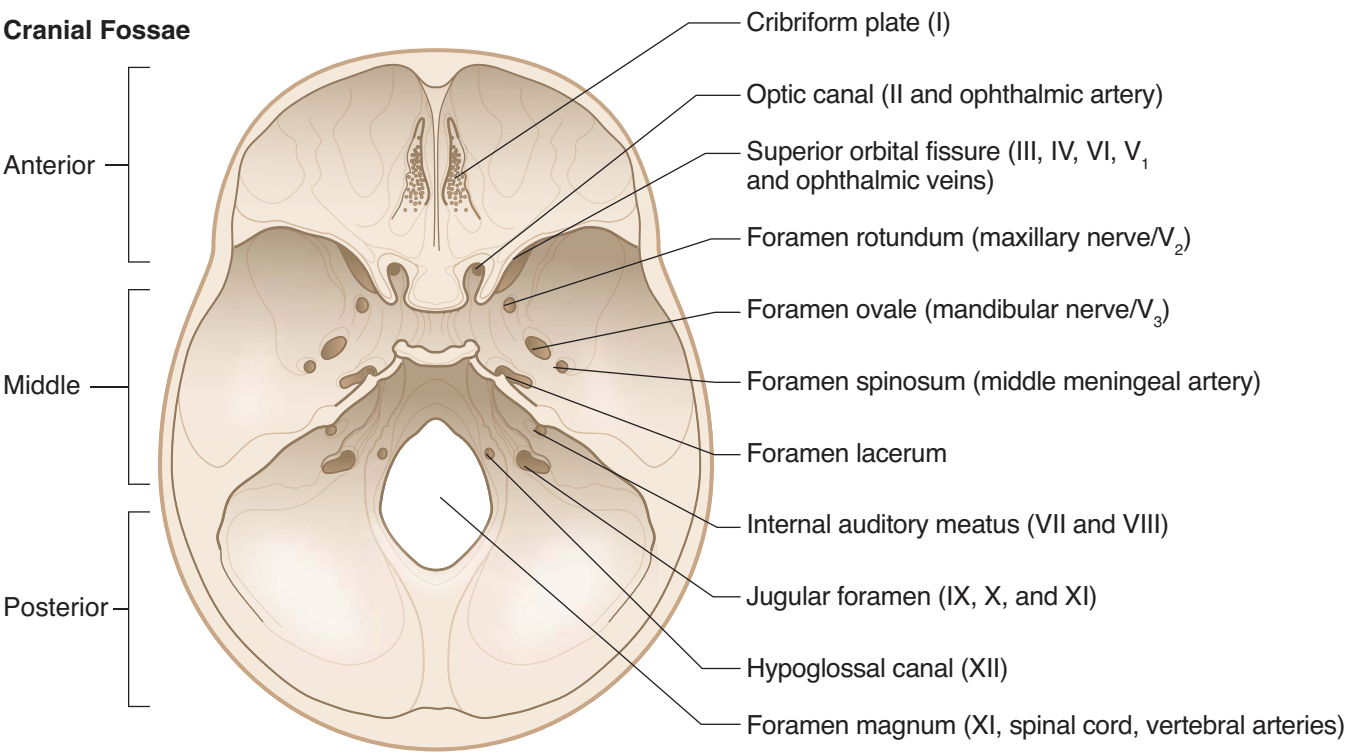

Figure II-6-8. Foramina: Cranial Fossae

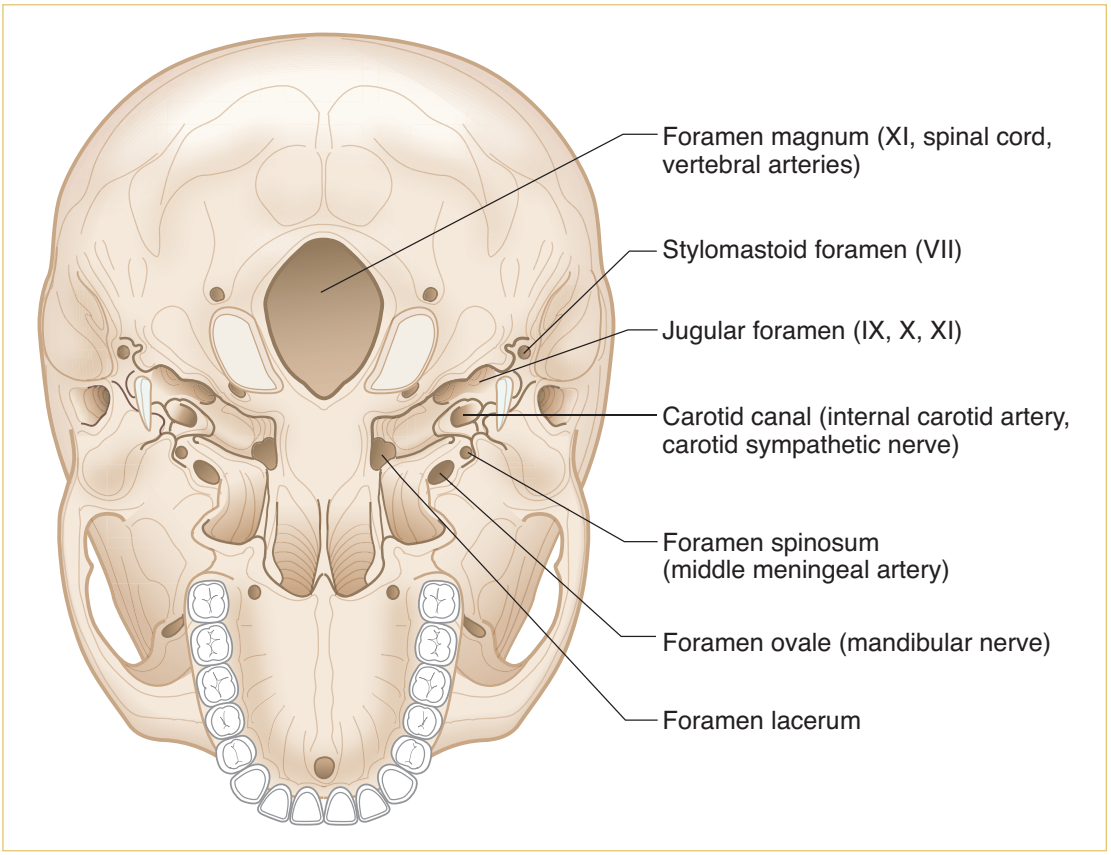

Figure II-6-9. Foramina: Base of Skull

Clinical Correlate

Jugular foramen syndrome may be caused by a tumor pressing on CN IX, X, and XI. Patients present with hoarseness, dysphagia (CN IX and X), loss of sensation over the oropharynx and posterior third of the tongue (CN IX), and trapezius and sternocleidomastoid weakness (CN XI). The nearby CN XII may be involved, producing tongue deviation to the lesioned side.

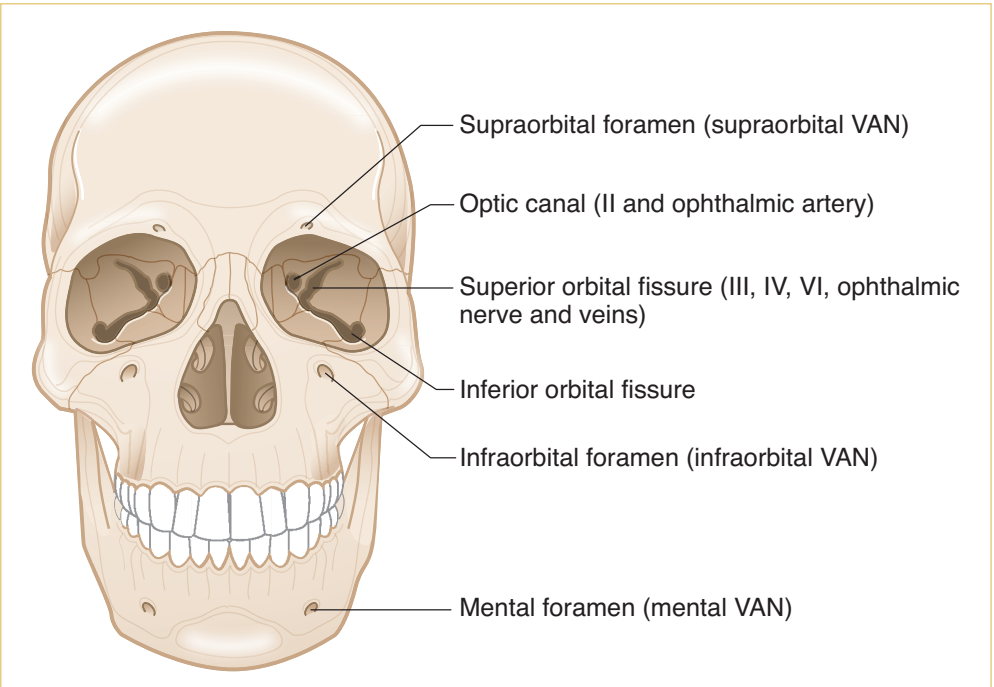

Figure II-6-10. Foramina: Front of Skull

CRANIAL MENINGES AND DURAL VENOUS SINUSES

Cranial Meninges

The brain is covered by 3 meninges that are continuous through the foramen magnum with the spinal meninges. There are several similarities and differences between spinal and cranial meninges.

- **Pia mater** tightly invests the surfaces of the brain and cannot be dissected away, having the same relationship with the brain as spinal pia mater.
- **Dura mater** (thickest) unlike the spinal dura, consists of 2 layers (**periosteal and meningeal**) that are fused together during most of their course in the cranial cavity.
  - **Periosteal layer**: outer layer lines the inner surfaces of the flat bones and serves as their periosteum; can easily be peeled away from the bones
  - **Meningeal (true dura) layer**: innermost layer that is mostly fused with the periosteal dura mater throughout the cranial cavity. At certain points in the cranium, the meningeal layer separates from the periosteal layer and forms the dural venous sinuses and connective tissue foldings or duplications: **falx cerebri, diaphragma sellae and tentorium cerebelli**. These duplications separate and support different parts of the CNS.

- **Arachnoid** is the thin, delicate membrane which lines and follows the inner surface of the meningeal dura. Projections of arachnoid called **arachnoid granulations** penetrate through the dura mater and extend into the superior sagittal dural venous sinus. Arachnoid granulations are where CSF returns to the systemic venous circulation.

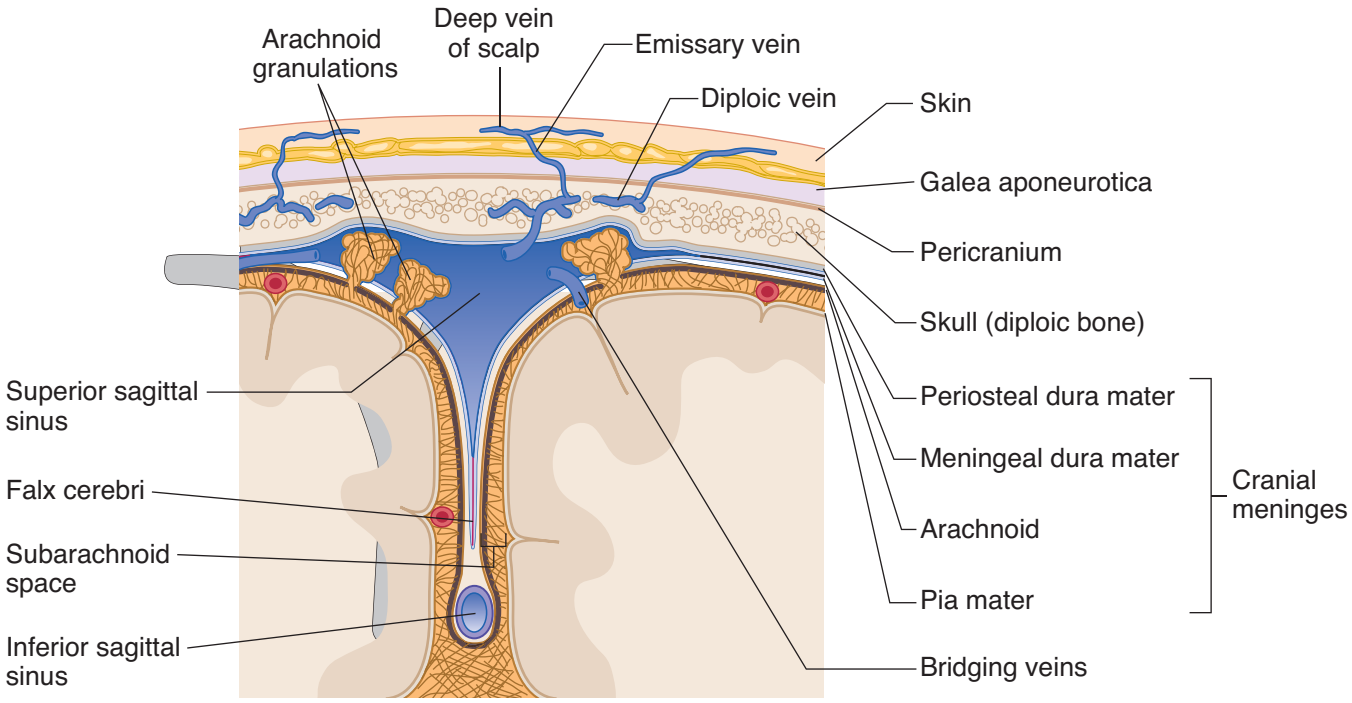

Figure II-6-11. Coronal Section of the Dural Sinuses

There are several spaces related to the cranial meninges:

- **Epidural space** is a potential space between the periosteal dura and the bones of the skull: site of epidural hematomas (described later).
- **Subdural space** is the potential space between the meningeal dura and the arachnoid membrane: site of subdural hematomas (described later).
- **Subarachnoid space** lies between the arachnoid and pia mater containing CSF: site of subarachnoid hemorrhage (described later).

Dural Venous Sinuses

Dural venous sinuses are formed at different points in the cranial cavity where the **periosteal** and **meningeal** dural layers separate to form endothelial lined venous channels called dural venous sinuses (Figures II-6-11 and II-6-12). The sinuses provide the major venous drainage from most structures within the cranial cavity. They drain mostly into the internal jugular vein, which exits the cranial floor at the jugular foramen. Most of the dural venous sinuses are located in the 2 largest duplications of meningeal dura mater (**falx cerebri** and the **tentorium cerebelli**).

The primary tributaries that flow into the sinuses are the following:

- **Cerebral** and **cerebelli veins** form **bridging veins,** which pass across the subdural space to drain into the sinuses.
- **Emissary** veins are valveless channels that course through the bones of the skull and allow dural sinuses to communicate with extracranial veins.
- **Diploic veins** drain the spongy (diploe) core of the flat bones.
- **Arachnoid granulations** are where CSF returns to the venous circulation.
- **Meningeal veins** drain the meninges.

Names of the Major Dural Sinuses

1. Superior sagittal*
2. Inferior sagittal
3. Straight*
4. Transverse* (2)
5. Sigmoid (2)
6. Cavernous (2)
7. Superior petrosal (2)

* Drain into the confluence of sinuses located at the inion.

Folds (Duplications) of Dura Mater

A. Falx cerebri
B. Tentorium cerebelli

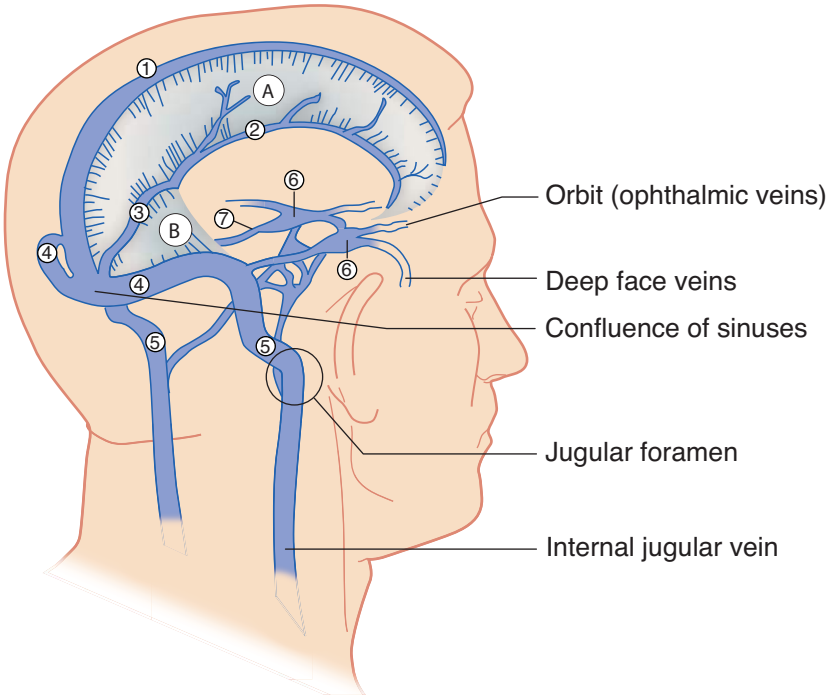

Figure II-6-12. Dural Venous Sinuses

Major dural venous sinuses

The major dural venous sinuses are the following:

- The **superior sagittal sinus** is located in the midsagittal plane along the superior aspect of the falx cerebri. It drains primarily into the confluence of the sinuses.
- The **inferior sagittal sinus** is located in the midsagittal plane near the inferior margin of the falx cerebri. It terminates by joining with the great cerebral vein (of Galen) to form the straight sinus at the junction of the falx cerebri and tentorium cerebelli.

- The **straight sinus** is formed by the union of the inferior sagittal sinus and the great cerebral vein. It usually terminates by draining into the confluence of sinuses (or into the transverse sinus).
- The **occipital sinus** is a small sinus found in the posterior border of the tentorium cerebelli. It drains into the confluence of sinuses.
- The **confluence of sinuses** is formed by the union of the superior sagittal, straight, and occipital sinuses posteriorly at the occipital bone. It drains laterally into the 2 transverse sinuses.
- The **transverse sinuses** are paired sinuses in the tentorium cerebelli and attached to the occipital bone that drain venous blood from the confluence of sinuses into the sigmoid sinuses.
- The **sigmoid sinuses** are paired and form a S-shaped channel in the floor of the posterior cranial fossa. The sigmoid sinus drains into the **internal jugular vein** at the **jugular foramen**.
- The paired **cavernous sinuses** are located on either side of the body of the sphenoid bone.
  - Each sinus receives blood primarily from the **orbit (ophthalmic veins)** and via emissary veins from the **deep face** (pterygoid venous plexus). Superficial veins of the maxillary face drain into the medial angle of the eye, enter the ophthalmic veins, and drain into the cavernous sinus.
  - Each cavernous sinus 1 via the superior and inferior petrosal sinuses into the sigmoid sinus and internal jugular vein, respectively.
  - The cavernous sinuses are the **most clinically significant** dural sinuses because of their relationship to a number of cranial nerves. **CN III** and **IV** and the **ophthalmic and maxillary** divisions of the trigeminal nerve are located in lateral wall of the sinus. **CN VI** and **internal carotid artery** are located centrally in the sinus.

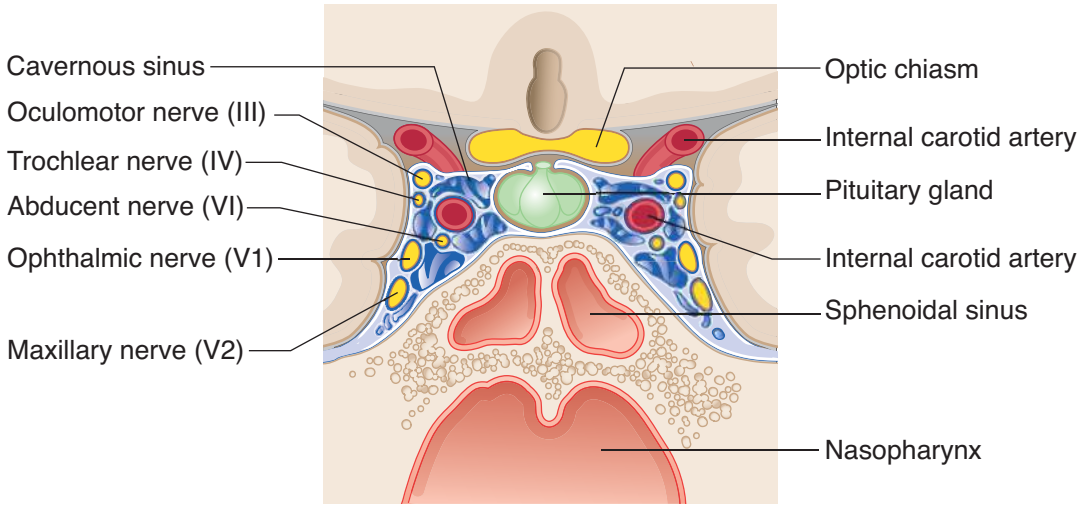

Figure II-6-13. Coronal Section Through Pituitary Gland and Cavernous Sinuses

Clinical Correlate

Cavernous Sinus Thrombosis

Infection can spread from the superficial and deep face into the cavernous sinus, producing a thrombosis that may result in swelling of sinus and damage the cranial nerves that are related to the cavernous sinus.

CN III and IV and the ophthalmic and maxillary divisions of CN V will be compressed in the lateral wall of the sinus.

CN VI and the internal carotid artery with its periarterial plexus of postganglionic sympathetic fibers will be compressed in the central part of the cavernous sinus. CN VI is typically affected first in a cavernous sinus thrombosis with the other nerves being affected later. Initially, patients have an internal strabismus (medially deviated eyeball) (CN VI lesion). Later, all eye movements are affected, along with altered sensation in the skin of the upper face and scalp.

INTRACRANIAL HEMORRHAGE

Epidural Hematoma

An **epidural hematoma** results from trauma to the lateral aspect of the skull which lacerates the middle meningeal artery. Arterial hemorrhage occurs rapidly in the epidural space between the periosteal dura and the skull.

- Epidural hemorrhage forms a **lens-shaped** (biconvex) hematoma at the lateral hemisphere.
- Epidural hematoma is associated with a momentary loss of consciousness followed by a lucid (asymptomatic) period of up to 48 hours.
- Patients then develop symptoms of elevated intracranial pressure such as headache, nausea, and vomiting, combined with neurological signs such as hemiparesis.
- Herniation of the temporal lobe, coma, and death may occur rapidly if the arterial blood is not evacuated.

Subdural Hematoma

A **subdural hematoma** results from head trauma that tears superficial ("bridging") cerebral veins at the point where they enter the superior sagittal sinus. A subdural hemorrhage occurs between the meningeal dura and the arachnoid.

- Subdural hemorrhage forms a **crescent-shaped** hematoma at the lateral hemisphere.
- Large subdural hematomas result in signs of elevated intracranial pressure such as headache and nausea.
- Small or chronic hematomas are often seen in elderly or chronic alcoholic patients.
- Over time, herniation of the temporal lobe, coma, and death may result if the venous blood is not evacuated.

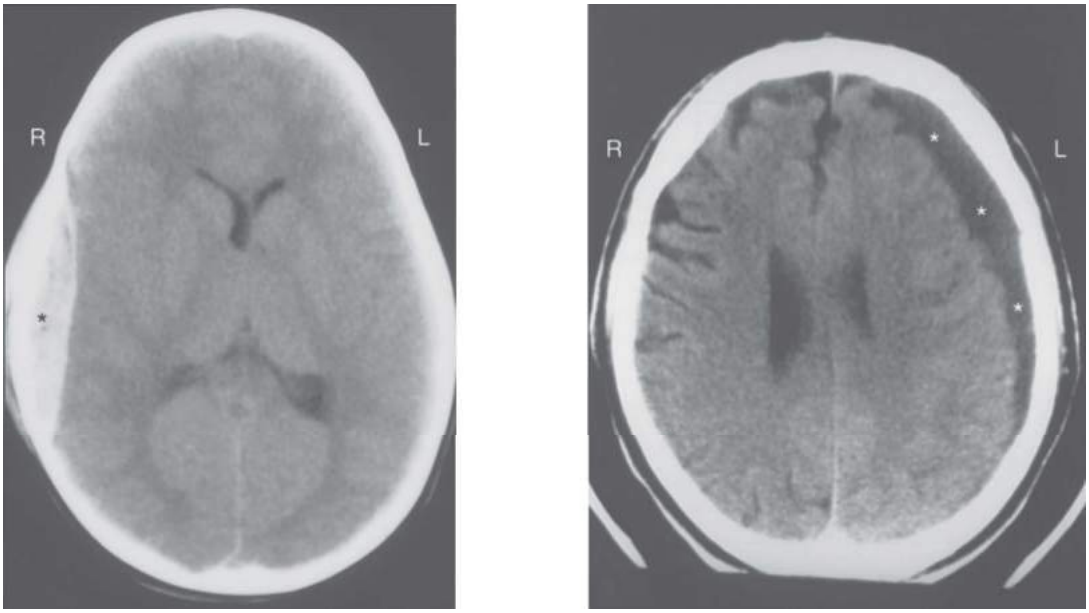

A. Epidural Hematoma*

B. Subdural Hematoma*

Figure II-6-14. Intracranial Hemorrhage

Nolte: The Human Brain.
Copyright Mosby, an imprint of Elsevier, Inc. Used with permission.

Subarachnoid Hemorrhage

A **subarachnoid hemorrhage** results from a rupture of a berry aneurysm in the circle of Willis. The most common site is in the anterior part of the circle of Willis at the branch point of the anterior cerebral and anterior communicating arteries. Other common sites are in the proximal part of the middle cerebral artery or at the junction of the internal carotid and posterior communicating arteries. Typical presentation is the onset of a severe headache.

ORBITAL MUSCLES AND THEIR INNERVATION

In the orbit, there are 6 extraocular muscles that move the eyeball. A seventh muscle, the levator palpebrae superioris, elevates the upper eyelid.

- Four of the 6 extraocular muscles (the superior, inferior, and medial rectus, and the inferior oblique, plus the levator palpebrae superioris) are innervated by the oculomotor nerve (CN III).
- The superior oblique muscle is the only muscle innervated by the trochlear nerve (CN IV).
- The lateral rectus is the only muscle innervated by the abducens nerve (CN VI).
- The levator palpebrae superioris is composed of skeletal muscle innervated by the oculomotor nerve (CN III) and smooth muscle (the superior tarsal muscle) innervated by sympathetic fibers.
- Sympathetic fibers reach the orbit from a plexus on the internal carotid artery of postganglionic axons that originate from cell bodies in the superior cervical ganglion.

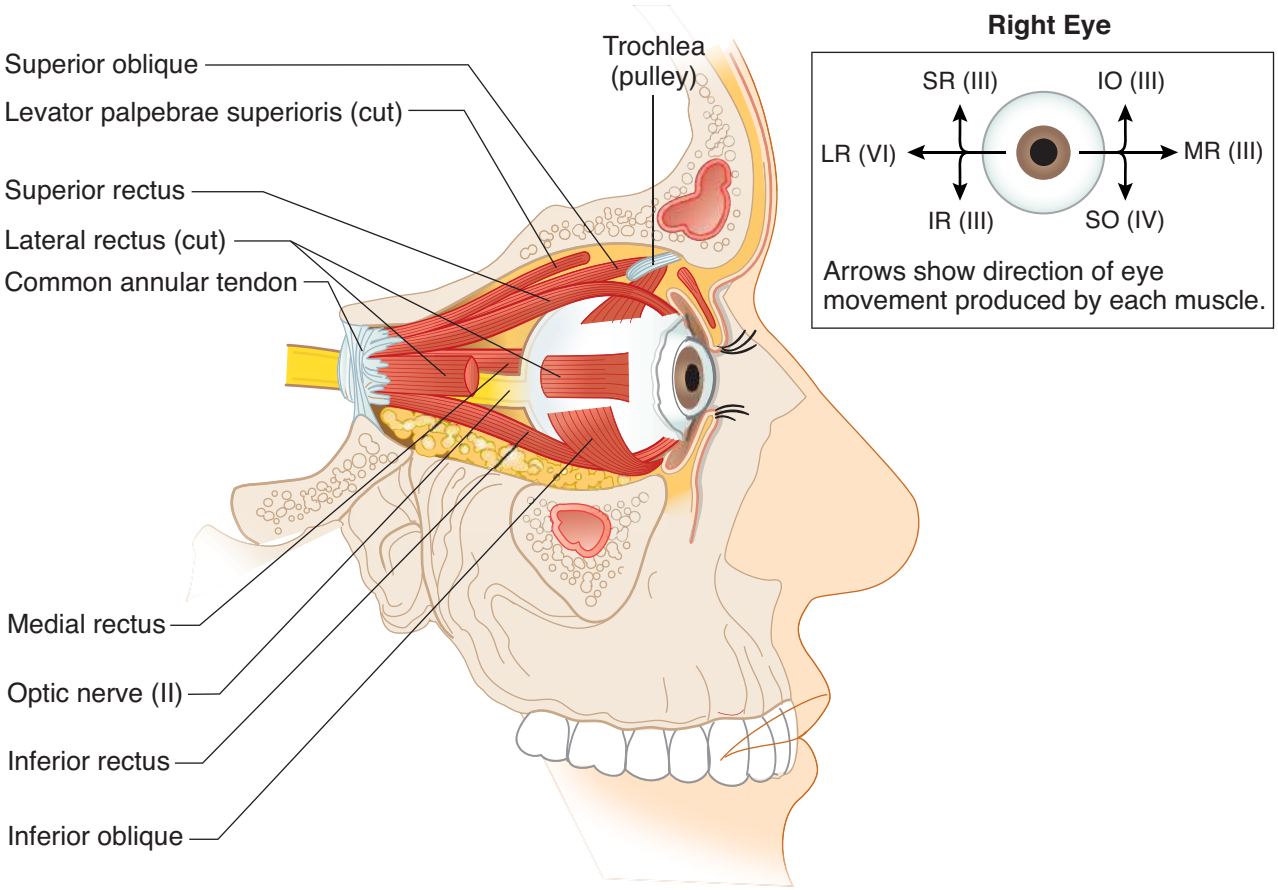

Figure II-6-15. Muscles of the Eye

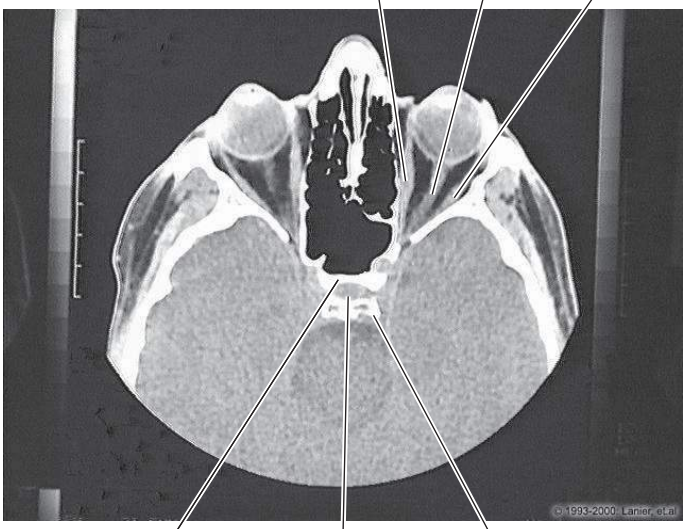

From the IMC. © 2010 DxR Development Group, Inc. All rights reserved.

Figure II-6-16. Head and Neck: CT, Orbit

PART III

Neuroscience

Nervous System Organization and Development

1

Learning Objectives

- ❑ Explain information related to autonomic nervous system
- ❑ Use knowledge of general organization

NERVOUS SYSTEM

The central nervous system (CNS) consists of the brain and spinal cord, which develop from the neural tube.

The peripheral nervous system (PNS) contains cranial and spinal nerves that consist of neurons that give rise to axons, which grow out of the **neural tube**, and neurons derived from **neural crest cells**. Skeletal motor neurons and axons of preganglionic autonomic neurons are derived from the neural tube.

Neural crest cells form sensory neurons and postganglionic autonomic neurons. The neuronal cell bodies of these neurons are found in ganglia. Therefore, all ganglia found in the PNS contain either sensory or postganglionic autonomic neurons and are derived from neural crest cells.

Chromaffin cells are neural crest cells, which migrate into the adrenal medulla to form postganglionic sympathetic neurons.

Development of the Nervous System

Neurulation begins in the third week; both CNS and PNS derived from neuroectoderm. The **notochord** induces the overlying ectoderm to form the **neural plate (neuroectoderm)**. By end of the third week, **neural folds** grow over midline and fuse to form **neural tube**.

- During closure, **neural crest** cells also form from neuroectoderm.
- **Neural tube** 3 primary vesicles → 5 primary vesicles → brain and spinal cord
- Brain stem and spinal cord have an **alar** plate (**sensory**) and a **basal** plate (**motor**); plates are separated by the **sulcus limitans**.
- **Neural crest** → sensory and postganglionic autonomic neurons, and other non-neuronal cell types.
- **Peripheral NS (PNS):** cranial nerves (12 pairs) and spinal nerves (31 pairs)

Note

Alpha-fetoprotein (AFP) levels may also be elevated in gastroschisis and omphalocele. AFP levels are low in pregnancy of Down syndrome fetus.

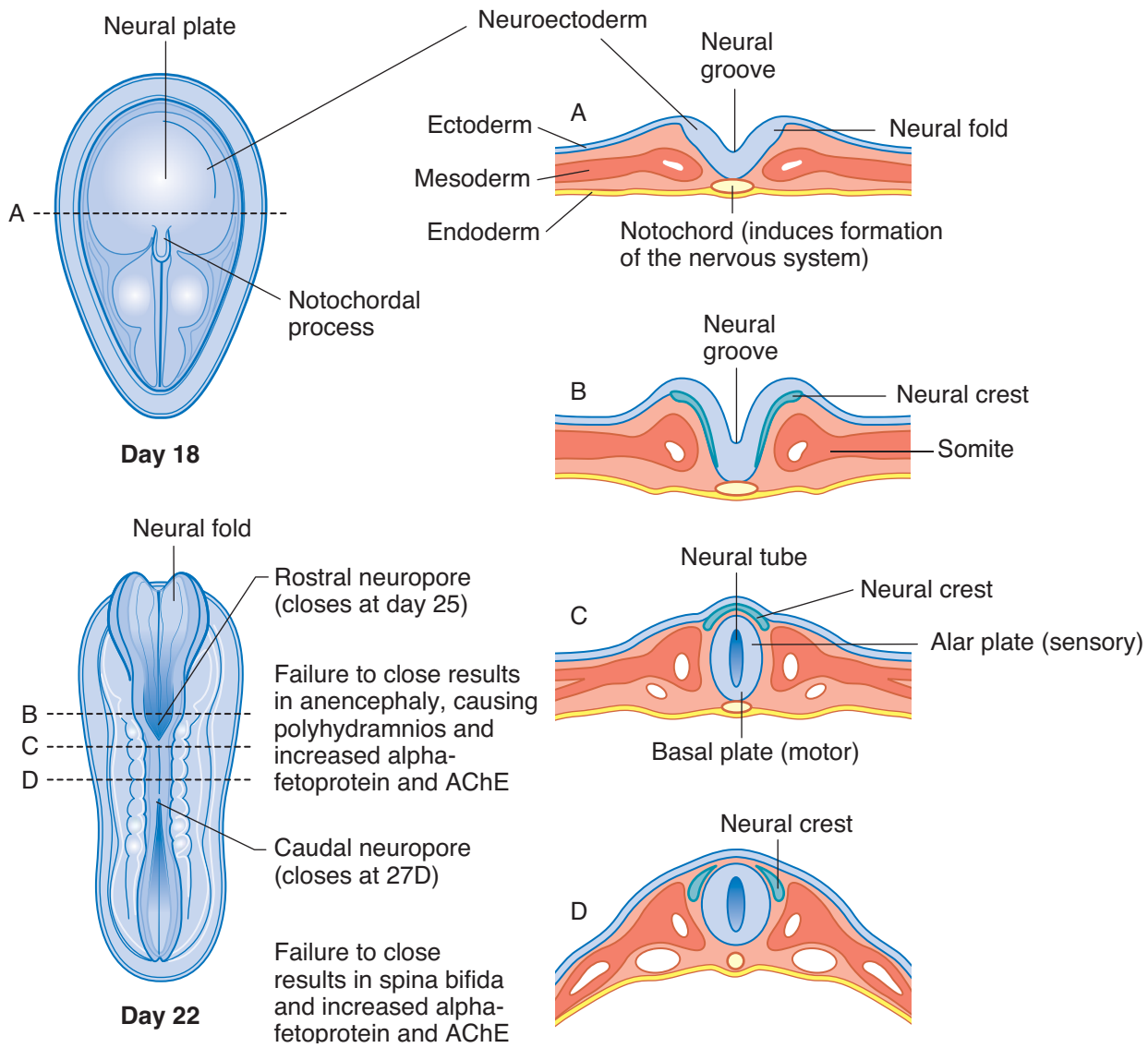

Figure III-1-1. Development of Nervous System

Central Nervous System

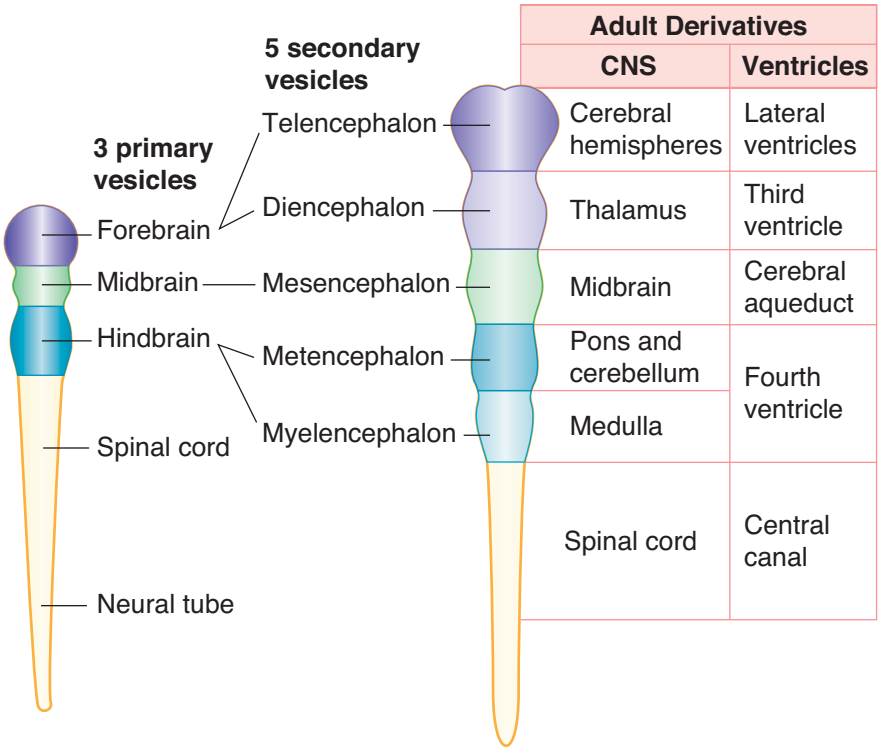

Figure III-1-2. Adult Derivatives of Secondary Brain Vesicles

Clinical Correlate

Axonal polyneuropathies produce distal "glove-and-stocking" weakness or sensory deficits, and are related to axonal transport failure. Diabetes mellitus patients present with sensory neuropathies.

Table III-1-1. Adult Derivatives of Secondary Brain Vesicles

	Structures	Neural Canal Remnant
Telencephalon	Cerebral hemispheres, most of basal ganglia	Lateral ventricles
Diencephalon	Thalamus, hypothalamus, subthalamus, epithalamus (pineal gland), retina and optic nerve	Third ventricle
Mesencephalon	Midbrain	Cerebral aqueduct
Metencephalon	Pons, cerebellum	Fourth ventricle
Myelencephalon	Medulla Spinal cord	Central canal

Table III-1-2. Congenital Malformations of the Nervous System

Condition	Types	Description
Anencephaly	—	Failure of **anterior neuropore** to close Brain does not develop Incompatible with life Increased AFP during pregnancy and AChE
Spina bifida	Spina bifida occulta **(Figure A)**	Failure to induce bone growth around the spinal cord Mildest form **Vertebrae** fail to form around spinal cord **No** increase in **AFP** Asymptomatic; tuft of hair over defect.
	Spina bifida with meningocele **(Figure B)**	**Meninges** protrude through vertebral defect Increase in AFP
	Spina bifida with meningomyelocele **(Figure C)**	**Meninges** and **spinal cord** protrude through vertebral defect; seen with Arnold-Chiari Type II Increase in AFP
	Spina bifida with myeloschisis **(Figure D)**	Most severe **Spinal cord** can be seen **externally** Increase in AFP and AChE
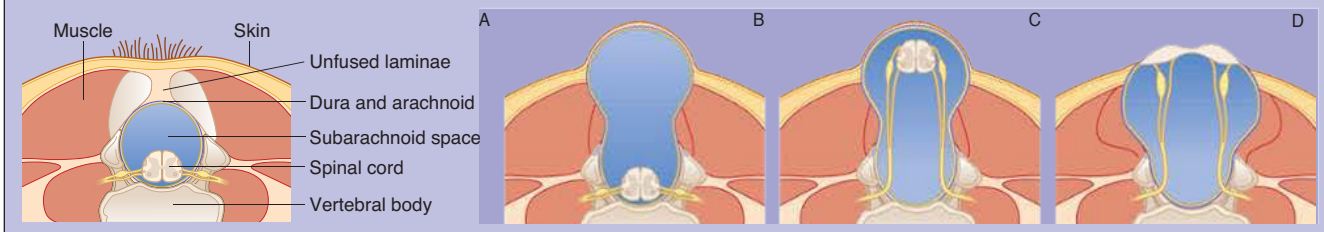		
Arnold-Chiari malformation	Type I	Most common Mostly **asymptomatic** in children Downward displacement of cerebellar tonsils through foramen magnum Frequent association with **syringomyelia**
	Type II	More often **symptomatic** Downward displacement of **cerebellar vermis** Compression of IV ventricle → obstructive **hydrocephaly** Frequent lumbar **meningomyelocele**
Dandy-Walker malformation		Failure of foramina of Luschka and Magendie to open → **dilation of IV ventricle** Agenesis of cerebellar vermis and splenium of the corpus callosum
Hydrocephalus		Most often caused by stenosis of cerebral aqueduct CSF accumulates in ventricles and subarachnoid space Increased head circumference
Holoprosencephaly		Incomplete separation of cerebral hemispheres One ventricle in telencephalon Seen in trisomy 13 (Patau)

Abbreviation: AFP, alpha-fetoprotein

Table III-1-3. Germ Layer Derivatives

Ectoderm	Mesoderm	Endoderm
Surface ectoderm Epidermis Hair Nails Inner ear, external ear Enamel of teeth Lens of eye Anterior pituitary (Rathke's pouch) Parotid gland **Neuroectoderm** **Neural tube** Central nervous system Retina and optic nerve Pineal gland Neurohypophysis Astrocytes Oligodendrocytes (CNS myelin)	**Muscle** Smooth Cardiac Skeletal Connective tissue All serous membranes Bone and cartilage Blood, lymph, cardiovascular organs Adrenal cortex Gonads and internal reproductive organs Spleen Kidney and ureter Dura mater	**Forms epithelial parts of:** Tonsils Thymus Pharynx Larynx Trachea Bronchi Lungs Urinary bladder Urethra Tympanic cavity Auditory tube GI tract
Ectoderm	**Mesoderm**	**Endoderm**
Neural crest Adrenal medulla Ganglia Sensory (unipolar) Autonomic (postganglionic) Pigment cells (melanocytes) Schwann cells (PNS myelin) Meninges Pia and arachnoid mater Pharyngeal arch cartilage (first arch syndromes) Odontoblasts Parafollicular (C) cells Aorticopulmonary septum (tetralogy of Fallot) Endocardial cushions (Down syndrome)		**Forms parenchyma of:** Liver Pancreas Tonsils Thyroid gland Parathyroid glands Glands of the GI tract Submandibular gland Sublingual gland

Yolk sac derivatives:

Primordial germ cells

Early blood and blood vessels

AUTONOMIC NERVOUS SYSTEM

The autonomic nervous system (ANS) is responsible for the motor innervation of smooth muscle, cardiac muscle, and glands of the body. It is divided into the **sympathetic** and **parasympathetic** nervous systems. In both systems there are 2 neurons in the peripheral distribution of the motor innervation.

- Preganglionic neuron with cell body in CNS
- Postganglionic neuron with cell body in a ganglion in the PNS

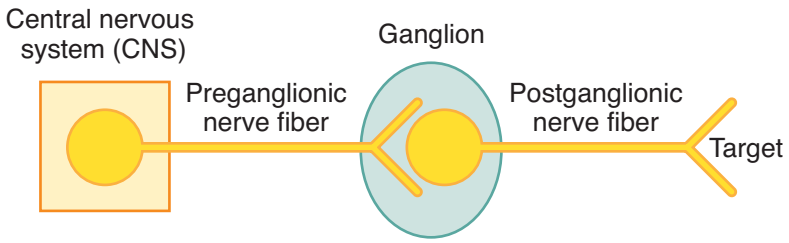

Figure III-1-3. Autonomic Nervous System

Peripheral Nervous System

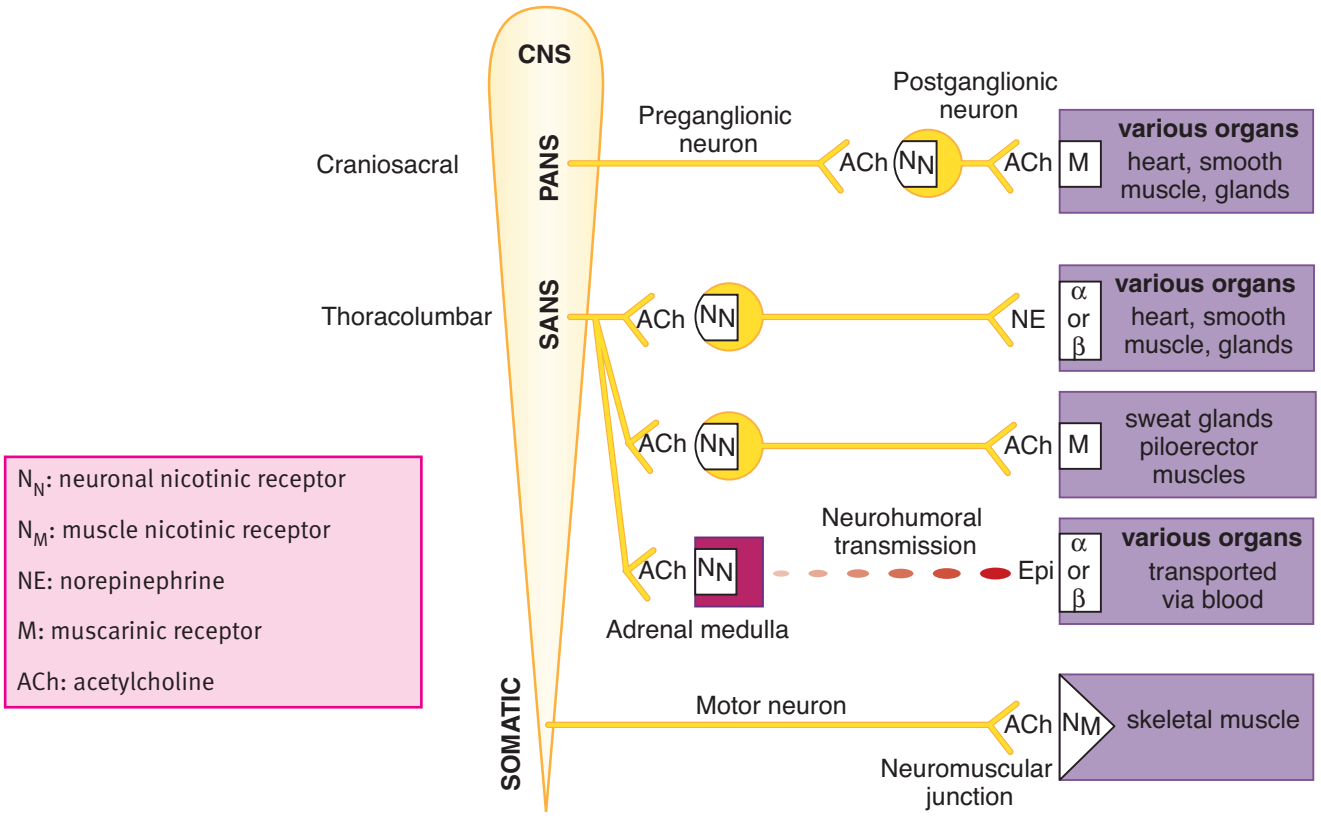

Figure III-1-4. Autonomic and Somatic Nervous System Neurotransmitters/Receptors

- **Somatic nervous system:** 1 neuron (from CNS → effector organ)
- **ANS:** 2 neurons (from CNS → effector organ)
  - **Preganglionic** neuron: cell body in CNS
  - **Postganglionic** neuron: cell body in ganglia in PNS
  - **Parasympathetic:** long preganglionic, short postganglionic
  - **Sympathetic:** short preganglionic, long postganglionic (except adrenal medulla)

Parasympathetic Nervous System

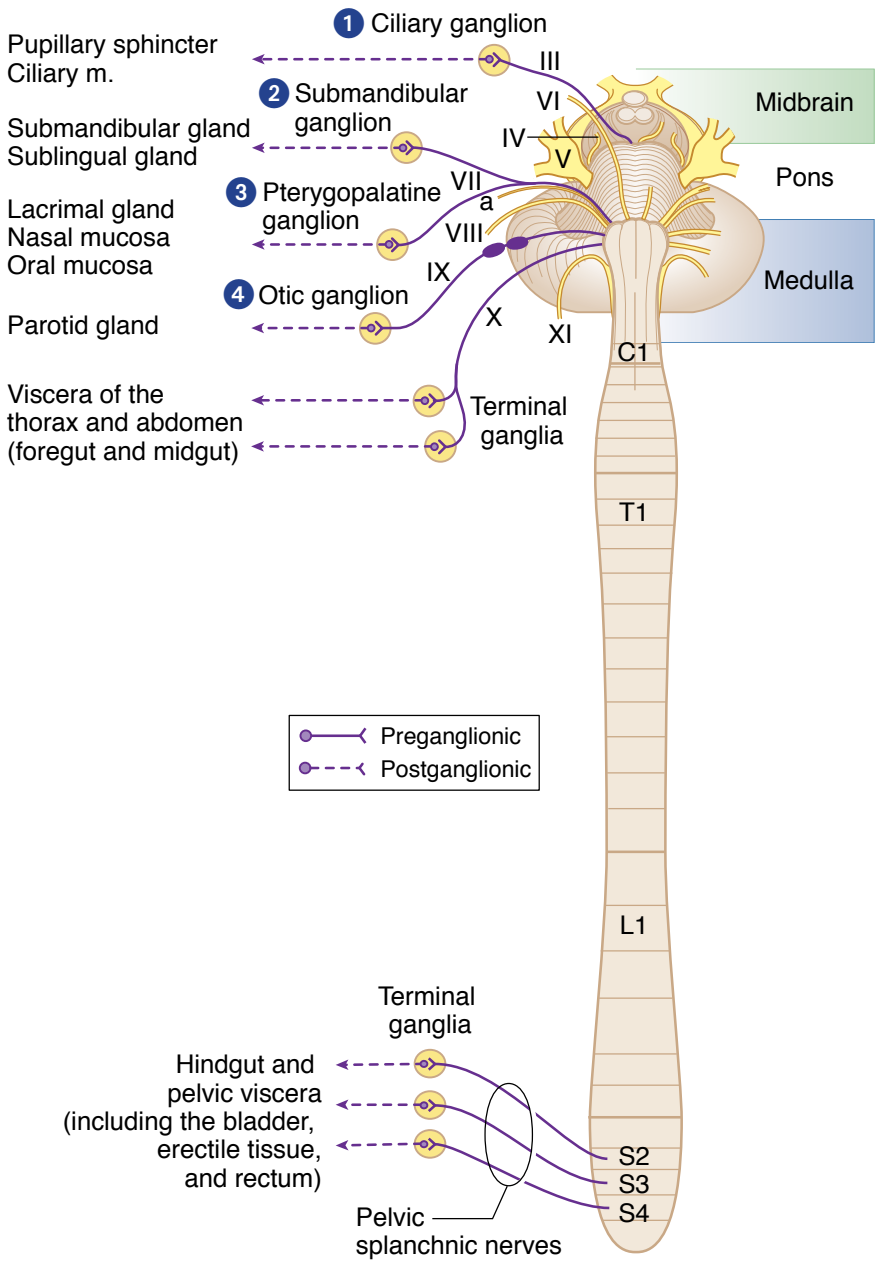

Figure III-1-5. Overview of Parasympathetic Outflow

Clinical Correlate

Hirschsprung's disease results from missing terminal ganglia in the wall of the rectum. Infants cannot pass meconium.

Table III-1-4. Parasympathetic = Craniosacral Outflow

Origin	Site of Synapse	Innervation
Cranial nerves III, VII, IX	Four cranial ganglia	Glands and smooth muscle of the head
Cranial nerve X	Terminal ganglia (in or near the walls of viscera)	Viscera of the neck, thorax, foregut, and midgut
Pelvic splanchnic nerves (S2, S3, S4)	Terminal ganglia (in or near the walls of viscera)	Hindgut and pelvic viscera (including bladder and erectile tissue)

Note

Horner's syndrome results in *ipsilateral* ptosis, miosis, anhydrosis.

Sympathetic Nervous System

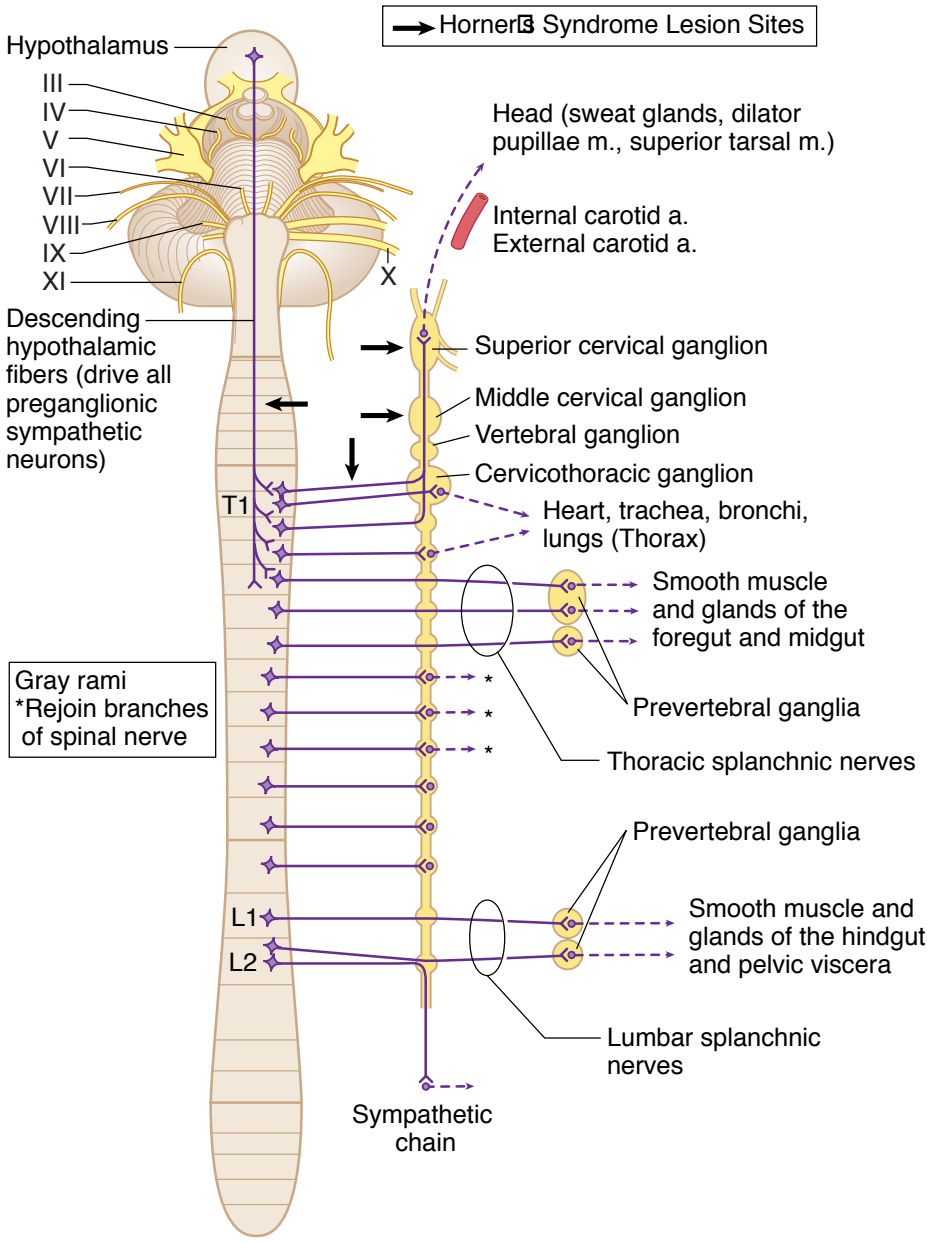

Figure III-1-6. Overview of Sympathetic Outflow

Table III-1-5. Sympathetic = Thoracolumbar Outflow

Origin	Site of Synapse	Innervation
Spinal cord levels T1–L2	Sympathetic chain ganglia (paravertebral ganglia)	Smooth muscle and glands of body wall and limbs; head and thoracic viscera
Thoracic splanchnic nerves T5–T12	Prevertebral ganglia (collateral; e.g., celiac, aorticorenal superior mesenteric ganglia)	Smooth muscle and glands of the foregut and midgut
Lumbar splanchnic nerves L1, L2	Prevertebral ganglia (collateral; e.g., inferior mesenteric and pelvic ganglia)	Smooth muscle and glands of the pelvic viscera and hindgut

Note

Gray rami are postganglionics that rejoin spinal nerves to go to the body wall.

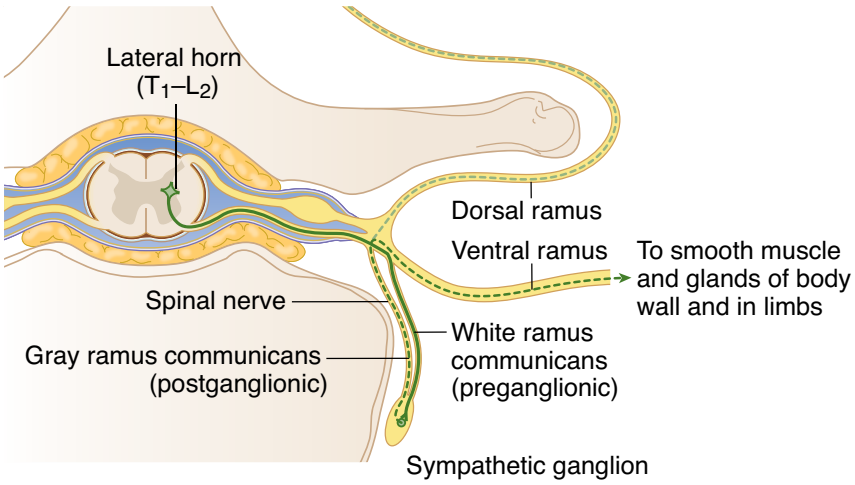

Figure III-1-7. Cross Section of Spinal Cord Showing Sympathetic Outflow

Histology of the Nervous System

2

Learning Objectives

- Explain information related to neurons
- Solve problems concerning disorders of myelination

NEURONS

Neurons are cells which are morphologically and functionally polarized so that information may pass from one end of the cell to the other. Neurons may be classified by the form and number of their processes as bipolar, unipolar, or multipolar. The cell body of the neuron contains the nucleus and membrane-bound cytoplasmic organelles typical of a eukaryotic cell, including endoplasmic reticulum (ER), Golgi apparatus, mitochondria, and lysosomes. The nucleus and nucleolus are prominent in neurons.

The cytoplasm contains Nissl substance, clumps of rough ER with bound polysomes. The cytoplasm also contains free polysomes; free and bound polysomes in the Nissl substance are sites of protein synthesis.

Multipolar Neuron

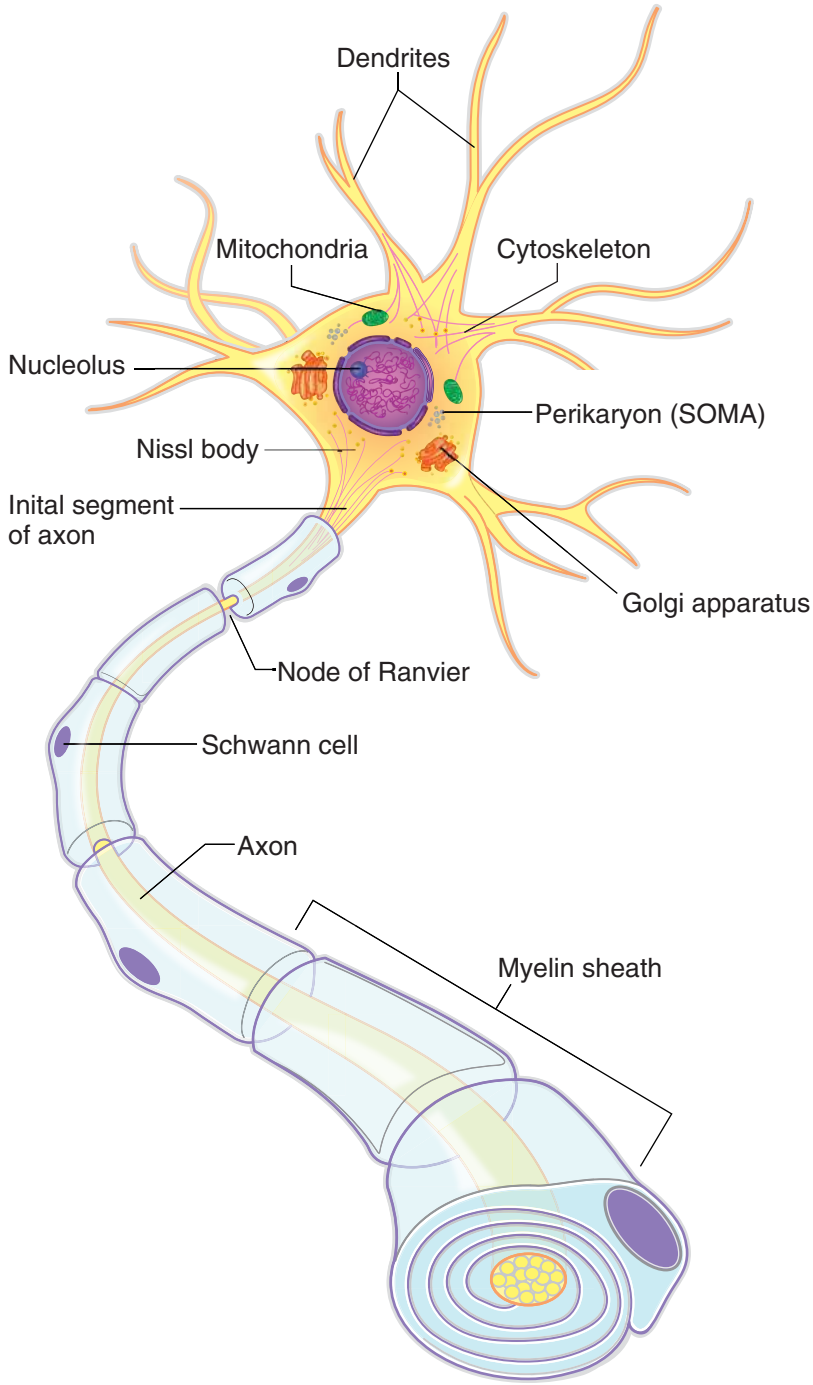

Figure III-2-1. Neuron Structure

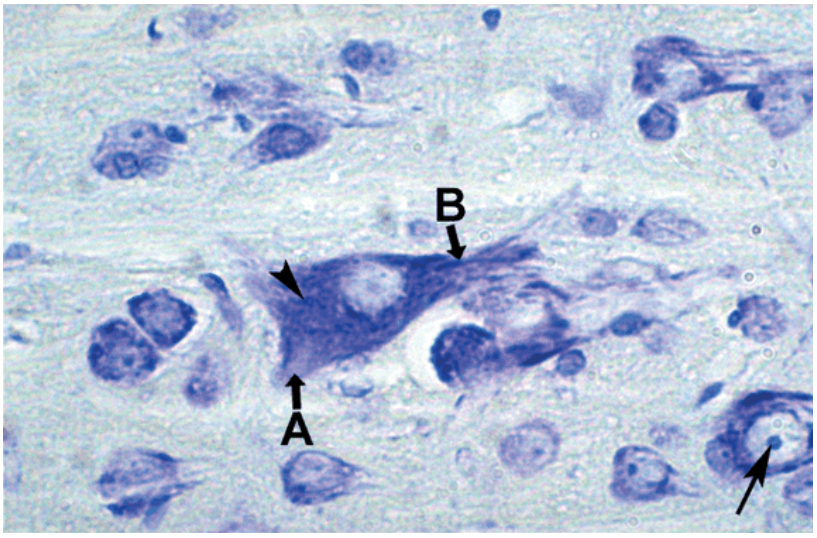

Copyright McGraw-Hill Companies. Used with permission.

Figure III-2-2. Neural Tissue with Nissl stain that stains rough ER in cell body (arrowhead) and proximal parts of dendrites (B)

The axon (A) lacks Nissl substance. The nucleus of an adjacent neuron has a prominent nucleolus (arrow).

Cytoskeleton

The **cytoskeleton of the neuron** consists of neurofilaments, microfilaments, and microtubules.

- **Neurofilaments** provide structural support for the neuron, and are most numerous in the axon and the proximal parts of dendrites.
- **Microfilaments** form a matrix near the periphery of the neuron. A microfilament matrix is prominent in growth cones of neuronal processes and functions to aid in the motility of growth cones during development. A microfilament matrix is also prominent in dendrites and forms structural specializations at synaptic membranes.
- **Microtubules** are found in all parts of the neuron, and are the cytoplasmic organelles used in axonal transport.

Clinical Correlate

CNS Disease and Cytoplasmic Inclusions in Neurons

Lewy bodies are cytoplasmic inclusions of degenerating neurons of the substantia nigra, pars compacta, evident in Parkinson's disease and in cortical and brain-stem neurons seen in certain forms of dementia.

Negri bodies are eosinophilic cytoplasmic inclusions seen in degenerating neurons in the hippocampus and cerebellar cortex in patients with rabies.

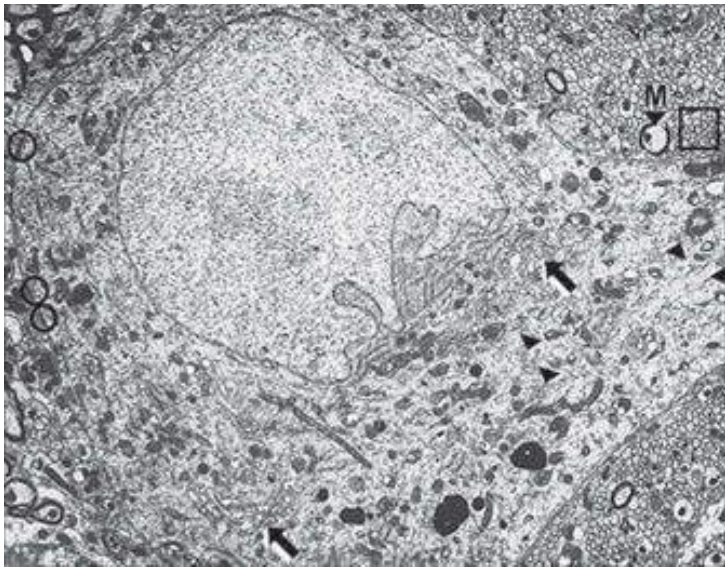

Copyright McGraw-Hill Companies. Used with permission.

Figure III-2-3. EM of Neuropil including Cell Body of a Neuron with Rough ER (arrowheads) and Golgi (arrows)

Surrounding neuropil has myelinated axons(M) and unmyelinated bare axons (box).

Clinical Correlate

In degenerative neuronal diseases of the CNS, a **tau protein** becomes excessively phosphorylated, which prevents crosslinking of microtubules. The affected microtubules form helical filaments and neurofibrillary tangles and senile plaques in the cell body and dendrites of neurons. **Neurofibrillary tangles** are prominent features of degenerating neurons in Alzheimer's disease, amyotrophic lateral sclerosis, and Down syndrome.

Dendrites taper from the cell body and provide the major surface for synaptic contacts with axons of other neurons. **Dendrites may contain spines**, which are small cytoplasmic extensions that dramatically increase the surface area of dendrites. Dendrites may be highly branched; the branching pattern of dendrites may be used to define a particular neuronal cell type.

The **axon** has a **uniform diameter and may branch at right angles into collaterals** along the length of the axon, in particular near its distal end. The proximal part of the axon is usually marked by an **axon hillock**, a tapered extension of the cell body that lacks Nissl substance.

The initial segment is adjacent to the axon hillock. The membrane of the initial segment contains numerous voltage-sensitive sodium ion channels. The initial segment is the "trigger zone" of an axon where conduction of electrical activity as an action potential is initiated.

If the axon is myelinated, the myelin sheath begins at the initial segment. The cytoplasm of the entire axon lacks free polysomes, Nissl substance, and Golgi apparatus but contains mitochondria and smooth ER.

Anterograde axonal transport moves proteins and membranes that are synthesized in the cell body through the axon to the synaptic terminal. In **fast anterograde transport**, there is a rapid (100–400 mm/day) movement of materials from the cell body to the axon terminal.

- Fast anterograde transport is dependent on **kinesin,** which acts as the motor molecule. Fast anterograde transport delivers precursors of peptide neurotransmitters to synaptic terminals.

- In **slow anterograde transport**, there is a slow (1–2 mm/day) anterograde movement of soluble cytoplasmic components. Cytoskeletal proteins, enzymes, and precursors of small molecule neurotransmitters are transported to synaptic terminals by slow anterograde transport. Slow transport is not dependent on microtubules or ATPase motor molecules.

Clinical Correlate

Neuropathies and Axonal Transport

- Disruption of fast anterograde transport may result in an axonal polyneuropathy. The cause may be anoxia (which affects mitochondrial oxidative phosphorylation) or anticancer agents e.g., colchicine and vinblastine (which depolymerize microtubules).
- In patients with diabetes, hyperglycemia results in an alteration of proteins that form microtubules, which may disrupt axonal transport. Patients may develop axonal polyneuropathies in long axons in nerves, producing a "glove-and-stocking" pattern of altered sensation and pain in the feet and then in the hands.

Retrograde axonal transport returns intracellular material from the synaptic terminal to the cell body to be recycled or digested by lysosomes.

Retrograde transport uses microtubules and is slower than anterograde transport (60–100 mm/day). It is dependent on dynein, an ATPase, which acts as the retrograde motor molecule. Retrograde transport also permits communication between the synaptic terminal and the cell body by transporting trophic factors emanating from the postsynaptic target or in the extracellular space.

Clinical Correlate

Retrograde Axonal Transport and Neurological Disorders

The polio, herpes, and rabies viruses and tetanus toxins are taken up and retrogradely transported by axons that innervate skeletal muscle.

Herpes is taken up and retrogradely transported in sensory fibers and remains dormant in sensory ganglia.

Glial and Supporting Cells in the CNS and PNS

The supporting (or glial) cells of the CNS are small cells that differ from neurons. Supporting cells have only one kind of process and do not form chemical synapses. Unlike neurons, they readily divide and proliferate; glioma is the most common type of primary tumor of the CNS.

Astrocytes are the **most numerous glial cells** in the CNS, and they have large numbers of radiating processes.

- They provide the structural support or scaffolding for the CNS and contain large bundles of intermediate filaments that consist of **glial fibrillary acidic protein** (GFAP).
- They have uptake systems which remove the neurotransmitter glutamate and K^+ ions from the extracellular space.
- They have foot processes which contribute to the blood–brain barrier by forming a glial-limiting membrane.
- They hypertrophy and proliferate after an injury to the CNS, filling up the extracellular space left by degenerating neurons by forming an astroglial scar.

Radial glia are precursors of astrocytes that guide neuroblast migration during CNS development.

Microglia cells are the **smallest glial cells** in the CNS. Unlike the rest of the CNS neurons and glia, which are derived from neuroectoderm, microglia are derived from bone marrow monocytes and enter the CNS after birth.

- They provide a link between cells of the CNS and the immune system.
- They proliferate and migrate to the site of a CNS injury and phagocytose neuronal debris after injury. Pericytes are microglia which contribute to the blood–brain barrier.
- They determine the chances of survival of a CNS tissue graft, and are the cells in the CNS that are targeted by the HIV-1 virus in those with AIDS. The affected microglia may produce cytokines that are toxic to neurons.

CNS microglia that become phagocytic in response to neuronal tissue damage may secrete toxic free radicals. Accumulation of free radicals, such as superoxide, may lead to disruption of the calcium homeostasis of neurons.

Oligodendrocytes form myelin for axons in the CNS. Each of the processes of the oligodendrocyte can myelinate individual segments of many axons. Unmyelinated axons in the CNS are not ensheathed by oligodendrocyte cytoplasm.

Schwann cells are the supporting cells of the peripheral nervous system (PNS), and are derived from neural crest cells. Schwann cells form the myelin for axons and processes in the PNS. Each Schwann cell forms myelin for only a single internodal segment of a single axon. Unmyelinated axons in the PNS are enveloped by the cytoplasmic processes of a Schwann cell. Schwann cells act as phagocytes and remove neuronal debris in the PNS after injury. A **node of Ranvier** is the region between adjacent myelinated segments of axons in the CNS and the PNS.

In all myelinated axons, nodes of Ranvier are sites that permit action potentials to jump from node to node (saltatory conduction). Saltatory conduction dramatically increases the conduction velocity of impulses in myelinated axons.

DISORDERS OF MYELINATION

Demyelinating diseases are acquired conditions involving selective damage to myelin. Other diseases (e.g., infectious, metabolic, inherited) can also affect myelin and are generally called leukodystrophies.

Table III-2-1. Conditions of Impaired Myelination

Disease	Symptoms	Notes
Multiple sclerosis (MS)	Symptoms separated in space and time Vision loss (optic neuritis) Internuclear ophthalmoplegia (MLF) Motor and sensory deficits Vertigo Neuropsychiatric	Occurs 2x more often in women Onset often in decades 3 or 4 Higher prevalence in temperate zones Relapsing–remitting course is most common Well-circumscribed demyelinated plaques often in periventricular areas Chronic inflammation; axons initially preserved Increased IgG (oligoclonal bands) in CSF Treatment: high-dose steroids, interferon-beta, glatiramer (Copaxone®)
Metachromatic leukodystrophy (MLD)	Four types; motor and cognitive issues with seizures	Arylsulfatase A deficiency in lysosomes affects both CNS and PNS myelin
Progressive multifocal leukoencephalopathy (PML)	Cortical myelin commonly affected; causes limb weakness, speech problems	Caused by JC virus Affects immunocompromised, especially AIDS Demyelination, astrogliosis, lymphohistiocytosis
Central pontine myelinolysis (CPM)	Pseudobulbar palsy Spastic quadriparesis Mental changes May produce the "locked-in" syndrome Often fatal	Focal demyelination of central area of basis pontis (affects corticospinal, corticobulbar tracts) Seen in severely malnourished, alcoholics, liver disease Probably caused by overly aggressive correction of hyponatremia
Guillain-Barré syndrome	Acute symmetric ascending inflammatory neuropathy of PNS myelin Weakness begins in lower limbs and ascends; respiratory failure can occur in severe cases Autonomic dysfunction may be prominent Cranial nerve involvement is common Sensory loss, pain, and paresthesias rarely occur Reflexes invariably decreased or absent	Two-thirds of patients have history of respiratory or GI illness 1–3 weeks prior to onset Elevated CSF protein with normal cell count (albuminocytologic dissociation)

Abbreviations: JC, John Cunningham; MLF, medial longitudinal fasciculus

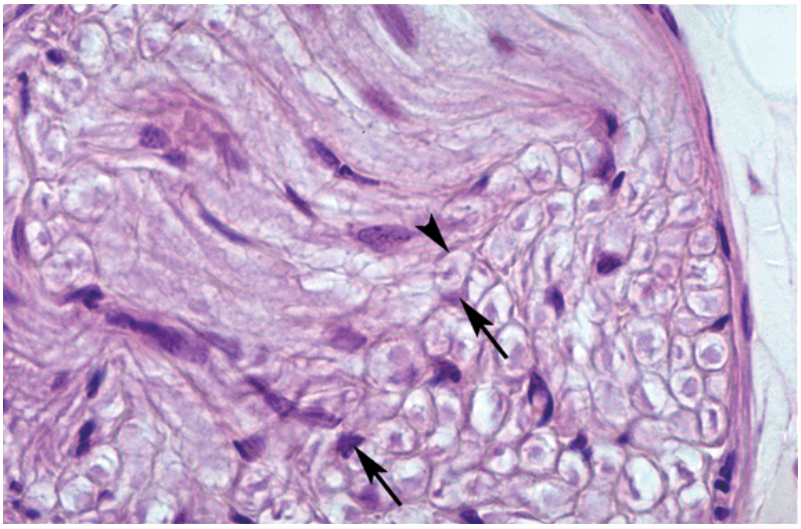

Copyright McGraw-Hill Companies. Used with permission.

Figure III-2-4. Section of a Peripheral Nerve

Note endoneurial border of an individual axon (arrowhead) and 2 Schwann cell nuclei (arrows)

From the IMC, ® 2010 DxR Development Group, Inc. All rights reserved.

Figure III-2-5. Axons Cut in Cross-Section

Ependymal cells line the ventricles in the adult brain. Some ependymal cells differentiate into choroid epithelial cells, forming part of the choroid plexus, which produces cerebrospinal fluid (CSF). Ependymal cells are ciliated; ciliary action helps circulate CSF.

Tanycytes are specialized ependymal cells that have basal cytoplasmic processes in contact with blood vessels; these processes may transport substances between a blood vessel and a ventricle.

Blood–Brain Barrier

The blood–brain barrier restricts access of micro-organisms, proteins, cells, and drugs to the nervous system. It consists of capillary endothelial cells, an underlying basal lamina, astrocytes, and pericytes.

- The most important elements of the blood-brain barrier are the **cerebral capillary endothelial cells** and their **intercellular tight junctions**.
- Astrocytes and pericytes are found at the blood–brain barrier outside the basal lamina. Astrocytes have processes with "end feet" that cover >95% of the basal lamina adjacent to the capillary endothelial cells.

Substances cross the blood–brain barrier into the CNS by **diffusion, by selective transport, and via ion channels.** Oxygen and carbon dioxide are lipid-soluble gases that readily diffuse across the blood–brain barrier. Glucose, amino acids, and vitamins K and D are selectively transported across the blood–brain barrier. Sodium and potassium ions move across the blood–brain barrier through ion channels.

Clinical Correlate

Drugs of addiction—heroin, ethanol, and nicotine—are lipid-soluble compounds that readily diffuse across the blood–brain barrier.

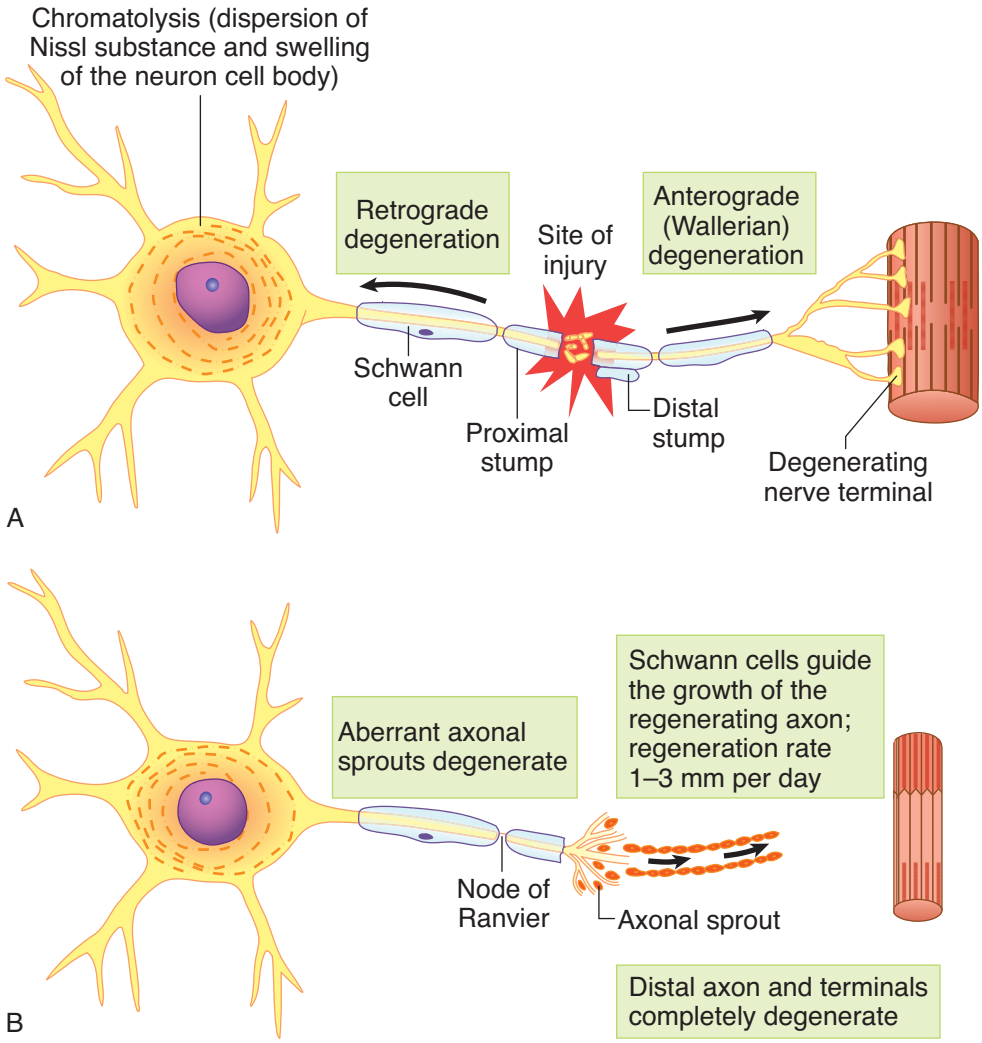

Figure III-2-6. Neuron Undergoing Axotomy, Chromatolysis, and Regeneration in the PNS

Response of Axons to Destructive Lesions (Severing an Axon or Axotomy) or Irritative Lesions (Compression of an Axon)

Anterograde or Wallerian degeneration distal to the cut occurs when an axon is severed in either the CNS or PNS. The closer the destructive lesion is to the neuronal cell body, the more likely the neuron is to die. In the PNS, anterograde degeneration of axons is rapid and complete after several weeks. In the PNS, the endoneurial Schwann cell sheath that envelops a degenerating axon does not degenerate and provides a scaffold for regeneration and remyelination of the axon.

Clinical Correlate

Schwannomas typically affect VIII nerve fibers seen in neurofibromatosis type 2.

Neurons with severed axons in the PNS are capable of complete axonal regeneration. Successful sprouts from the cut axon grow into and through endoneurial sheaths and are guided by Schwann cells back to their targets. Regeneration proceeds at the rate of 1–2 mm/day, which corresponds to the rate of slow anterograde transport.

Half of brain and spinal cord tumors are metastatic.

Table III-2-2. Primary Tumors

Tumor	Features	Pathology
Glioblastoma multiforme (grade IV astrocytoma)	**Most common primary brain tumor** • **Highly malignant** • Usually lethal in 8–12 months	• Can cross the midline via the corpus callosum (**"butterfly glioma"**) • Areas of necrosis surrounded by rows of neoplastic cells (**pseudopalisading necrosis**)
Astrocytoma (pilocytic)	• Benign tumor of children and young adults • Usually in **posterior fossa in children**	• **Rosenthal fibers** • Immunostaining with **GFAP**
Oligodendroglioma	• Slow growing • Long survival (average 5–10 years)	• **"Fried-egg" appearance**—perinuclear halo
Ependymoma	• Ependymal origin • Can arise in IV ventricle and lead to **hydrocephalus**	• Rosettes and pseudorosettes
Medulloblastoma	• Highly malignant cerebellar tumor • A type of primitive neuroectodermal tumor (PNET)	• Blue, small, round cells with pseudorosettes
Meningioma	• Second most common primary brain tumor • Dural convexities; parasagittal region	• Attaches to the dura, compresses underlying brain without invasion • Microscopic—**psammoma bodies**
Schwannoma	• Third most common primary brain tumor • Most frequent location: **CN VIII at cerebellopontine angle** • **Hearing loss, tinnitus, CN V + VII signs** • Good prognosis after surgical resection	• Antoni A (hypercellular) and B (hypocellular) areas • **Bilateral acoustic schwannomas—pathognomonic for neurofibromatosis type 2**
Retinoblastoma	• Sporadic—unilateral • **Familial—bilateral; associated with osteosarcoma**	• Small, round, blue cells; may have rosettes
Craniopharyngioma	• Derived from oral epithelium (remnants of **Rathke pouch**) • Usually children and young adults • Often calcified • Symptoms due to encroachment on pituitary stalk or **optic chiasm** • Benign but may recur	• Histology resembles **adamantinoma** (most common tumor of tooth)

Abbreviation: GFAP, glial fibrillary acidic protein

Ventricular System 3

Learning Objectives

- ❑ Demonstrate understanding of ventricular system and venous drainage
- ❑ Explain information related to CSF distribution, secretion, and circulation

The brain and spinal cord float within a protective bath of cerebrospinal fluid (CSF), which is produced continuously by the choroid plexus within the ventricles of the brain.

Each part of the CNS contains a component of the ventricular system. There are 4 interconnected ventricles in the brain: 2 lateral ventricles, a third ventricle, and a fourth ventricle.

- A lateral ventricle is located deep within each cerebral hemisphere. Each lateral ventricle communicates with the third ventricle via an interventricular foramen (foramen of Monro).
- The third ventricle is found in the midline within the diencephalon and communicates with the fourth ventricle via the cerebral aqueduct (of Sylvius), which passes through the midbrain.
- The fourth ventricle is located between the dorsal surfaces of the pons and upper medulla and the ventral surface of the cerebellum. The fourth ventricle is continuous with the central canal of the lower medulla and spinal cord.

Note

Choroid plexus secretes CSF into all ventricles. Arachnoid granulations are sites of CSF resorption.

VENTRICULAR SYSTEM AND VENOUS DRAINAGE

The brain and spinal cord float within a protective bath of CSF, which is produced by the lining of the ventricles, the choroid plexus. CSF circulation begins in the ventricles and then enters the subarachnoid space to surround the brain and spinal cord.

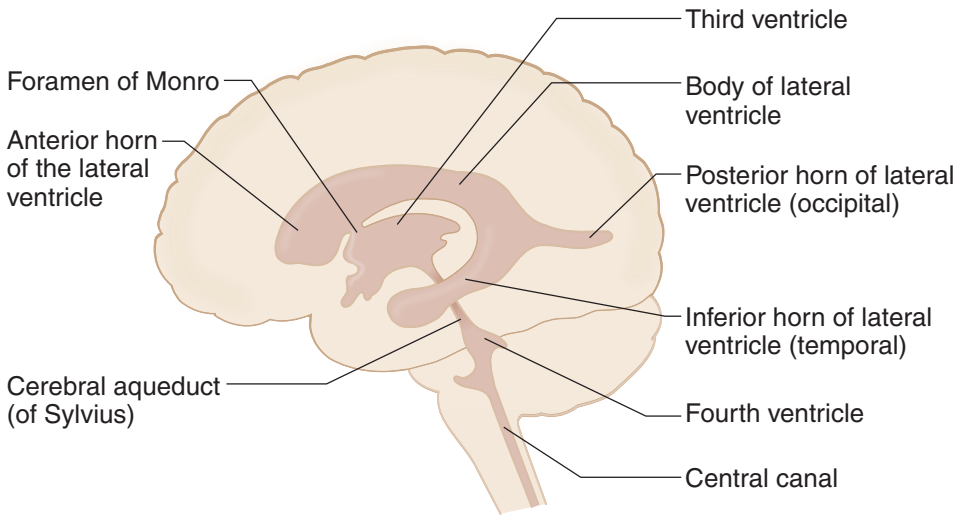

Figure III-3-1. Ventricles and CSF Circulation

Note

A total of 400–500 cc of CSF is produced per day; ventricles and subarachnoid space contain 90–150 cc, so all of CSF is turned over 2–3 times per day.

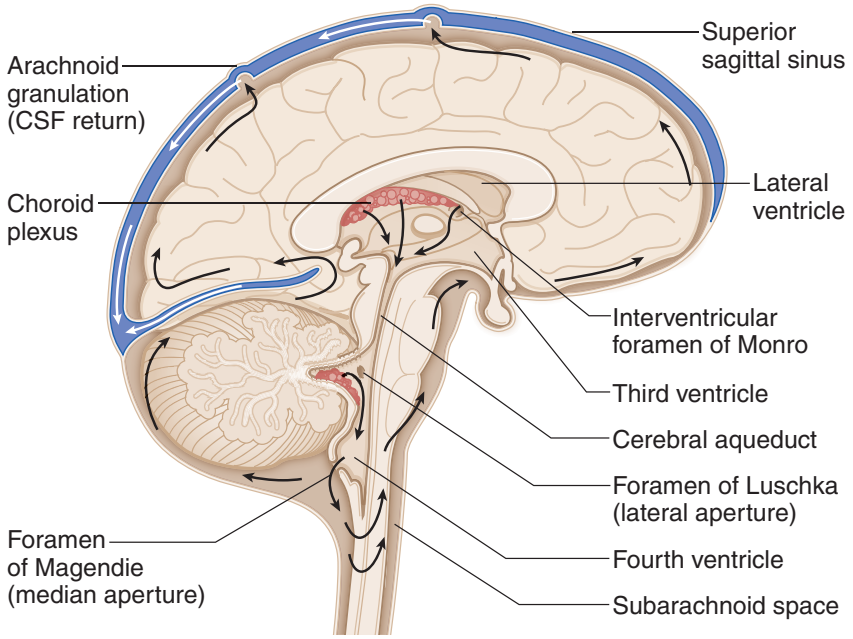

Figure III-3-2. Sagittal Section of the Brain

Lateral ventricles $\xrightarrow{\text{interventricular foramen of Monro}}$ third ventricle $\xrightarrow{\text{cerebral aqueduct}}$ fourth ventricle → subarachnoid space (via foramina of Luschka and foramen of Magendie)

CSF Production and Barriers

Choroid plexus—contains **choroid epithelial cells** and is in the lateral, third, and fourth ventricles. **Secretes CSF.** Tight junctions form **blood-CSF barrier**.

Blood-brain barrier—formed by capillary endothelium with tight junctions; astrocyte foot processes contribute.

Once CSF is in the subarachnoid space, it goes up over convexity of the brain and enters the venous circulation by passing through **arachnoid granulations** into **dural venous sinuses**.

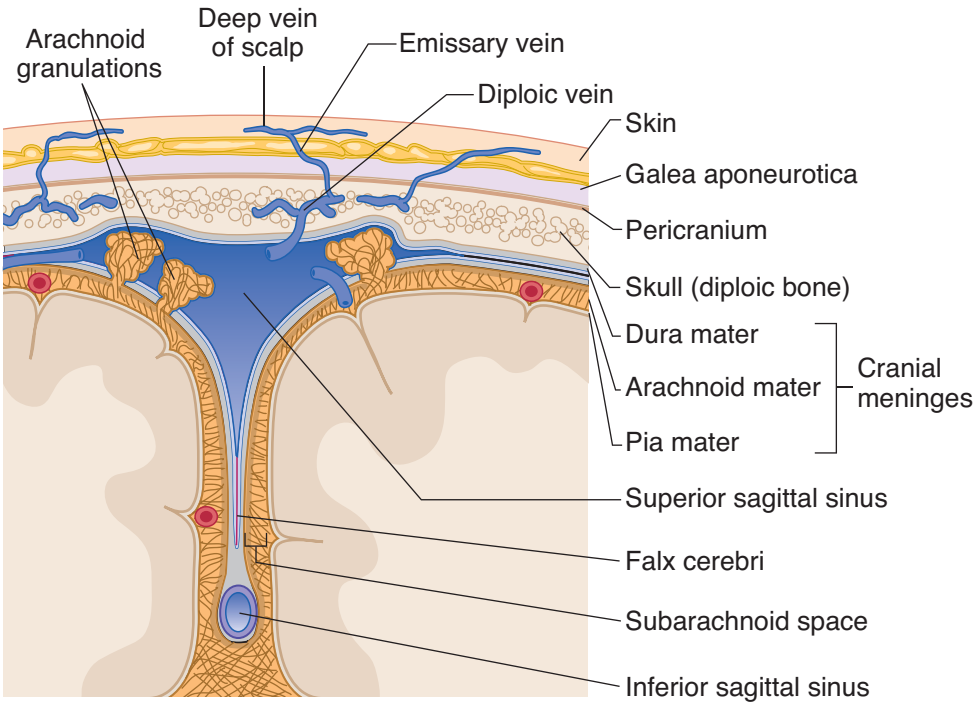

Figure III-3-3. Coronal Section of the Dural Sinuses

Sinuses

Superior sagittal sinus (in superior margin of falx cerebri)—drains into 2 **transverse sinuses**. Each of these drains blood from the **confluence of sinuses** into **sigmoid sinuses**. Each sigmoid sinus exits the skull (via **jugular foramen**) as the **internal jugular veins**.

Inferior sagittal sinus (in inferior margin of falx cerebri)— terminates by joining with the great cerebral vein of Galen to form the **straight sinus** at the falx cerebri and tentorium cerebelli junction. This drains into the confluence of sinuses.

Cavernous sinus—a plexus of veins on either side of the **sella turcica**. Surrounds internal carotid artery and cranial nerves III, IV, V, and VI. It drains into the transverse sinus (via the **superior petrosal sinus**) and the internal jugular vein (via the **inferior petrosal sinus**).

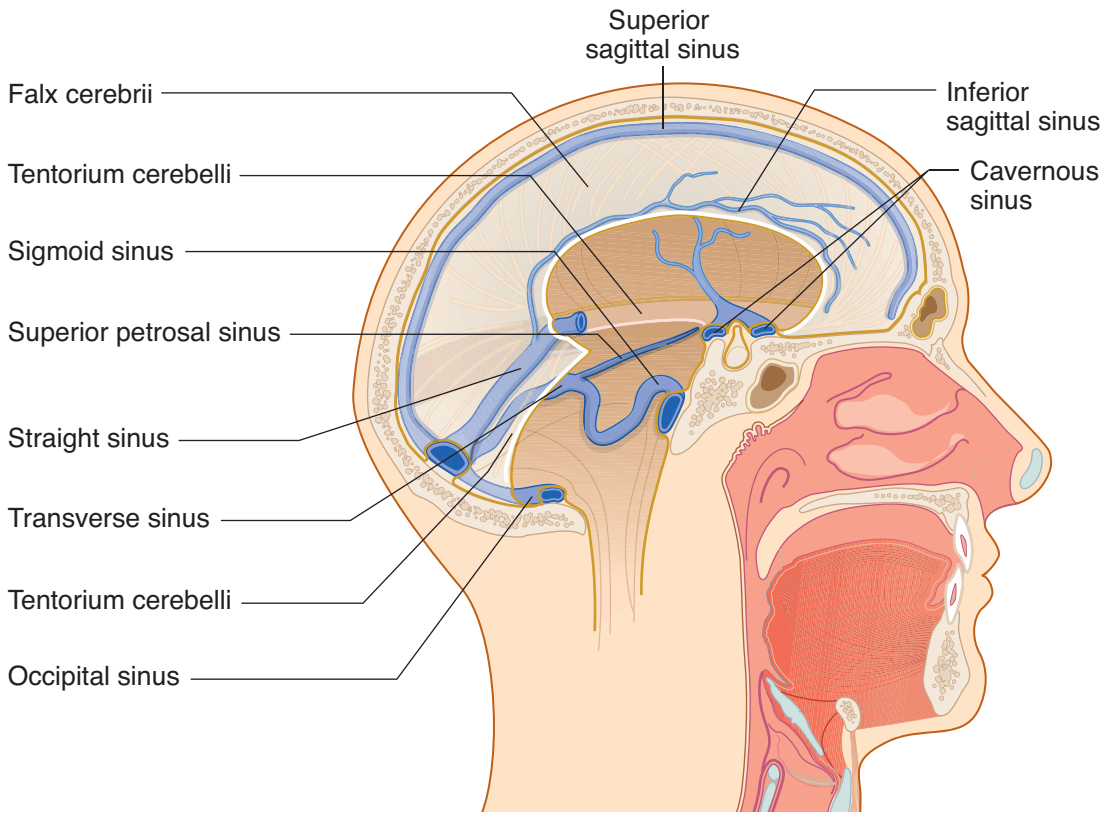

Figure III-3-4. Dural Venous Sinuses

Hydrocephalus

Excess volume or pressure of CSF, leading to dilated ventricles

Table III-3-1. Types and Features of Hydrocephalus

Type of Hydrocephalus	Description
Noncommunicating	**Obstruction of flow within ventricles;** most commonly occurs at narrow points, e.g., foramen of Monro, cerebral aqueduct and/or openings of fourth ventricle
Communicating	**Impaired CSF reabsorption** in arachnoid granulations or obstruction of flow in subarachnoid space
Normal pressure (chronic)	CSF is not absorbed by arachnoid villi (a form of communicating hydrocephalus). CSF pressure is usually normal. Ventricles chronically dilated. Produces **triad** of **dementia, apraxic (magnetic) gait,** and **urinary incontinence.** Peritoneal shunt.
Ex vacuo	Descriptive term referring to excess CSF in regions where brain tissue is lost due to atrophy, stroke, surgery, trauma, etc. Results in dilated ventricles but normal CSF pressure.

CSF DISTRIBUTION, SECRETION, AND CIRCULATION

CSF fills the subarachnoid space and the ventricles of the brain. The average adult has 90–150 mL of total CSF, although 400–500 mL is produced daily. Only 25 mL of CSF is found in the ventricles themselves.

Approximately 70% of the CSF is secreted by the choroid plexus, which consists of glomerular tufts of capillaries covered by ependymal cells that project into the ventricles (the remaining 30% represents metabolic water production). The choroid plexus is located in parts of each lateral ventricle, the third ventricle, and the fourth ventricle.

CSF from the lateral ventricles passes through the interventricular foramina of Monro into the third ventricle. From there, CSF flows through the aqueduct of Sylvius into the fourth ventricle. The only sites where CSF can leave the ventricles and enter the subarachnoid space outside the CNS are through 3 openings in the fourth ventricle, 2 lateral foramina of Luschka and the median foramen of Magendie.

Within the subarachnoid space, CSF also flows up over the convexity of the brain and around the spinal cord. Almost all CSF returns to the venous system by draining through arachnoid granulations into the superior sagittal dural venous sinus.

- Normal CSF is a **clear** fluid, isotonic with serum (290–295 mOsm/L).
- The pH of CSF is 7.33 (arterial blood pH, 7.40; venous blood pH, 7.36).
- Sodium ion (Na^+) concentration is equal in serum and CSF (≈138 mEq/L).
- CSF has a higher concentration of chloride (Cl^-) and magnesium (Mg^{2+}) ions than does serum.
- CSF has a lower concentration of potassium (K^+), calcium (Ca^{2+}), and bicarbonate (HCO_3^-) ions, as well as glucose, than does serum.

The **blood–CSF barrier** is a mechanism which protects the chemical integrity of the brain. Tight junctions located along the epithelial cells of the choroid plexus form the blood–CSF barrier. Transport systems are similar but not identical to the those of blood–brain barrier. The ability of a substance (drug) to enter the CSF does not guarantee it will gain access to the brain.

Clinical Correlate

The concentration of protein (including all immunoglobulins) is much lower in the CSF as compared with serum.

Normal CSF contains 0–4 lymphocytes or mononuclear cells per cubic millimeter. Although the presence of a few monocytes or lymphocytes is normal, the presence of polymorphonuclear leukocytes is always abnormal, as in bacterial meningitis.

- Red blood cells are not normally found in the CSF but may be present after traumatic spinal tap or subarachnoid hemorrhage.
- Increased protein levels may indicate a CNS tumor.
- Tumor cells may be present in the CSF in cases with meningeal involvement.

The Spinal Cord 4

Learning Objectives

- Solve problems concerning general features
- Interpret scenarios on neural systems

GENERAL FEATURES

The spinal cord is housed in the vertebral canal. It is continuous with the medulla below the pyramidal decussation and terminates as the conus medullaris at the second lumbar vertebra of the adult. The roots of 31 pairs of spinal nerves arise segmentally from the spinal cord.

There are **8 cervical pairs** of spinal nerves (C1 through C8). The cervical enlargement (C5 through T1) gives rise to the rootlets that form the brachial plexus, which innervates the upper limbs.

There are **12 thoracic pairs** of spinal nerves (T1 through T12). Spinal nerves emanating from thoracic levels innervate most of the trunk.

There are **5 lumbar pairs** of spinal nerves (L1 through L5). The lumbar enlargement (L2 through S3) gives rise to rootlets that form the lumbar and sacral plexuses, which innervate the lower limbs.

There are **5 sacral pairs** of spinal nerves (S1 through S5). Spinal nerves at the sacral level innervate part of the lower limbs and the pelvis.

There is **1 coccygeal pair** of spinal nerves. The cauda equina consists of the dorsal and ventral roots of the lumbar, sacral, and coccygeal spinal nerves.

Inside the spinal cord, gray matter is centrally located and shaped like a butterfly. It contains neuronal cell bodies, their dendrites, and the proximal parts of axons. White matter surrounds the gray matter on all sides. White matter contains bundles of functionally similar axons called tracts or fasciculi, which ascend or descend in the spinal cord.

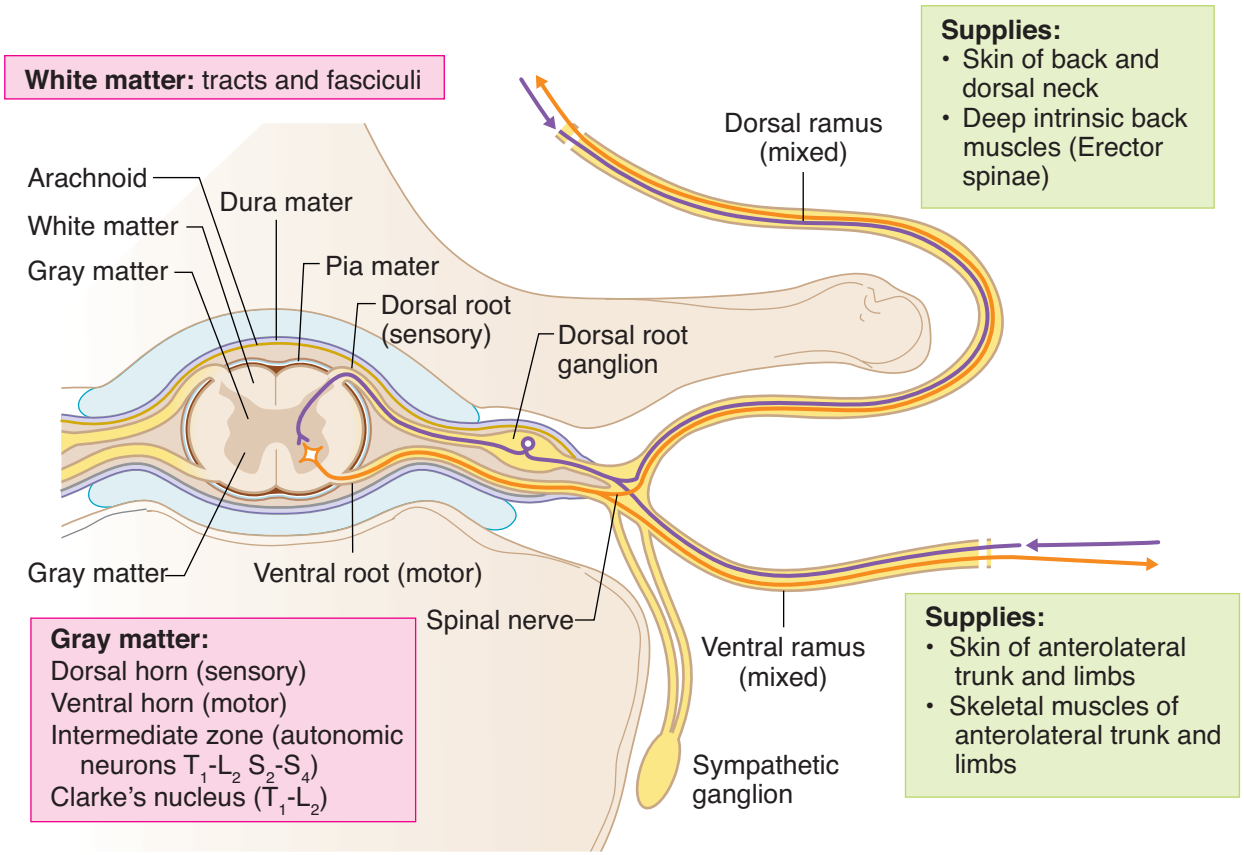

Figure III-4-1. Cross Section of Spinal Cord and Parts of Spinal Nerve

Table III-4-1. General Spinal Cord Features

Conus medullaris	Caudal end of the spinal cord (S3–S5). In adult, ends at the L2 vertebra
Cauda equina	Nerve roots of the lumbar, sacral, and coccygeal spinal nerves
Filum terminale	Slender pial extension that tethers the spinal cord to the bottom of the vertebral column
Doral root ganglia	Cell bodies of primary sensory neurons
Dorsal and ventral roots	Each segment has a pair
Dorsal horn	**Sensory neurons**
Ventral horn	**Motor neurons**
Spinal nerve	Formed from dorsal and ventral roots (mixed nerve)
Cervical enlargement	(C5–T1) → branchial plexus → upper limbs
Lumbar enlargement	(L2–S3) → lumbar and sacral plexuses → lower limbs

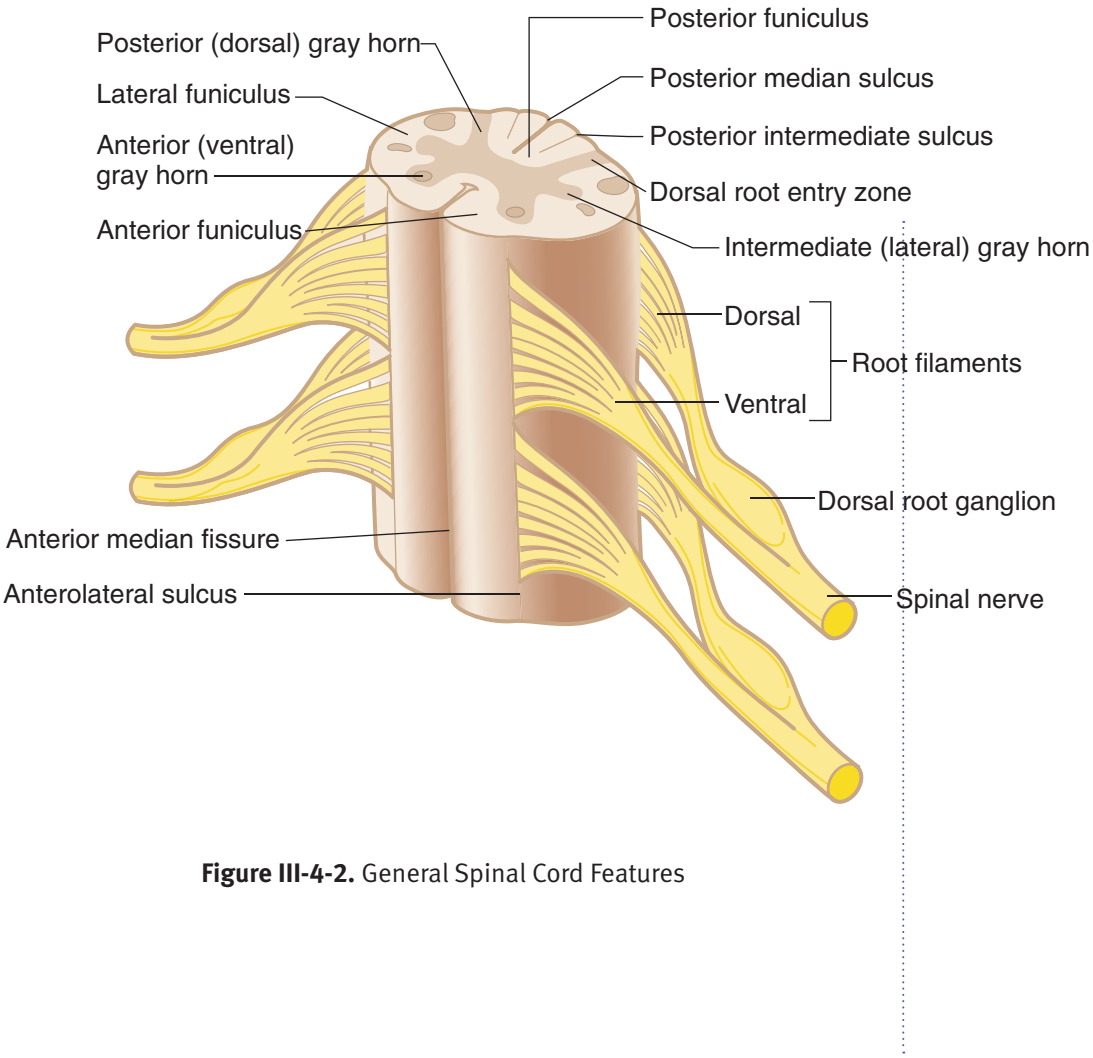

Figure III-4-2. General Spinal Cord Features

Dorsal Horn

The dorsal horn is dominated by neurons that respond to sensory stimulation. All incoming sensory fibers in spinal nerves enter the dorsolateral part of the cord adjacent to the dorsal horn in a dorsal root. Neurons in the dorsal horn project to higher levels of the CNS to carry sensations to the brain stem, cerebral cortex, or cerebellum. Other dorsal horn neurons participate in reflexes.

Dorsal horn: rexed laminae I–VI

Ventral horn: rexed laminae VIII–IX

Intermediate zone: lamina VII

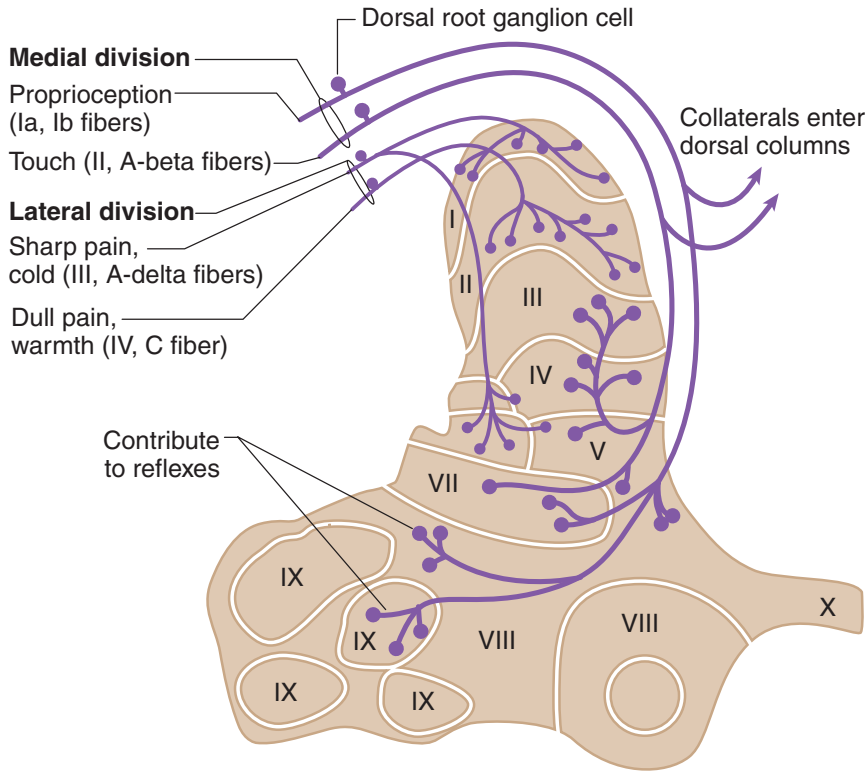

Figure III-4-3. Fiber Types in Dorsal Roots and Sites of Termination in the Spinal Cord Gray Matter

Ventral Horn

The ventral horn contains **alpha and gamma motoneurons**. The alpha motoneurons innervate skeletal muscle (extrafusal fibers) by way of a specialized synapse at a neuromuscular junction, and the gamma motoneurons innervate the contractile intrafusal muscle fibers of the muscle spindle. Within the ventral horn, alpha and gamma motoneurons that innervate flexors are dorsal to those that innervate extensors. Alpha and gamma motoneurons that innervate the proximal musculature are medial to those that innervate the distal musculature. Axons of alpha and gamma motoneurons and axons of preganglionic autonomic neurons leave the cord by way of a ventral root.

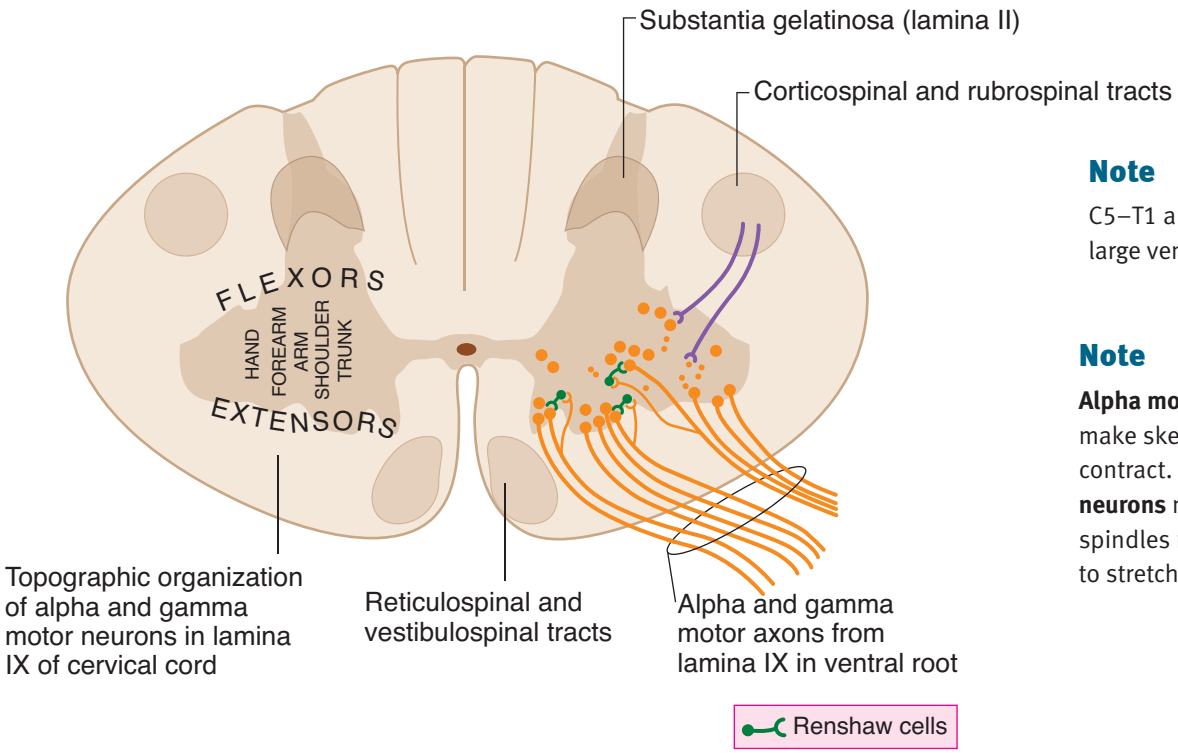

Figure III-4-4. Topographic Organization of Alpha and Gamma Motoneurons (LMNs) in Lamina IX

Note

C5–T1 and L2–S3 have large ventral horn.

Note

Alpha motor neurons make skeletal muscles contract. **Gamma motor neurons** make muscle spindles more sensitive to stretch.

Intermediate Zone

The intermediate zone of the spinal cord from T1 to L2 contains preganglionic sympathetic neuron cell bodies and Clarke nucleus, which sends unconscious proprioception to the cerebellum.

NEURAL SYSTEMS

There are 3 major neural systems in the spinal cord that use neurons in the gray matter and tracts or fasciculi of axons in the white matter. These neural systems have components which can be found at all levels of the CNS, from the cerebral cortex to the tip of the spinal cord. A knowledge of these 3 neural systems is essential to understanding the effects of lesions in the spinal cord and brain stem, and at higher levels of the CNS.

Motor System

Voluntary innervation of skeletal muscle

Upper and Lower Motoneurons

Two motoneurons, an upper motoneuron and a lower motoneuron, together form the basic neural circuit involved in the voluntary contraction of skeletal muscle everywhere in the body. **The lower motoneurons are found in the ventral horn of the spinal cord** and in **cranial nerve nuclei in the brain stem**.

Note

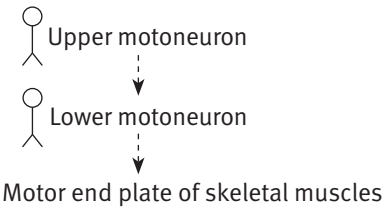

Axons of lower motoneurons of spinal nerves exit in a ventral root, then join the spinal nerve to course in one of its branches to reach and synapse directly at a neuromuscular junction in skeletal muscle. Axons of lower motoneurons in the brain stem exit in a cranial nerve.

To initiate a voluntary contraction of skeletal muscle, a lower motoneuron must be innervated by an upper motoneuron. The **cell bodies of upper motoneurons are found in the brain stem and cerebral cortex**, and their axons descend into the spinal cord in a tract to reach and synapse on lower motoneurons, or on interneurons, which then synapse on lower motoneurons. At a minimum, therefore, to initiate a voluntary contraction of skeletal muscle, 2 motoneurons, an upper and a lower, must be involved. The upper motoneuron innervates the lower motoneuron, and the lower motoneuron innervates the skeletal muscle.

The cell bodies of upper motoneurons are found in the red nucleus, reticular formation, and lateral vestibular nuclei of the brain stem, but the **most important location of upper motoneurons** is in the **cerebral cortex**. Axons of these cortical neurons course in the **corticospinal tract**.

Note

UMNs have net inhibitory effect on muscle stretch reflexes.

Note

Voluntary contraction: UMN → LMN

Reflect contraction: muscle sensory neuron → LMN

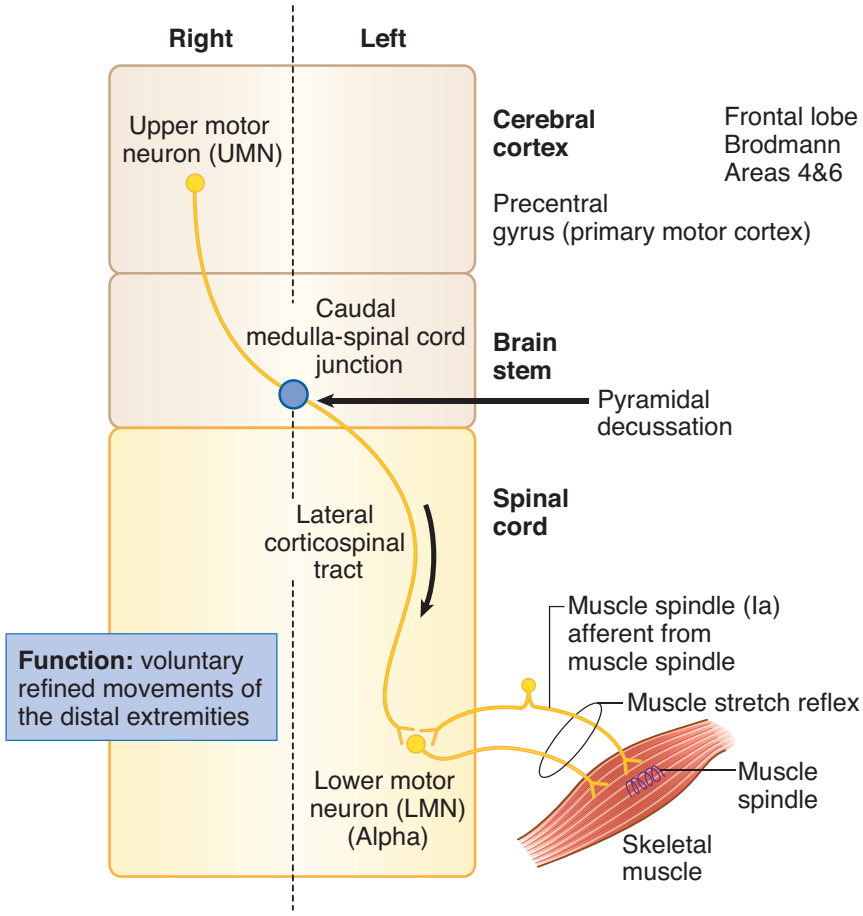

Figure III-4-5. Voluntary Contraction of Skeletal Muscle: UMN and LMNs

Corticospinal Tract

The primary motor cortex, located in the precentral gyrus of the frontal lobe, and the premotor area, located immediately anterior to the primary motor cortex, give rise to about 60% of the fibers of the corticospinal tract (Figure III-4-4). Primary and secondary somatosensory cortical areas located in the parietal lobe give rise to about 40% of the fibers of the corticospinal tract.

Fibers in the corticospinal tract leave the cerebral cortex in the internal capsule, which carries all axons in and out of the cortex. Corticospinal fibers then descend through the length of the brain stem in the ventral portion of the midbrain, pons, and medulla.

In the lower medulla, 80–90% of corticospinal fibers cross at the decussation of the pyramids and continue in the contralateral spinal cord as the lateral corticospinal tract. The lateral corticospinal tract descends the full length of the cord in the lateral part of the white matter. As it descends, axons leave the tract and enter the gray matter of the ventral horn to synapse on lower motoneurons.

Clinical Correlate

Lesions of the Corticospinal Tract

The crossing or decussation of axons of the corticospinal tract at the medulla/spinal cord junction has significant clinical implications. If lesions of the corticospinal tract occur above the pyramidal decussation, a weakness is seen in muscles on the contralateral side of the body; lesions below this level produce an ipsilateral muscle weakness. In contrast to upper motoneurons, the cell bodies of lower motoneurons are ipsilateral to the skeletal muscles that their axons innervate. A lesion to any part of a lower motoneuron will result in an ipsilateral muscle weakness at the level of the lesion.

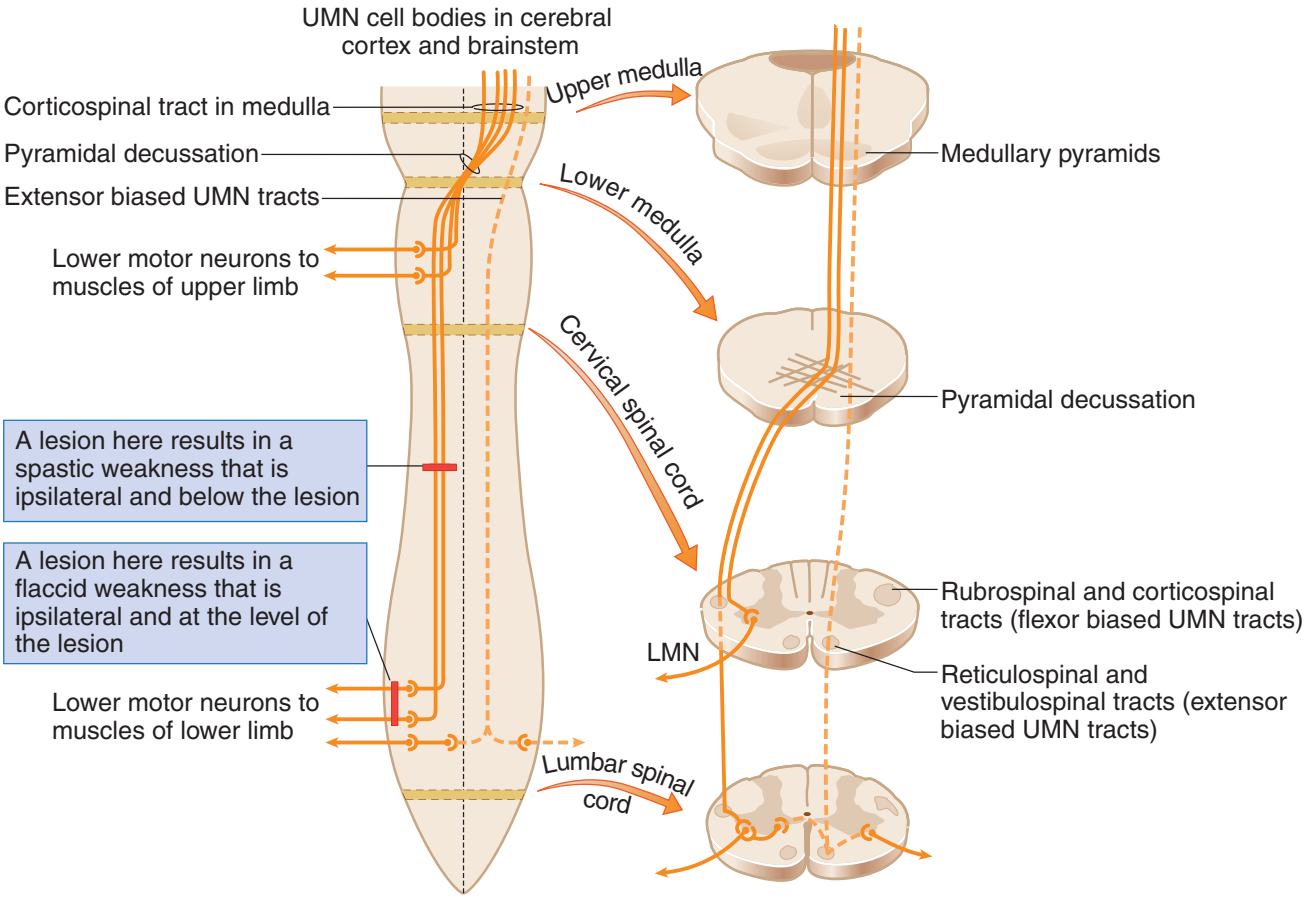

Figure III-4-6. Course of Axons of Upper Motor Neurons in the Medulla and Spinal Cord with Representative Cross-Sections

Reflex innervation of skeletal muscle

A reflex is initiated by a stimulus of a sensory neuron, which in turn innervates a motoneuron and produces a motor response. In reflexes involving skeletal muscles, the sensory stimulus arises from receptors in the muscle, and the motor response is a contraction or relaxation of one or more skeletal muscles. In the spinal cord, lower motoneurons form the specific motor component of skeletal muscle reflexes. **Upper motoneurons provide descending control over the reflexes.**

Both alpha and gamma motoneurons are lower motoneurons that participate in reflexes.

- Alpha motoneurons are large cells in the ventral horn that innervate extrafusal muscle fibers. A single alpha motoneuron innervates a group of muscle fibers, which constitutes a motor unit, the basic unit for voluntary, postural, and reflex activity.
- Gamma motoneurons supply intrafusal muscle fibers, which are modified skeletal muscle fibers. The intrafusal muscle fibers form the muscle spindle, which acts as a sensory receptor in skeletal muscle stretch reflexes.

Both ends of the muscle spindle are connected in parallel with the extrafusal fibers, so these receptors monitor the length and rate of change in length of extrafusal fibers. Muscles involved with fine movements contain a greater density of spindles than those used in coarse movements.

Commonly tested muscle stretch reflexes

The **deep tendon (stretch, myotatic) reflex** is monosynaptic and ipsilateral. The **afferent limb** consists of a **muscle spindle, Ia sensory neuron,** and **efferent limb (lower motor neuron)**. These reflexes are useful in the clinical exam.

Reflex	Cord Segment Involved	Muscle Tested
Knee (patellar)	L2–L4 (femoral n.)	Quadriceps
Ankle	S1 (tibial n.)	Gastrocnemius
Elbow	C5–C6 (musculocutaneous n.)	Biceps
Elbow	C7–C8 (radial n.)	Triceps
Forearm	C5–C6 (radial n.)	Brachioradialis

Muscle stretch (myotatic) reflex

The muscle stretch (myotatic) reflex is the stereotyped contraction of a muscle in response to stretch of that muscle. **The stretch reflex is a basic reflex that occurs in all muscles and is the primary mechanism for regulating muscle tone.** Muscle tone is the tension present in all resting muscle. Tension is controlled by the stretch reflexes.

The best example of a muscle stretch or deep tendon reflex is the knee-jerk reflex. Tapping the patellar ligament stretches the quadriceps muscle and its muscle spindles. Stretch of the spindles activates sensory endings (Ia afferents),

and afferent impulses are transmitted to the cord. Some impulses from stretch receptors carried by Ia fibers monosynaptically stimulate the alpha motoneurons that supply the quadriceps. This causes contraction of the muscle and a sudden extension of the leg at the knee. Afferent impulses simultaneously inhibit antagonist muscles through interneurons (in this case, hamstrings).

Inverse muscle stretch reflex

The inverse muscle stretch reflex monitors muscle tension. This reflex uses Golgi tendon organs (GTOs). These are encapsulated groups of nerve endings that terminate between collagenous tendon fibers at the junction of muscle and tendon. GTOs are oriented in series with the extrafusal fibers and respond to increases in force or tension generated in that muscle. Increases in force in a muscle increase the firing rate of Ib afferent neurons that innervate the GTOs, which, in turn, polysynaptically facilitate antagonists and inhibit agonist muscles.

Muscle tone and reflex activity can be influenced by **gamma motoneurons** and by upper motoneurons. Gamma motoneurons directly innervate the muscle spindles and regulate their sensitivity to stretch. Upper motoneurons innervate gamma motoneurons and also influence the sensitivity of muscle spindles to stretch. Stimulation of gamma motoneurons causes intrafusal muscle fibers located at the pole of each muscle spindle to contract, which activates alpha motoneurons, causing an increase in muscle tone.

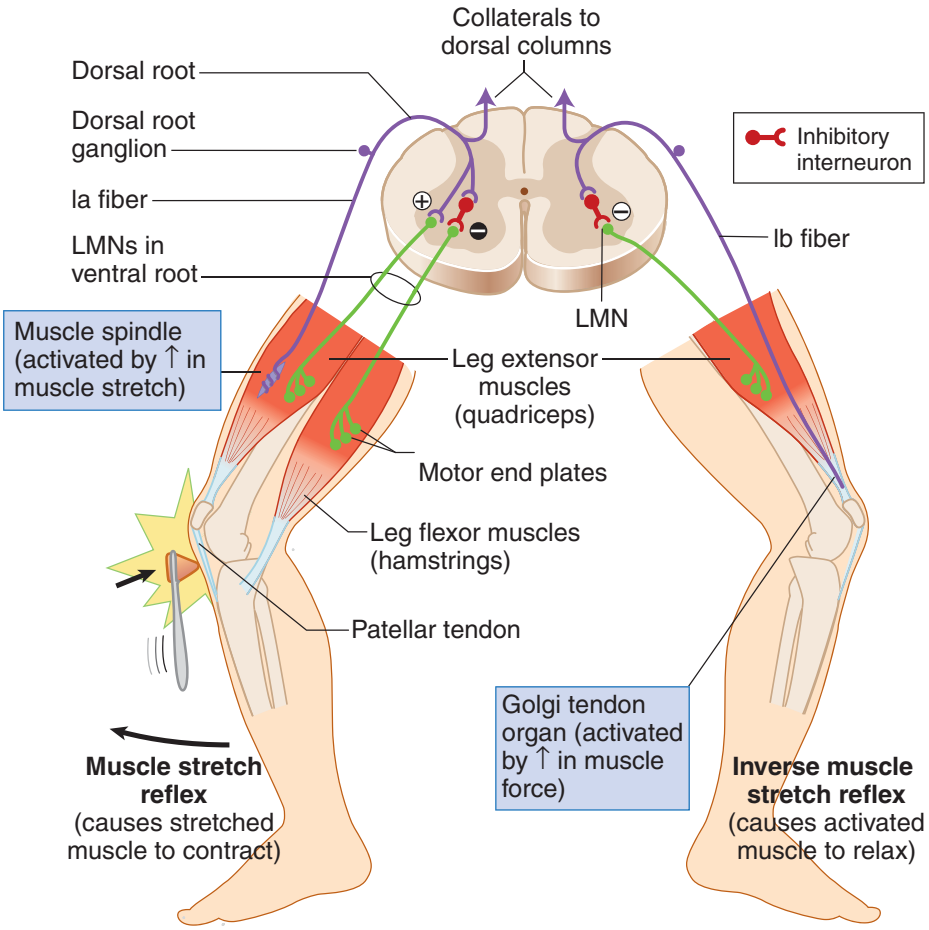

Figure III-4-7. Muscle Stretch and Golgi Tendon Reflex Components

Note

UMN lesions result in:

- Hyperactive muscle stretch reflexes
- Clasp knife reflex due to oversensitive Golgi tendon organs

Flexor withdrawal reflex

The flexion withdrawal reflex is a protective reflex in which a stimulus (usually painful) causes withdrawal of the stimulated limb. This reflex may be accompanied by a crossed extension reflex in which the contralateral limb is extended to help support the body.

Clinical Correlate

Upper Motoneuron Versus Lower Motoneuron Muscle Lesions

A fundamental requirement of interpreting the cause of motor weakness in neuroscience cases is the ability to distinguish between a lesion of an upper versus a lower motoneuron. Because a lesion to either one produces a weakness in the ability to voluntarily contract skeletal muscles, the key to distinguishing them will be the condition of reflexes of the affected muscles.

A lesion of any part of a lower motoneuron will result in hypoactive muscle stretch reflexes and a reduction in muscle tone (hypotonicity) because lower motoneurons form the motor component of the reflex. Therefore, lower motoneuron lesions result in a paresis combined with suppressed or absent muscle stretch reflexes. An early sign is muscle fasciculations, which are twitches or contractions of groups of muscle fibers, that may produce a twitch visible on the skin. Later, lower motoneuron lesions produce fibrillations, which are invisible 1- to 5-ms potentials, detected with electromyography. Muscles denervated by a lower motoneuron lesion undergo pronounced wasting or atrophy. The constellation of signs combining paresis with suppressed or absent reflexes, fasciculations, and atrophy is known as a **flaccid paralysis.** With few exceptions, lower motoneuron lesions produce a flaccid paralysis ipsilateral and at the level of the lesion.

Neurologically, upper motoneurons including the corticospinal tract have a net overall inhibitory effect on muscle stretch reflexes. As a result, they combine paresis of skeletal muscles with muscle stretch or deep tendon reflexes that are hyperactive or hypertonic. The hypertonia may be seen as decorticate rigidity (i.e., postural flexion of the arm and extension of the leg) or decerebrate rigidity (i.e., postural extension of the arm and leg) depending on the location of the lesion. Lesions above the midbrain produce decorticate rigidity; lesions below the midbrain produce decerebrate rigidity. Upper motoneuron lesions result in atrophy of weakened muscles only as a result of disuse, because these muscles can still be contracted by stimulating muscle stretch reflexes.

Upper motoneuron lesions are also accompanied by reversal of cutaneous reflexes, which normally yield a flexor motor response. The best known of the altered flexor reflexes is the **Babinski sign.** The test for the Babinski reflex is performed by stroking the lateral surface of the sole of the foot with a slightly painful stimulus. Normally, there is plantar flexion of the big toe. With a lesion of the corticospinal tract, the Babinski reflex is present, which is characterized by extension of the great toe and fanning of the other toes. Two other flexor reflexes, the abdominal and cremasteric, are also lost in upper motoneuron lesions. The constellation of signs combining paresis with increases or hyperactive reflexes, disuse atrophy of skeletal muscles, and altered cutaneous reflexes is known as a spastic paresis.

In contrast to lower motoneuron lesions, lesions of upper motoneurons result in a **spastic paresis** that is ipsilateral or contralateral and below the site of the lesion.
Upper motoneuron lesions anywhere in the spinal cord will result in an ipsilateral spastic paresis below the level of the lesion. Upper motoneuron lesions between the cerebral cortex and the medulla above the decussation of the pyramids will result in a contralateral spastic paresis below the level of the lesion.

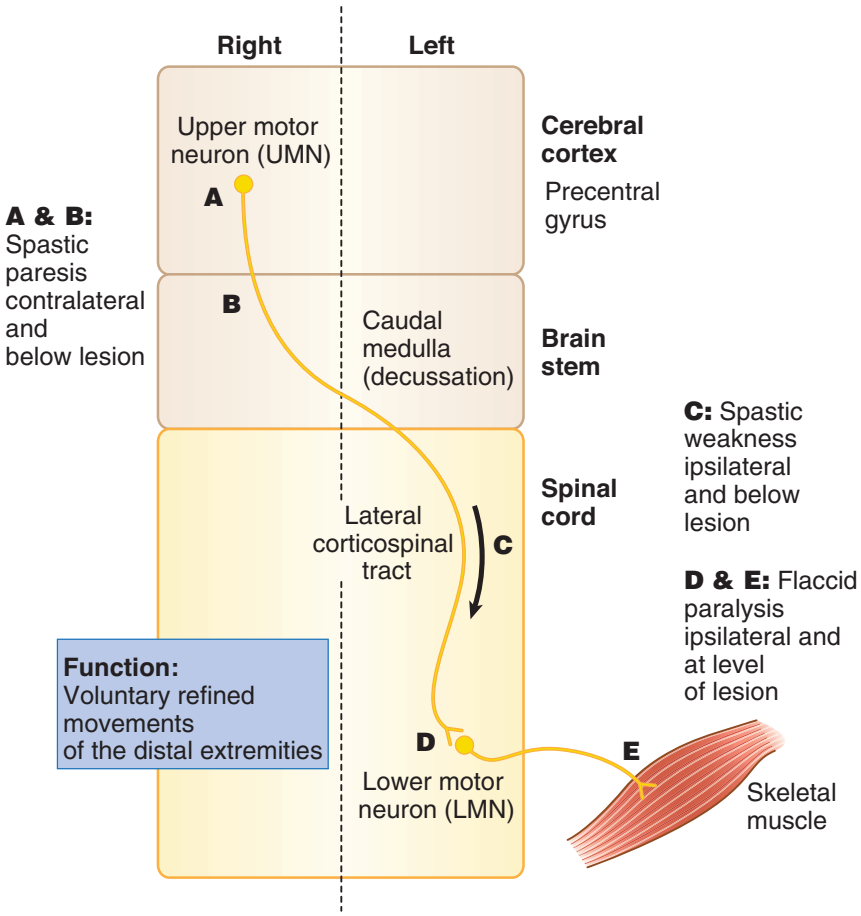

Figure III-4-8. Upper Versus Lower Motor Neuron Lesions

Table III-4-2. Upper Versus Lower Motoneuron Lesions

Upper Motor Neuron Lesion*	Lower Motor Neuron Lesion†
Spastic paresis	Flaccid paralysis
Hyperreflexia	Areflexia
Babinski sign present	No Babinski
Increased muscle tone	Fasciculations
Clasp knife reflex	Decreased muscle tone or atonia
Disuse atrophy of muscles	Atrophy of muscle(s)
Decreased speed of voluntary movements	Loss of voluntary movements
Large area of the body involved	Small area of the body affected

*Deficits contralateral or ipsilateral and below the lesion

†Deficits ipsilateral and at the level of lesion

Sensory Systems

Two sensory systems, the dorsal column–medial lemniscal system and the anterolateral (spinothalamic) system, use 3 neurons to convey sensory information from peripheral sensory receptors to conscious levels of cerebral cortex. In both systems, the first sensory neuron that innervates a sensory receptor has a cell body in the dorsal root ganglion and carries the information into the spinal cord in the dorsal root of a spinal nerve. The first neuron synapses with a second neuron in the brain stem or the spinal cord, and the axon of the second neuron crosses the midline and is carried in a tract in the CNS. The axon of the second neuron then synapses on a third neuron that is in the thalamus. The axon of the third neuron projects to primary somatosensory cortex.

1: first-order neuron in sensory ganglion

2: second-order neuron in CNS (axon always crosses midline)

3: third-order neuron in thalamus

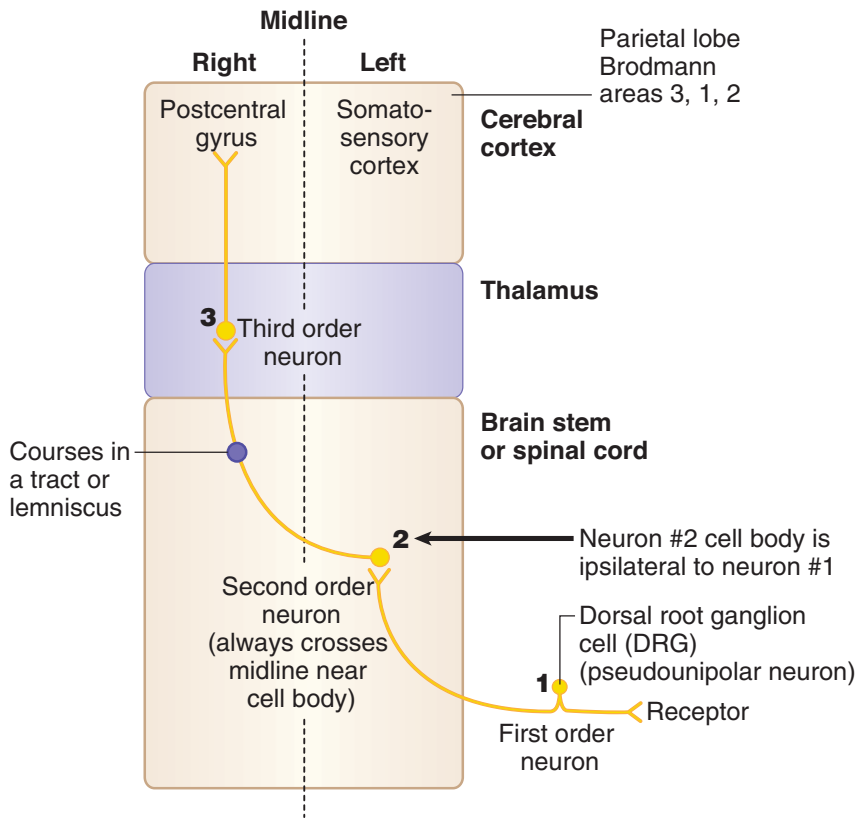

Figure III-4-9. General Sensory Pathways

Ascending Pathways

The 2 most important ascending pathways use a 3-neuron system to convey sensory information to the cortex. Key general features are listed below.

Pathway	Function	Overview
Dorsal column–medial lemniscal system	Discriminative touch, conscious proprioception, vibration, pressure	**3-neuron system:** 1° neuron: cell body in **DRG** 2° neuron: **decussates** 3° neuron: **thalamus (VPL) → cortex**
Anterolateral system (spinothalamic)	Pain and temperature	

Abbreviations: DRG, dorsal root ganglia; VPL, ventral posterolateral nucleus.

Dorsal column–medial lemniscal system

The dorsal column–medial lemniscal system carries sensory information for discriminative touch, joint position (kinesthetic or conscious proprioceptive) sense, vibratory, and pressure sensations from the trunk and limbs. The primary afferent neurons in this system have their cell bodies in the dorsal root ganglia, enter the cord via class II or A-beta dorsal root fibers, and then coalesce in the fasciculus gracilis or fasciculus cuneatus in the dorsal funiculus of the spinal cordfasciculus cuneatus in the dorsal funiculus of the spinal cord. The fasciculus gracilis, found at all spinal cord levels, is situated closest to the midline and carries input from the lower extremities and lower trunk. The fasciculus cuneatus, found only at upper thoracic and cervical spinal cord levels, is lateral to the fasciculus gracilis and carries input from the upper extremities and upper trunk. These 2 fasciculi form the dorsal columns of the spinal cord that carry the central processes of dorsal root ganglion cells and ascend the length of the spinal cord to reach their second neurons in the lower part of the medulla.

In the lower part of the medulla, fibers in the fasciculus gracilis and fasciculus cuneatus synapse with the second neurons found in the nucleus gracilis and nucleus cuneatus, respectively. Cells in these medullary nuclei give rise to fibers that cross the midline as internal arcuate fibers and ascend through the brain stem in the medial lemniscus ascend through the brain stem in the medial lemniscus. Fibers of the medial lemniscus terminate on cells of the ventral posterolateral (VPL) nucleus of the thalamus. From the VPL nucleus, thalamocortical fibers project to the primary somesthetic (somatosensory) area of the postcentral gyrus, located in the most anterior portion of the parietal lobe.

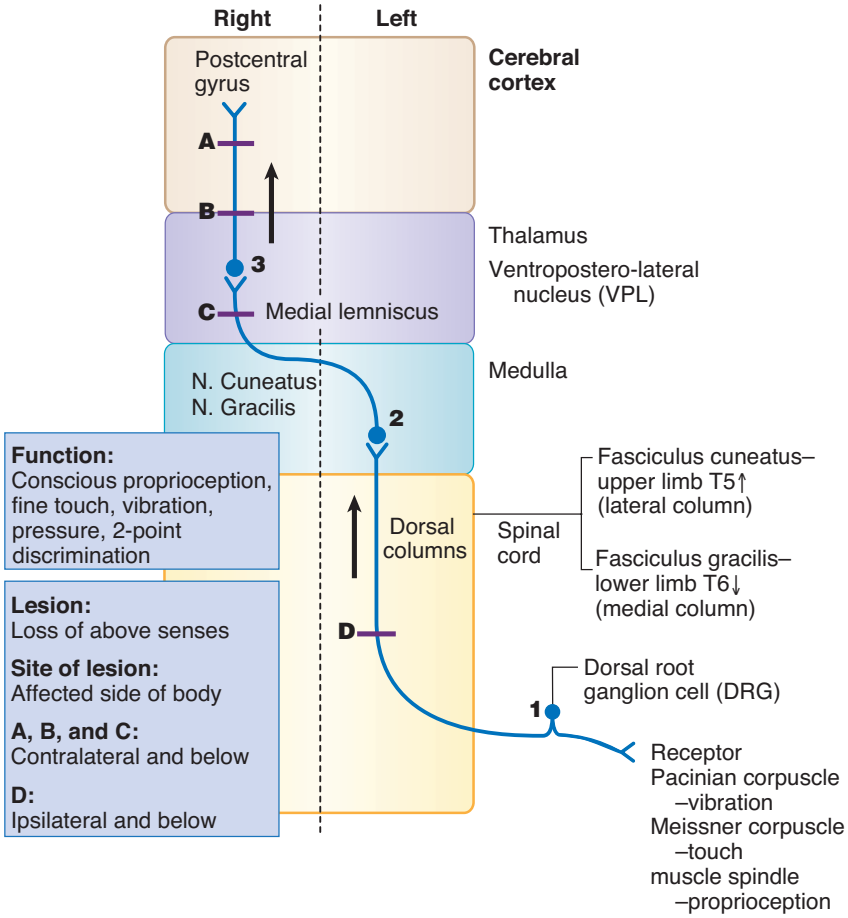

Figure III-4-10. Dorsal Column Pathway–Medial Lemniscal System

Clinical Correlate

Lesions of the dorsal columns result in a loss of joint position sensation, vibratory and pressure sensations, and 2-point discrimination. There is loss of the ability to identify the characteristics of an object, called astereognosis (e.g., size, consistency, form, shape), using only the sense of touch. Typically, dorsal column–medial lemniscal lesions are evaluated by testing vibratory sense using a 128-Hz tuning fork. Romberg sign is also used to distinguish between lesions of the dorsal columns and the midline (vermal area) of the cerebellum.

Romberg sign is tested by asking the patients to place their feet together. If there is a marked deterioration of posture (if the patient sways) with the eyes closed, this is a positive Romberg sign, suggesting that the lesion is in the dorsal columns (or dorsal roots of spinal nerves). With the eyes open, interruption of proprioceptive input carried by the dorsal columns can be compensated for by visual input to the cerebellum. Therefore, if the patient has balance problems and tends to sway with the eyes open, this is indicative of cerebellar damage.

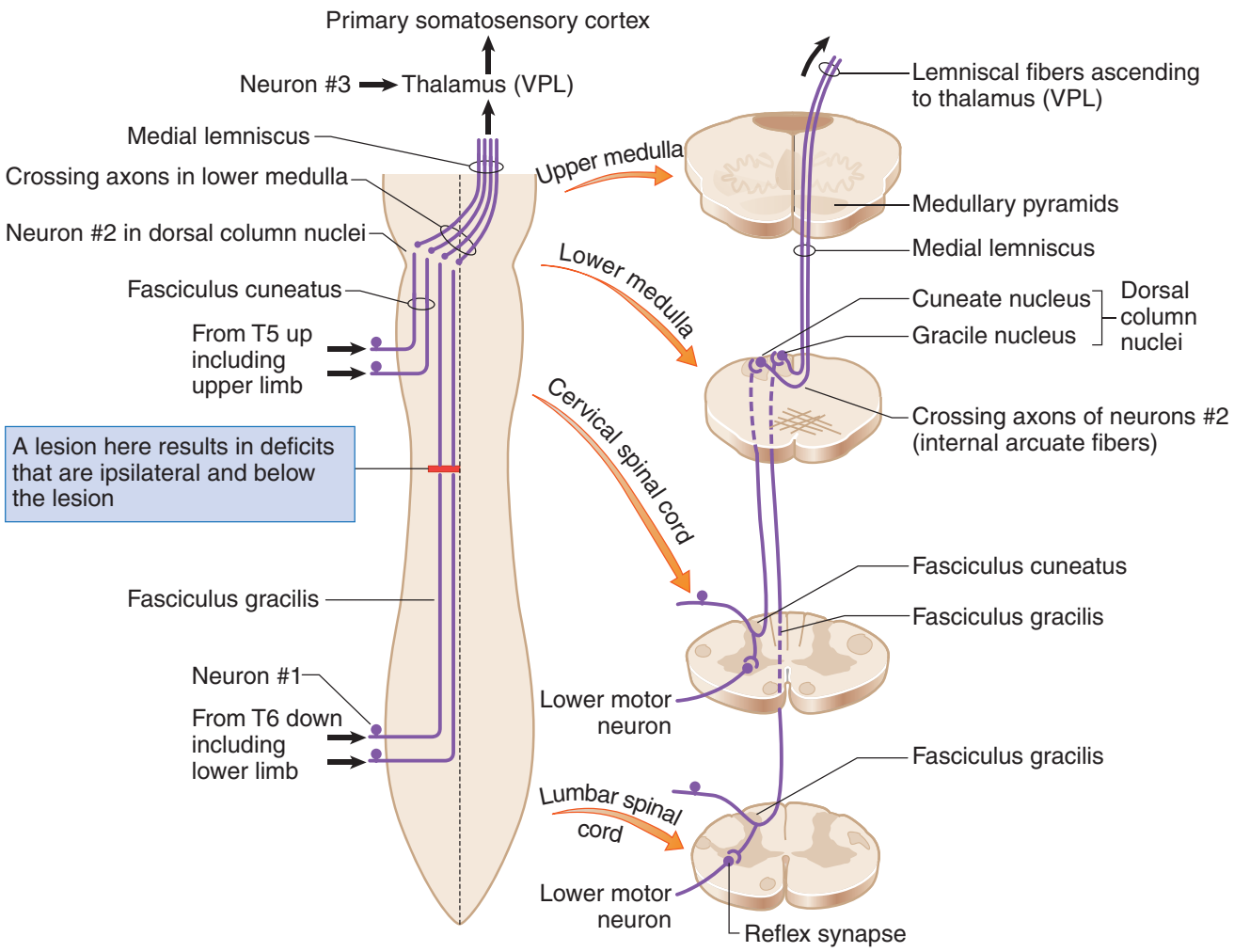

Figure III-4-11. Dorsal Column/Medial Lemniscal System in the Spinal Cord and Medulla

Anterolateral (spinothalamic tract) system

The anterolateral system carries pain, temperature, and crude touch sensations from the extremities and trunk.

Pain and temperature fibers have cell bodies in the dorsal root ganglia and enter the spinal cord via A-delta and C or class III and class IV dorsal root fibers. Their fibers ascend or descend a couple of segments in the dorsolateral tract of Lissauer before entering and synapsing in the dorsal horn. The second neuron cell bodies are located in the dorsal horn gray matter. Axons from these cells cross in the ventral white commissure just below the central canal of the spinal cord and coalesce to form the spinothalamic tract in the ventral part of the lateral funiculus. The spinothalamic tract courses through the entire length of the spinal cord and the brain stem to terminate in the VPL nucleus of the thalamus. Cells in the VPL nucleus send pain and temperature information to the primary somatosensory cortex in the postcentral gyrus.

Clinical Correlate

Because the pain and temperature information crosses almost as soon as it enters the spinal cord, any unilateral **lesion of the spinothalamic tract** in the spinal cord or brain stem will result in a contralateral loss of pain and temperature. This is an extremely useful clinical sign because it means that if a patient presents with analgesia on one side of the trunk or limbs, the location of the lesion must be on the contralateral side of the spinal cord or brain stem. The analgesia begins 1 to 2 segments below the lesion and includes everything below that level.

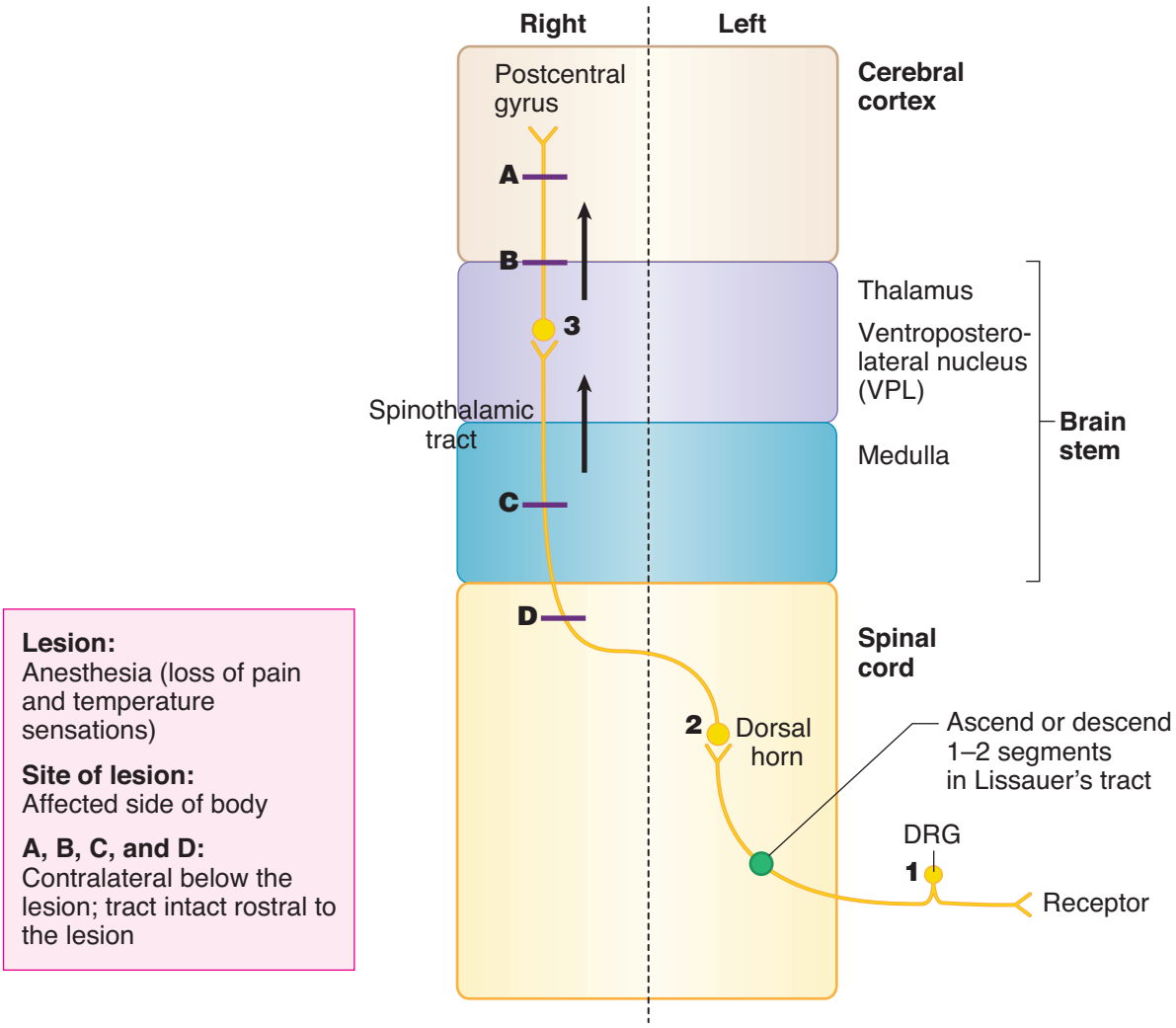

Figure III-4-12. Spinothalamic Tract (Anterolateral System)

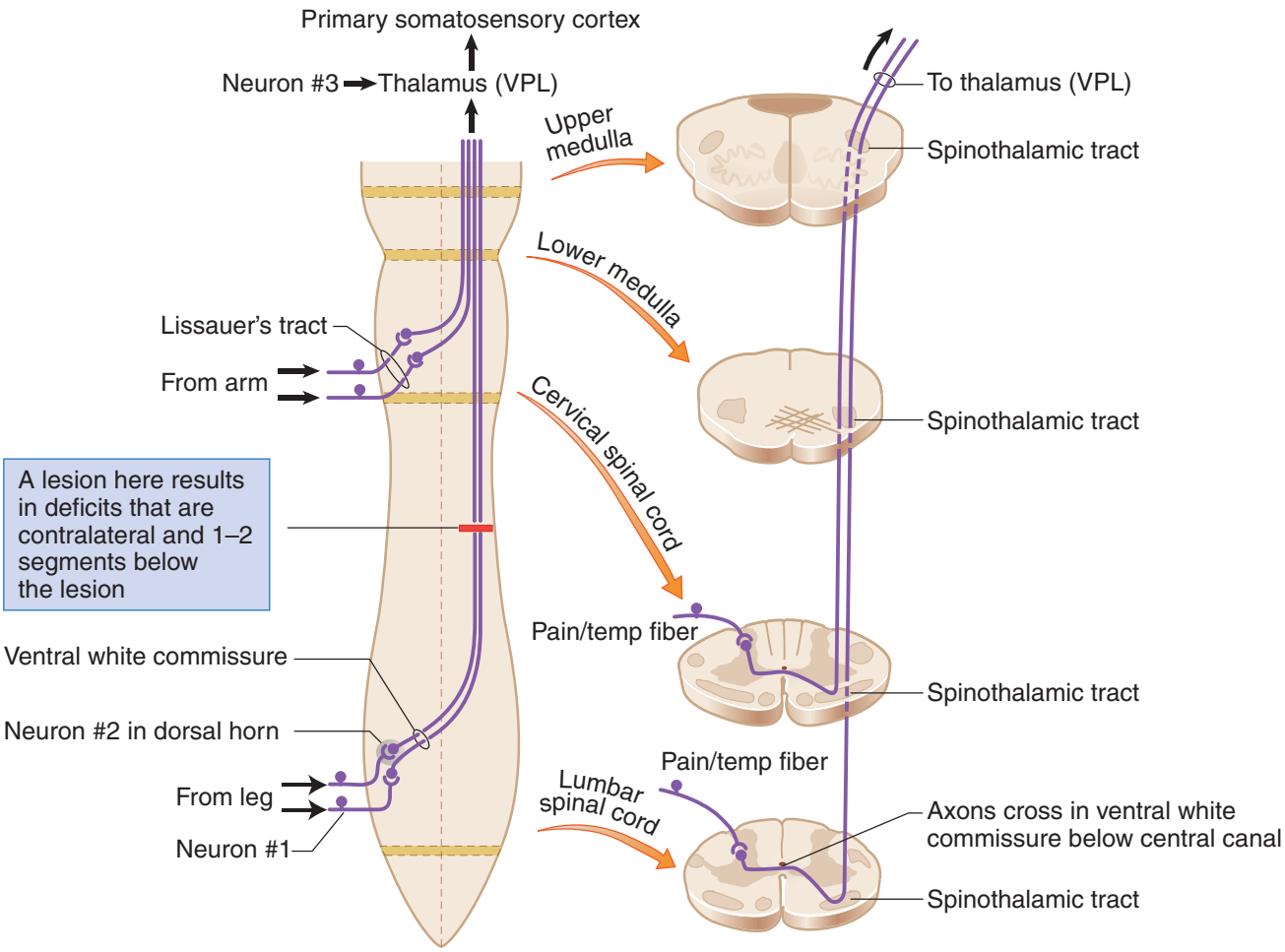

Figure III-4-13. Anterolateral System in the Spinal Cord and Medulla

Spinocerebellar pathways

The spinocerebellar tracts mainly carry unconscious proprioceptive input from muscle spindles and GTOs to the cerebellum, where this information is used to help monitor and modulate movements. There are 2 major spinocerebellar pathways:

- Dorsal spinocerebellar tract—carries input from the lower extremities and lower trunk.
- Cuneocerebellar tract—carries proprioceptive input to the cerebellum from the upper extremities and upper trunk.

The cell bodies of the dorsal spinocerebellar tract are found in Clarke's nucleus, which is situated in the spinal cord from T1 to L2. The cell bodies of the cuneocerebellar tract are found in the medulla in the external cuneate nucleus.

Clinical Correlate

Lesions that affect only the spinocerebellar tracts are uncommon, but there are a group of hereditary diseases in which degeneration of spinocerebellar pathways is a prominent feature. The most common of these is Friedreich ataxia, which is usually inherited as an autosomal recessive trait. The spinocerebellar tracts, dorsal columns, corticospinal tracts, and cerebellum may be involved. Ataxia of gait is the most common initial symptom of this disease.

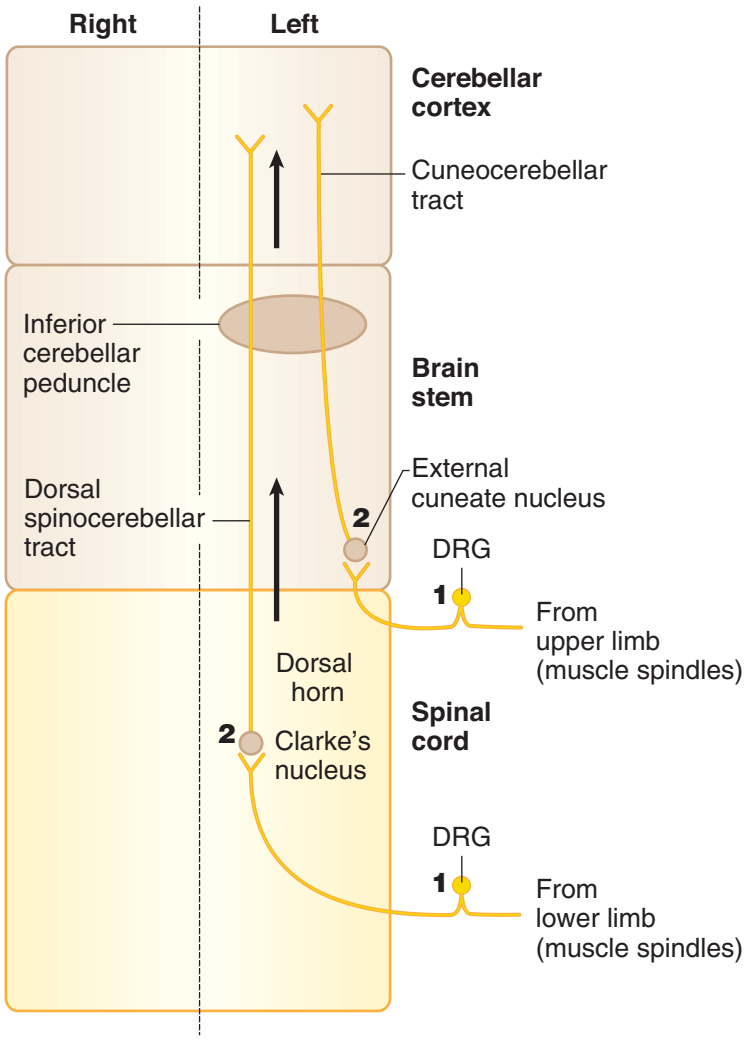

Figure III-4-14. Spinocerebellar Tracts

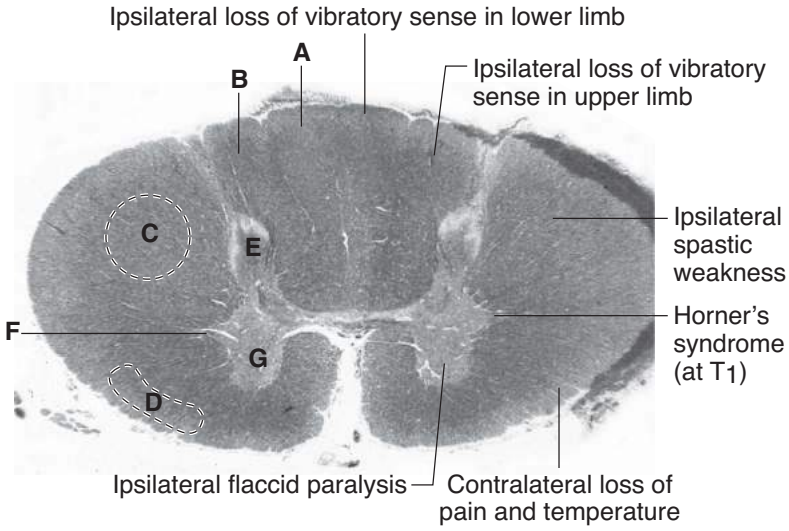

Figure III-4-15. Major spinal cord neural components and clinical anatomy depicted in myelin-stained section of upper thoracic cord.

A Fasciculus Gracilis, B Fasciculus Cuneatus, C Corticospinal tract, D Anterolateral system, E Dorsal Horn, F Lateral horn (preganglionic sympathetic neurons), G Ventral horn (lower motor neurons)

Features to look for to identify a cord section:

- Is there a large ventral horn?

Yes → C_5–T_1, or L_2–S_2

No → T_2–L_1, C_1–C_4

- Are both dorsal columns present?

Yes → Above T_5

No → Below T_5

- Is there a lateral horn present?

Yes → T_1–L_2

No → C_1–C_8 or L_3–S_5

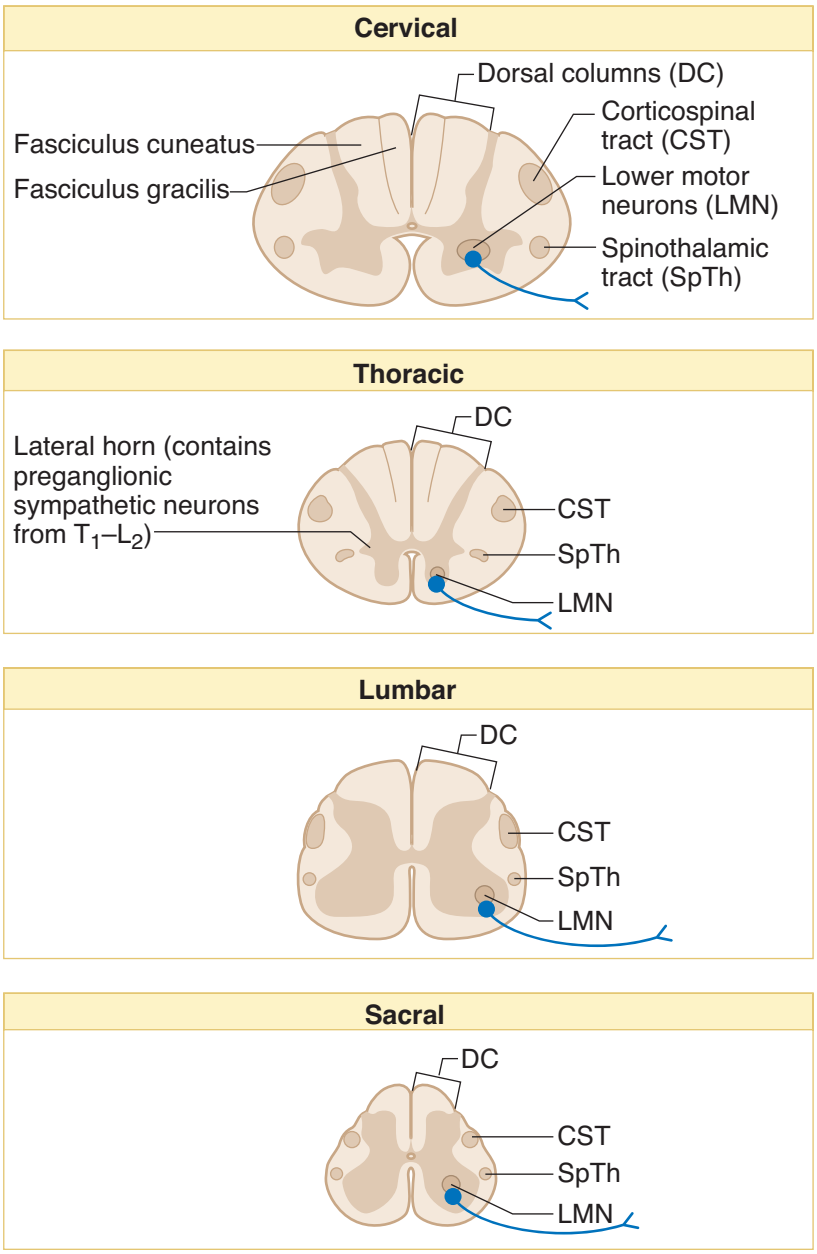

Figure III-4-16. Spinal Cord: Levels

Note

In Argyll Robertson pupil, the pupil reacts to accommodation but not to light.

Spinal Cord Lesions

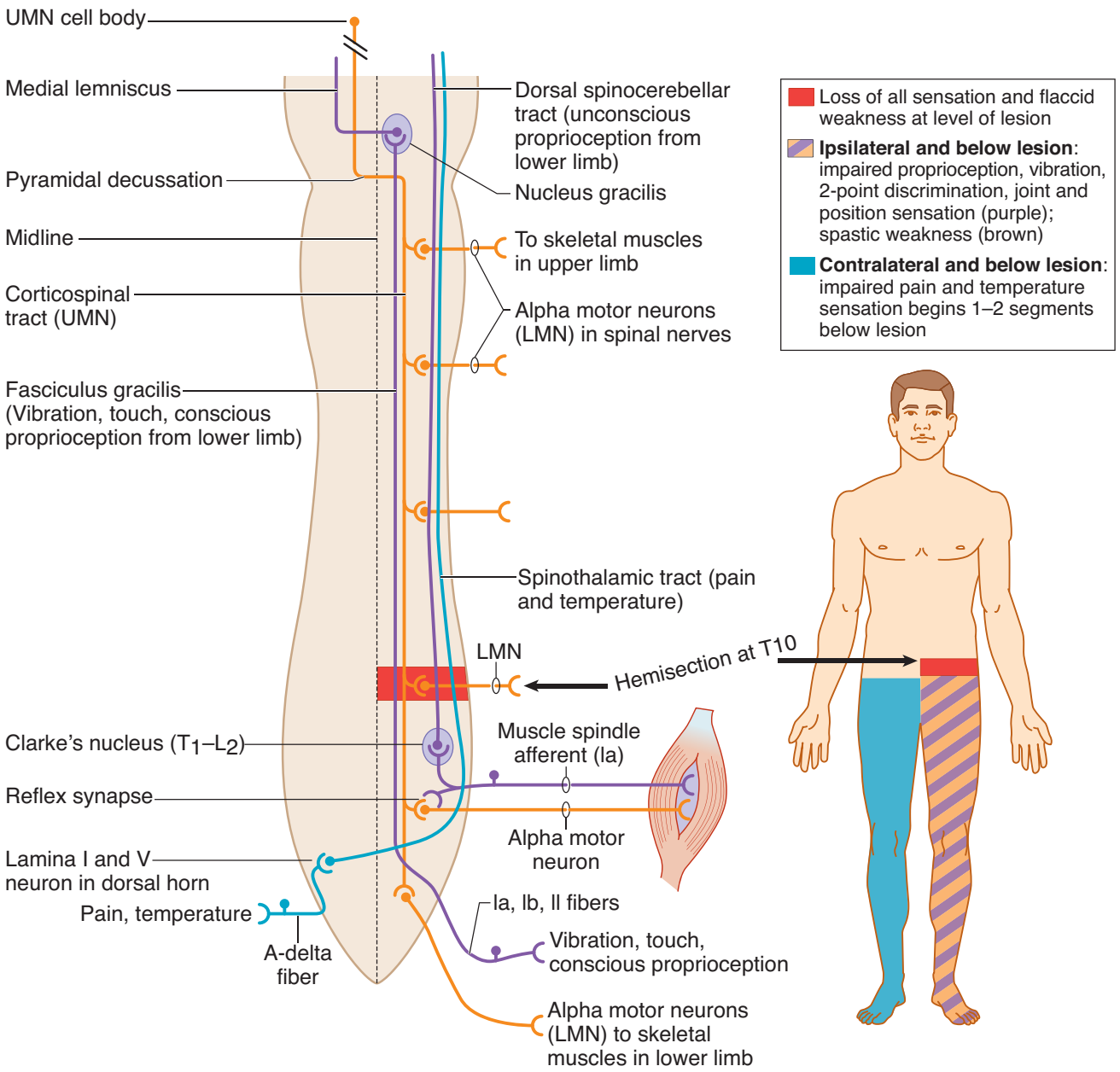

Figure III-4-17. Spinal Cord Overview and Brown-Séquard Syndrome with Lesion at Left Tenth Thoracic Segment

Brown-Séquard syndrome

Hemisection of the cord results in a lesion of each of the 3 main neural systems: the principal upper motoneuron pathway of the corticospinal tract, one or both dorsal columns, and the spinothalamic tract. The hallmark of a lesion to these 3 long tracts is that the patient presents with 2 ipsilateral signs and 1 contralateral sign.

- Lesion of the corticospinal tract results in an ipsilateral spastic paresis below the level of the injury.
- Lesion of the fasciculus gracilis or cuneatus results in an ipsilateral loss of joint position sense, tactile discrimination, and vibratory sensations below the lesion.
- Lesion of the spinothalamic tract results in a contralateral loss of pain and temperature sensation starting 1 or 2 segments below the level of the lesion.

At the level of the lesion, there will be an ipsilateral loss of all sensation, including touch modalities as well as pain and temperature, and an ipsilateral flaccid paralysis in muscles supplied by the injured spinal cord segments (Figure III-4-15).

Polio

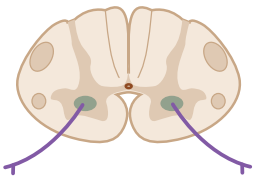

a. Flaccid paralysis
b. Muscle atrophy
c. Fasciculations
d. Areflexia
e. Common at lumbar levels

Tabes Dorsalis

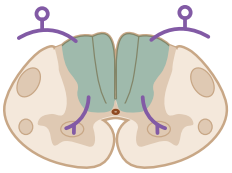

a. "Paresthesias, pain, polyuria"
b. Associated with late-stage syphilis, sensory ataxia, positive Romberg sign: sways with eyes closed, Argyll Robertson pupils, suppressed reflexes
c. Common at lumbar cord levels

Amyotrophic Lateral Sclerosis (ALS)

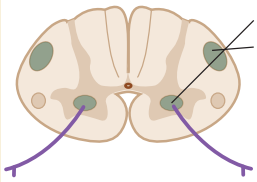

a. Progressive spinal muscular atrophy (ventral horn)
b. Primary lateral sclerosis (corticospinal tract)
   - Spastic paralysis in lower limbs
   - Increased tone and reflexes
   - Flaccid paralysis in upper limbs
c. Common in cervical enlargement

Anterior Spinal Artery (ASA) Occlusion

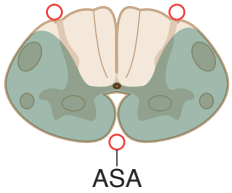

a. DC spared
b. All else bilateral signs
c. Common at mid thoracic levels
d. Spastic bladder

Figure III-4-18. Lesions of the Spinal Cord I

Clinical Correlate

Tabes patients present with paresthesias (pins-and-needles sensations), pain, polyuria, Romberg sign.

Clinical Correlate

Spastic bladder results from lesions of the spinal cord **above the sacral spinal cord levels**. There is a loss of inhibition of the parasympathetic nerve fibers that innervate the detrusor muscle during the filling stage. Thus, the detrusor muscle responds to a minimum amount of stretch, causing urge incontinence.

Clinical Correlate

Atonic bladder results from lesions **to the sacral spinal cord segments** or the sacral spinal nerve roots. Loss of pelvic splanchnic motor innervation with loss of contraction of the detrusor muscle results in a full bladder with a continuous dribble of urine from the bladder.

Poliomyelitis

Poliomyelitis results from a relatively selective destruction of lower motoneurons in the ventral horn by the poliovirus. The disease causes a flaccid paralysis of muscles with the accompanying hyporeflexia and hypotonicity. Some patients may recover most function, whereas others progress to muscle atrophy and permanent disability.

Amyotrophic lateral sclerosis

Amyotrophic lateral sclerosis (ALS, Lou Gehrig disease) is a relatively pure motor system disease that affects both upper and lower motoneurons. The disease typically begins at cervical levels of the cord and progresses either up or down the cord. Patients present with bilateral flaccid weakness of the upper limbs and bilateral spastic weakness of the lower limbs. Lower motoneurons in the brain-stem nuclei may be involved later.

Subacute Combined Degeneration

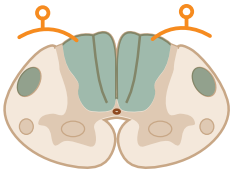

a. Vitamin B12, pernicious anemia
b. Demyelination of the:
   - Dorsal columns (central and peripheral myelin)
   - Spinocerebellar tracts
   - Corticospinal tracts (CST)
c. Upper thoracic or lower cervical cord

Syringomyelia

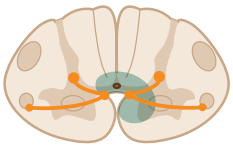

a. Cavitation of the cord (usually cervical)
b. Bilateral loss of pain and temperature at the level of the lesion
c. As the disease progresses, there is muscle weakness; eventually flaccid paralysis and atrophy of the upper limb muscles due to destruction of ventral horn cells

Hemisection: Brown-Séquard Syndrome (cervical)

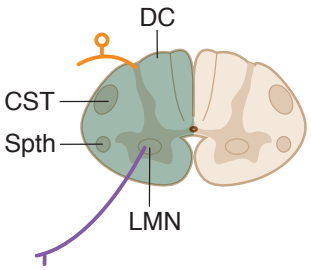

a. DC: Ipsilateral loss of position and vibratory senses at and below level of the lesion
b. Spinothalamic tract: Contralateral loss of pain and temp 1–2 segments below lesion and ipsilateral loss at the level of the lesion
c. CST: Ipsilateral paresis below the level of the lesion
d. LMN: Flaccid paralysis at the level of the lesion
e. Descending hypothalamics: Ipsilateral Horner syndrome (if cord lesion is above T1)
   - Facial hemianhydrosis
   - Ptosis (slight)
   - Miosis

Figure III-4-19. Lesions of the Spinal Cord II

Clinical Correlate

Subacute combined degeneration patients present paresthesias, bilateral spastic weakness, Babinski sign Babinski signs, and antibodies to intrinsic factor.

Clinical Correlate

Syringomyelia may present with hydrocephalus and Arnold-Chiari I malformation.

Note

Syringomyelia results in a "belt-like" or "cape-like" loss of pain and temperature.

Occlusion of the anterior spinal artery

This artery lies in the anterior median sulcus of the spinal cord. Occlusion of the anterior spinal artery interrupts blood supply to the ventrolateral parts of the cord, including the corticospinal tracts and spinothalamic tracts. Below the level of the lesion, the patient exhibits a bilateral spastic paresis and a bilateral loss of pain and temperature.

Syringomyelia

Syringomyelia is a disease characterized by progressive cavitation of the central canal, usually in the cervical spinal cord but may involve other cord regions or the medulla. Early in the disease, there is a bilateral loss of pain and temperature sensation in the hands and forearms as a result of the destruction of spinothalamic fibers crossing in the anterior white commissure. When the cavitation expands, lower motoneurons in the ventral horns are compressed, resulting in bilateral flaccid paralysis of upper limb muscles. A late manifestation of cavitation is **Horner syndrome**, which occurs as a result of involvement of descending hypothalamic fibers innervating preganglionic sympathetic neurons in the T1 through T4 cord segments. Horner syndrome consists of miosis (pupillary constriction), ptosis (drooping eyelids), and anhidrosis (lack of sweating) in the face.

Tabes dorsalis

Tabes dorsalis is one possible manifestation of neurosyphilis. It is caused by bilateral degeneration of the dorsal roots and secondary degeneration of the dorsal columns. There may be impaired vibration and position sense, astereognosis, paroxysmal pains, and ataxia, as well as diminished stretch reflexes or incontinence. Owing to the loss of proprioceptive pathways, individuals with tabes dorsalis are unsure of where the ground is and walk with a characteristic and almost diagnostic "high-step stride". Tabetic patients may also present with abnormal pupillary responses (Argyll Robertson pupils).

Subacute combined degeneration

Subacute combined degeneration is seen most commonly in cases of vitamin B12 deficiency, sometimes related to pernicious anemia. The disease is characterized by patchy losses of myelin in the dorsal columns and lateral corticospinal tracts, resulting in a bilateral spastic paresis and a bilateral alteration of touch, vibration, and pressure sensations below the lesion sites. Myelin in both CNS and PNS is affected.

The Brain Stem 5

Learning Objectives

- ❑ Answer questions about cranial nerves
- ❑ Answer questions about sensory and motor neural systems
- ❑ Solve problems concerning medulla
- ❑ Demonstrate understanding of pons
- ❑ Interpret scenarios on midbrain
- ❑ Interpret scenarios on components of the ear, auditory, and vestibular systems
- ❑ Demonstrate understanding of horizontal conjugate gaze
- ❑ Solve problems concerning blood supply to the brain stem
- ❑ Interpret scenarios on brain-stem lesions
- ❑ Interpret scenarios on reticular formation

The brain stem is divisible into 3 continuous parts: the midbrain, the pons, and the medulla. The **midbrain** is most rostral and begins just below the diencephalon. The **pons** is in the middle and is overlain by the cerebellum. The **medulla** is caudal to the pons and is continuous with the spinal cord.

The brain stem is the home of the origins or sites of termination of fibers in 9 of the 12 cranial nerves (CNs).

CRANIAL NERVES

Two cranial nerves, the oculomotor and trochlear (CN III and IV), arise from the midbrain. **Four cranial nerves**, the trigeminal, abducens, facial, and vestibulocochlear nerves (CN V, VI, VII, and VIII), enter or exit from the pons. **Three cranial nerves**, the glossopharyngeal, vagus, and hypoglossal nerves (CN IX, X, and XII), enter or exit from the medulla. Fibers of the accessory nerve arise from the cervical spinal cord.

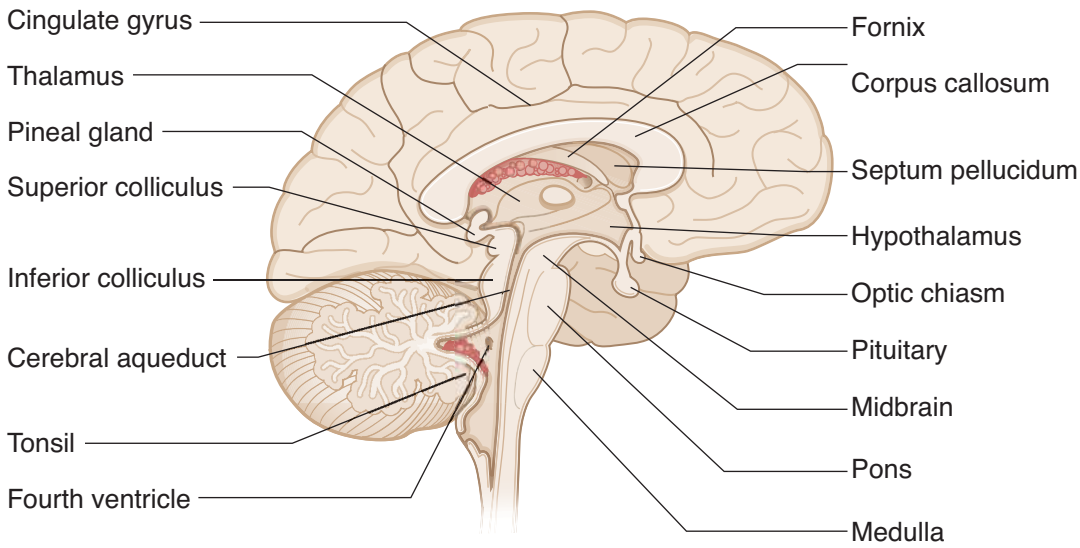

Figure III-5-1. Brain: Mid-Sagittal Section

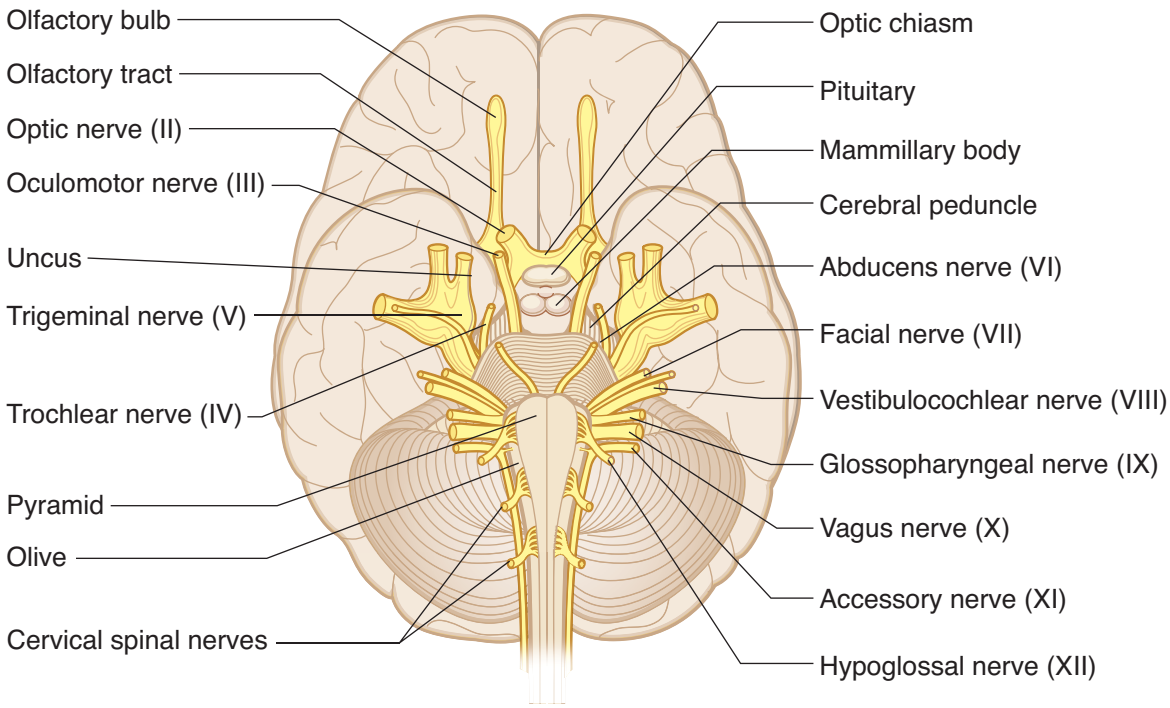

Figure III-5-2. Brain: Inferior View

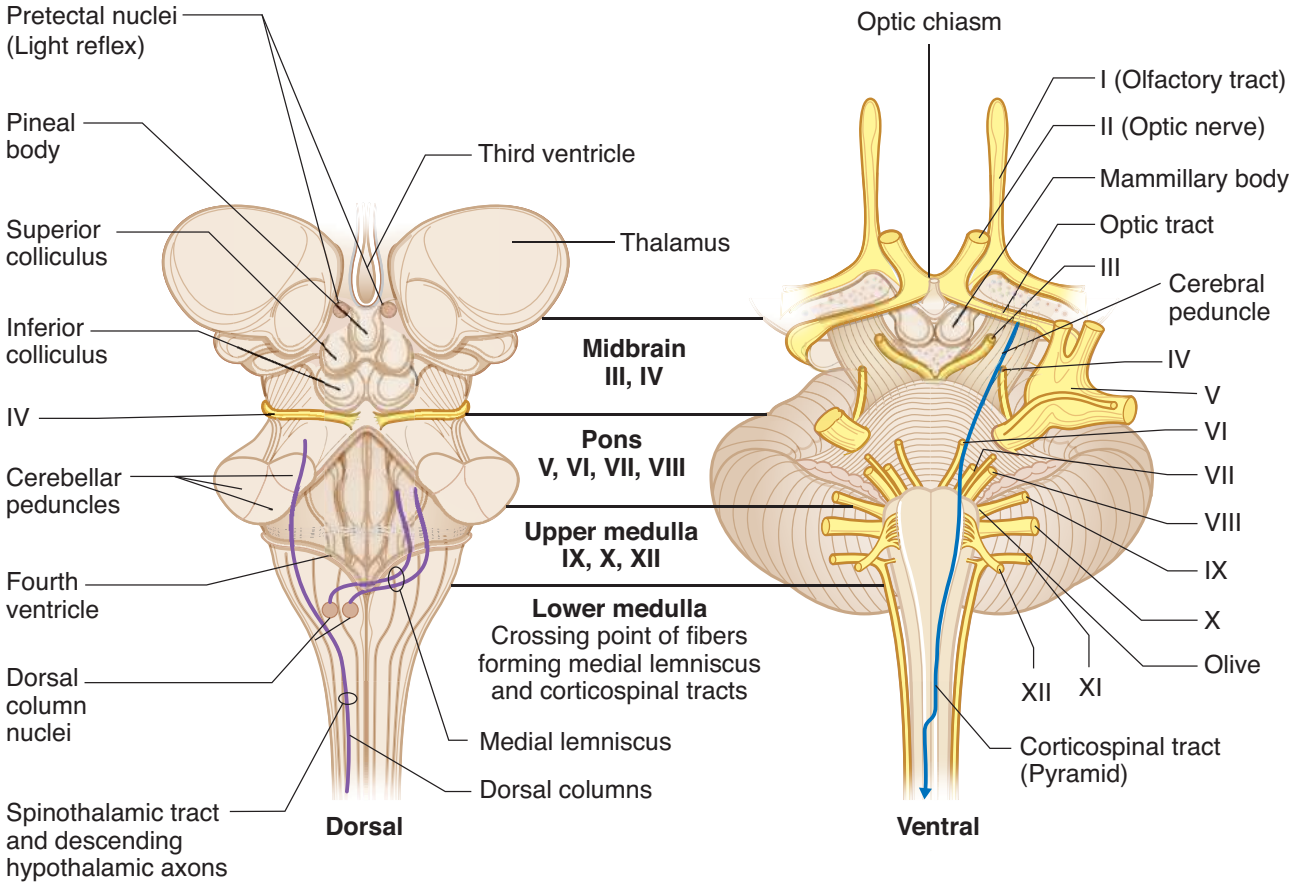

Figure III-5-3. Brain Stem and Cranial Nerve: Surface Anatomy

Afferent fibers of cranial nerves enter the CNS and terminate in relation to aggregates of neurons in sensory nuclei. Motor or efferent components of cranial nerves arise from motor nuclei. All motor and sensory nuclei that contribute fibers to cranial nerves are organized in a series of discontinuous columns according to the functional component that they contain. Motor nuclei are situated medially, closest to the midline, and sensory nuclei are situated lateral to the motor nuclei. A cranial nerve nucleus or nerve will be found at virtually every transverse sectional level of the brain stem.

Note

The descending hypothalamic fibers course with the spinothalamic tract.

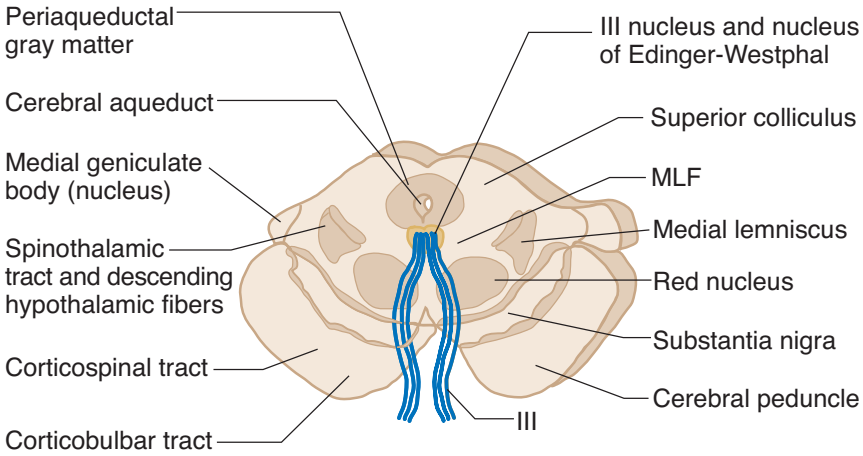

Figure III-5-4A. Upper Midbrain; Level of Nerve III

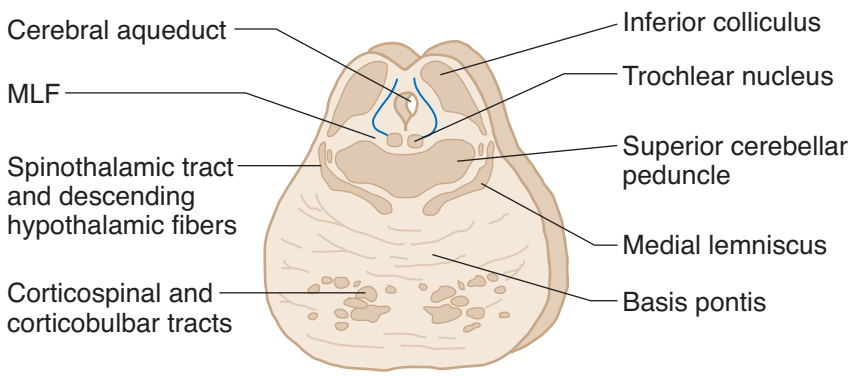

Figure III-5-4B. Lower Midbrain; Level of Nucleus CN IV

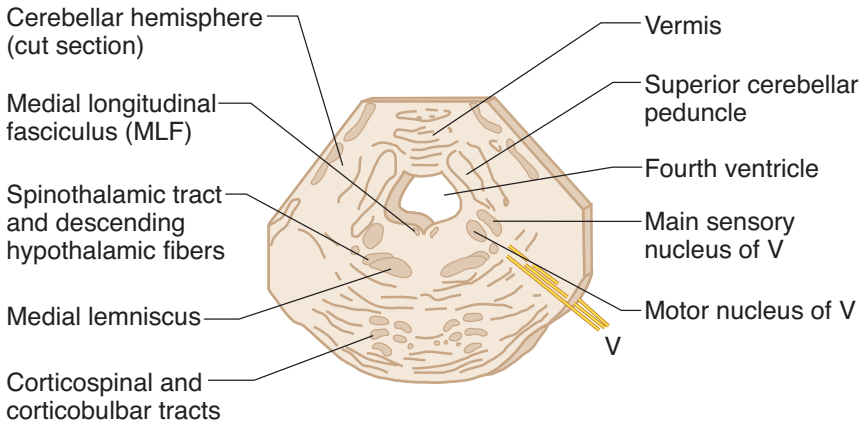

Figure III-5-4C. Middle Pons; Level of Nerve V

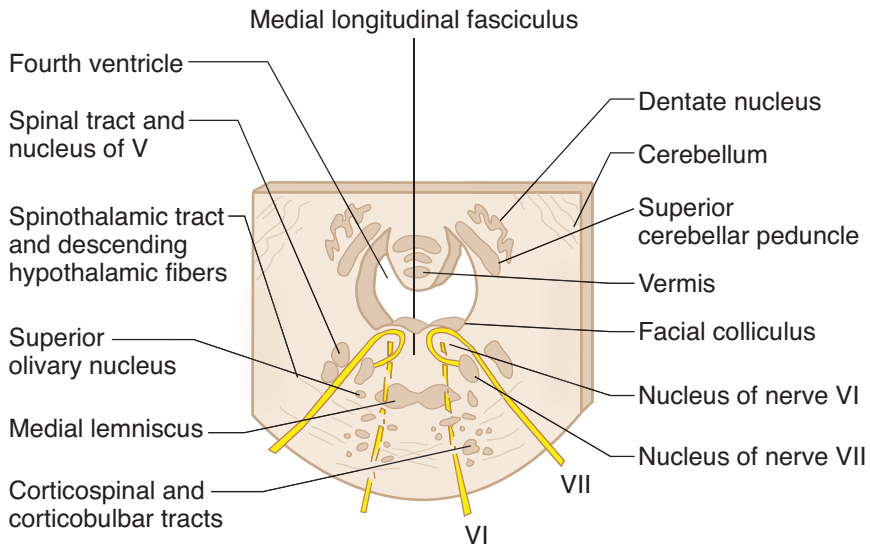

Figure III-5-4D. Lower Pons; Level of Nerves VI and VII

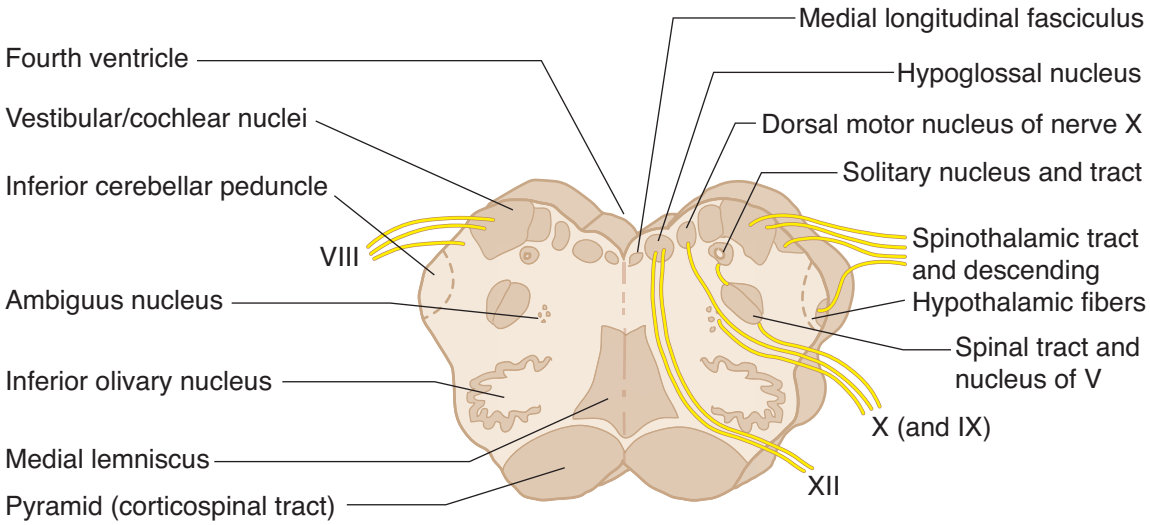

Figure III-5-4E. Open Medulla

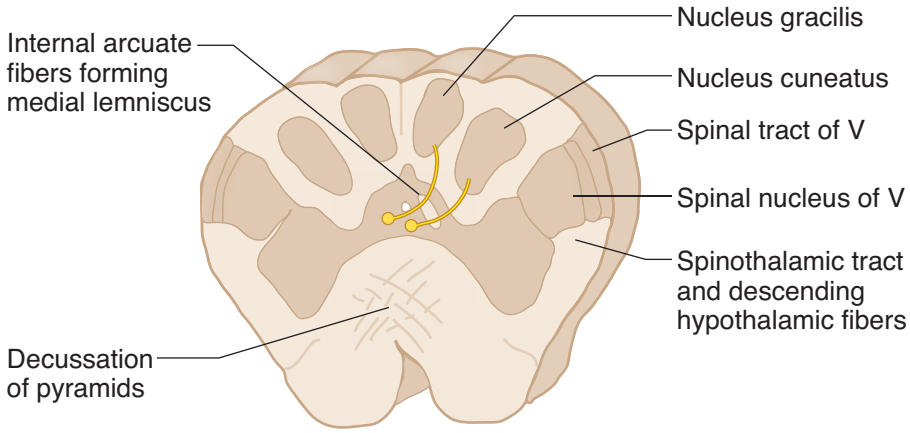

Figure III-5-4F. Closed Medulla

Table III-5-1. Cranial Nerves: Functional Features

CN	Name	Type	Function	Results of Lesions
I	Olfactory	Sensory	Smells	Anosmia
II	Optic	Sensory	Sees	Visual field deficits (anopsia) Loss of light reflex with III Only nerve to be affected by MS
III	Oculomotor	Motor	Innervates SR, IR, MR, IO extraocular muscles: adduction (MR) most important action Raises eyelid (levator palpebrae superioris) Constricts pupil (sphincter pupillae) Accommodates (ciliary muscle)	Diplopia, external strabismus Loss of parallel gaze Ptosis Dilated pupil, loss of light reflex with II Loss of near response
CN	**Name**	**Type**	**Function**	**Results of Lesions**
IV	Trochlear	Motor	Superior oblique—depresses and abducts eyeball (makes eyeball look down and out) Intorts	Weakness looking down with adducted eye Trouble going down stairs Head tilts away from lesioned side
V	Trigeminal Ophthalmic (V1) Maxillary (V2) Mandibular (V3)	Mixed	General sensation (touch, pain, temperature) of forehead/scalp/cornea General sensation of palate, nasal cavity, maxillary face, maxillary teeth General sensation of anterior two-thirds of tongue, mandibular face, mandibular teeth Motor to muscles of mastication (temporalis, masseter, medial and lateral pterygoids) and anterior belly of digastric, mylohyoid, tensor tympani, tensor palati	V1—loss of general sensation in skin of forehead/scalp Loss of blink reflex with VII V2—loss of general sensation in skin over maxilla, maxillary teeth V3—loss of general sensation in skin over mandible, mandibular teeth, tongue, weakness in chewing Jaw deviation toward weak side Trigeminal neuralgia—intractable pain in V2 or V3 territory

Table III-5-1. Cranial Nerves: Functional Features (continued)

CN	Name	Type	Function	Results of Lesions
VI	Abducens	Motor	Lateral rectus—abducts eyeball	Diplopia, internal strabismus Loss of parallel gaze, "pseudoptosis"
VII	Facial	Mixed	To muscles of facial expression, posterior belly of digastric, stylohyoid, stapedius Salivation (submandibular, sublingual glands) Skin behind ear Taste in anterior 2/3 of tongue/palate Tears (lacrimal gland)	Corner of mouth droops, cannot close eye, cannot wrinkle forehead, loss of blink reflex, hyperacusis; Bell palsy—lesion of nerve in facial canal Pain behind ear Alteration or loss of taste (ageusia) Eye dry and red
VIII	Vestibulocochlear	Sensory	Hearing Angular acceleration (head turning) Linear acceleration (gravity)	Sensorineural hearing loss Loss of balance, nystagmus
IX	Glossopharyngeal	Mixed	Oropharynx sensation, carotid sinus/body Salivation (parotid gland) All sensation of posterior one-third of tongue Motor to one muscle—stylopharyngeus	Loss of gag reflex with X
X	Vagus	Mixed	To muscles of palate and pharynx for swallowing except tensor palati (V) and stylopharyngeus (IX) To all muscles of larynx (phonates) Sensory of larynx and laryngopharynx Sensory of GI tract To GI tract smooth muscle and glands in foregut and midgut	Nasal speech, nasal regurgitation Dysphagia, palate droop Uvula pointing away from affected side Hoarseness/fixed vocal cord Loss of gag reflex with IX Loss of cough reflex
CN	**Name**	**Type**	**Function**	**Results of Lesions**
XI	Accessory	Motor	Head rotation to opposite side (sternocleidomastoid) Elevates and rotates scapula (trapezius)	Weakness turning chin to opposite side Shoulder droop
XII	Hypoglossal	Motor	Tongue movement (styloglossus, hyoglossus, genioglossus, and intrinsic tongue muscles—palatoglossus is by X)	Tongue pointing toward same (affected) side on protrusion

Abbreviations: CN, cranial nerve; IO, inferior oblique; IR, inferior rectus; MR, medial rectus; MS, multiple sclerosis; SR, superior rectus

SENSORY AND MOTOR NEURAL SYSTEMS

Each of the following 5 ascending or descending neural tracts, fibers, or fasciculi courses through the brain stem and is found at every transverse sectional level.

The **medial lemniscus** (ML) contains the axons from cell bodies found in the dorsal column nuclei (gracilis and cuneatus) in the caudal medulla and represents the second neuron in the pathway to the thalamus and cortex for discriminative touch, vibration, pressure, and conscious proprioception. The axons in the ML cross the midline of the medulla immediately after emerging from the dorsal column nuclei. Lesions in the ML, in any part of the brain stem, result in a loss of discriminative touch, vibration, pressure, and conscious proprioception from the **contralateral** side of the body.

The **spinothalamic tract** (part of anterolateral system) has its cells of origin in the spinal cord and represents the crossed axons of the second neuron in the pathway conveying pain and temperature to the thalamus and cortex. Lesions of the spinothalamic tract, in any part of the brain stem, result in a loss of pain and temperature sensations from the **contralateral** side of the body.

The **corticospinal tract** controls the activity of lower motoneurons, and interneuron pools for lower motoneurons course through the brain stem on their way to the spinal cord. Lesions of this tract produce a spastic paresis in skeletal muscles of the body **contralateral** to the lesion site in the brain stem.

The **descending hypothalamic fibers** arise in the hypothalamus and course without crossing through the brain stem to terminate on preganglionic sympathetic neurons in the spinal cord. Lesions of this pathway produce an ipsilateral **Horner syndrome.** Horner syndrome consists of miosis (pupillary constriction), ptosis (drooping eyelid), and anhidrosis (lack of sweating) in the face ipsilateral to the side of the lesion.

Descending hypothalamic fibers course with the spinothalamic fibers in the lateral part of the brain stem. Therefore, brain stem lesions producing Horner syndrome may also result in a contralateral loss of pain and temperature sensations from the limbs and body.

The **medial longitudinal fasciculus** is a fiber bundle interconnecting centers for horizontal gaze, the vestibular nuclei, and the nerve nuclei of CN III, IV, and VI, which innervate skeletal muscles that move the eyeball. This fiber bundle courses close to the dorsal midline of the brain stem and also contains vestibulospinal fibers, which course through the medulla to the spinal cord. Lesions of the fasciculus produce **internuclear ophthalmoplegia** and disrupt the vestibulo-ocular reflex.

MEDULLA

In the caudal medulla, 2 of the neural systems—the corticospinal and dorsal column–medial lemniscal pathways—send axons across the midline. The nucleus gracilis and nucleus cuneatus give rise to axons that decussate in the caudal medulla (the crossing axons are the internal arcuate fibers), which then form and ascend in the medial lemniscus.

The corticospinal (pyramidal) tracts, which are contained in the pyramids, course ventromedially through the medulla. Most of these fibers decussate in the caudal medulla just below the crossing of axons from the dorsal column nuclei, and then travel down the spinal cord as the (lateral) corticospinal tract.

The olives are located lateral to the pyramids in the rostral two-thirds of the medulla. The olives contain the convoluted inferior olivary nuclei. The olivary nuclei send climbing (olivocerebellar) fibers into the cerebellum through the inferior cerebellar peduncle. The olives are a key distinguishing feature of the medulla.

The spinothalamic tract and the descending hypothalamic fibers course together in the lateral part of the medulla below the inferior cerebellar peduncle and near the spinal nucleus and tract of CN V.

Cranial Nerve Nuclei

Spinal nucleus of V

The spinal nucleus of the trigeminal nerve (CN V) is located in a position analogous to the dorsal horn of the spinal cord. The spinal tract of the trigeminal nerve lies just lateral to this nucleus and extends from the upper cervical cord (C2) to the point of entry of the fifth cranial nerve in the pons. Central processes from cells in the trigeminal ganglion conveying pain and temperature sensations from the face enter the brain stem in the rostral pons but descend in the spinal tract of CN V and synapse on cells in the spinal nucleus.

Solitary nucleus

The solitary nucleus receives the axons of all general and special visceral afferent fibers carried into the CNS by CN VII, IX, and X. These include taste, cardiorespiratory, and gastrointestinal sensations carried by these cranial nerves. Taste and visceral sensory neurons all have their cell bodies in ganglia associated with CN VII, IX, and X outside the CNS.

Nucleus ambiguus

The nucleus ambiguus is a column of large motoneurons situated dorsal to the inferior olive. Axons arising from cells in this nucleus course in the ninth and tenth cranial nerves. The component to the ninth nerve is insignificant. In the tenth nerve, these fibers supply muscles of the soft palate, larynx, pharynx, and upper esophagus. A unilateral lesion will produce ipsilateral paralysis of the soft palate causing the uvula to deviate away from the lesioned nerve and nasal regurgitation of liquids, weakness of laryngeal muscles causing hoarseness, and pharyngeal weakness resulting in difficulty in swallowing.

Dorsal motor nucleus of CN X

These visceral motoneurons of CN X are located lateral to the hypoglossal nucleus in the floor of the fourth ventricle. This is a major parasympathetic nucleus of the brain stem, and it supplies preganglionic fibers innervating terminal ganglia in the thorax and the foregut and midgut parts of the gastrointestinal tract.

Hypoglossal nucleus

The hypoglossal nucleus is situated near the midline just beneath the central canal and fourth ventricle. This nucleus sends axons into the hypoglossal nerve to innervate all of the tongue muscles except the palatoglossus.

The accessory nucleus

The accessory nucleus is found in the cervical spinal cord. The axons of the spinal accessory nerve arise from the accessory nucleus, pass through the foramen magnum to enter the cranial cavity, and join the fibers of the vagus to exit the cranial cavity through the jugular foramen. As a result, intramedullary lesions do not affect fibers of the spinal accessory nerve. The spinal accessory nerve supplies the sternocleidomastoid and trapezius muscles.

The rootlets of the glossopharyngeal (CN IX) and vagus (CN X) nerves exit between the olive and the fibers of the inferior cerebellar peduncle. The hypoglossal nerve (CN XII) exits more medially between the olive and the medullary pyramid.

PONS

The pons is located between the medulla (caudally) and the midbrain (rostrally). The cerebellum overlies the pons. It is connected to the brain stem by 3 pairs of cerebellar peduncles. The fourth ventricle is found between the dorsal surface of the pons and the cerebellum. The ventral surface of the pons is dominated by fibers, which form a large ventral enlargement that carries fibers from pontine nuclei to the cerebellum in the middle cerebellar peduncle. This ventral enlargement is the key distinguishing feature of the pons.

The corticospinal tracts are more diffuse in the pons than in the medulla and are embedded in the transversely coursing fibers that enter the cerebellum in the middle cerebellar peduncle.

The medial lemniscus is still situated near the midline but is now separated from the corticospinal tracts by the fibers forming the middle cerebellar peduncle. The medial lemniscus has changed from a dorsoventral orientation in the medulla to a more horizontal orientation in the pons.

The spinothalamic tract and the descending hypothalamic fibers continue to course together in the lateral pons.

The lateral lemniscus, an ascending auditory pathway, is lateral and just dorsal to the medial lemniscus. The lateral lemniscus carries the bulk of ascending auditory fibers from both cochlear nuclei to the inferior colliculus of the midbrain.

The medial longitudinal fasciculus (MLF) is located near the midline just beneath the fourth ventricle.

Cranial Nerve Nuclei

Abducens nucleus

The abducens nucleus is found near the midline in the floor of the fourth ventricle just lateral to the MLF.

Facial motor nucleus

The facial motor nucleus is located ventrolateral to the abducens nucleus. Fibers from the facial nucleus curve around the posterior side of the abducens nucleus (the curve forms the internal genu of the facial nerve), then pass ventrolaterally to exit the brain stem at the pontomedullary junction.

Superior olivary nucleus

The superior olivary nucleus lies immediately ventral to the nucleus of CN VII and receives auditory impulses from both ears by way of the cochlear nuclei. The cochlear nuclei are found at the pontomedullary junction just lateral to the inferior cerebellar peduncle.

Vestibular nuclei

The vestibular nuclei are located near the posterior surface of the pons lateral to the abducens nucleus, and extend into the medulla.

Cochlear nuclei

The dorsal and ventral cochlear nuclei are found at the pontomedullary junction. All of the fibers of the cochlear part of CN VIII terminate here.

Trigeminal nuclei

Motor Nucleus—Pons

The motor nucleus of CN V is located in the pons just medial to the main sensory nucleus of the trigeminal and adjacent to the point of exit or entry of the trigeminal nerve fibers. These motor fibers supply the muscles of mastication (masseter, temporalis, and medial and lateral pterygoid (Figure IV-5-3).

Main Sensory Nucleus—Pons

The main sensory nucleus is located just lateral to the motor nucleus.

The main sensory nucleus receives tactile and pressure sensations from the face, scalp, oral cavity, nasal cavity, and dura.

Spinal Trigeminal Nucleus—Spinal cord to pons

The spinal trigeminal nucleus is a caudal continuation of the main sensory nucleus, extending from the mid pons through the medulla to the cervical cord. Central processes from cells in the trigeminal ganglion conveying pain and temperature sensations from the face descend in the spinal tract of V and synapse on cells in the spinal nucleus.

Note

VPM relays touch, pain, temperature (CN V) and taste (CN VII, IX) sensations to cortex.

Mesencephalic Nucleus—Midbrain

The mesencephalic nucleus of CN V is located at the point of entry of the fifth nerve and extends into the midbrain. It receives proprioceptive input from joints, muscles of mastication, extraocular muscles, teeth, and the periodontium. Some of these fibers synapse monosynaptically on the motoneurons, forming the sensory limb of the jaw jerk reflex.

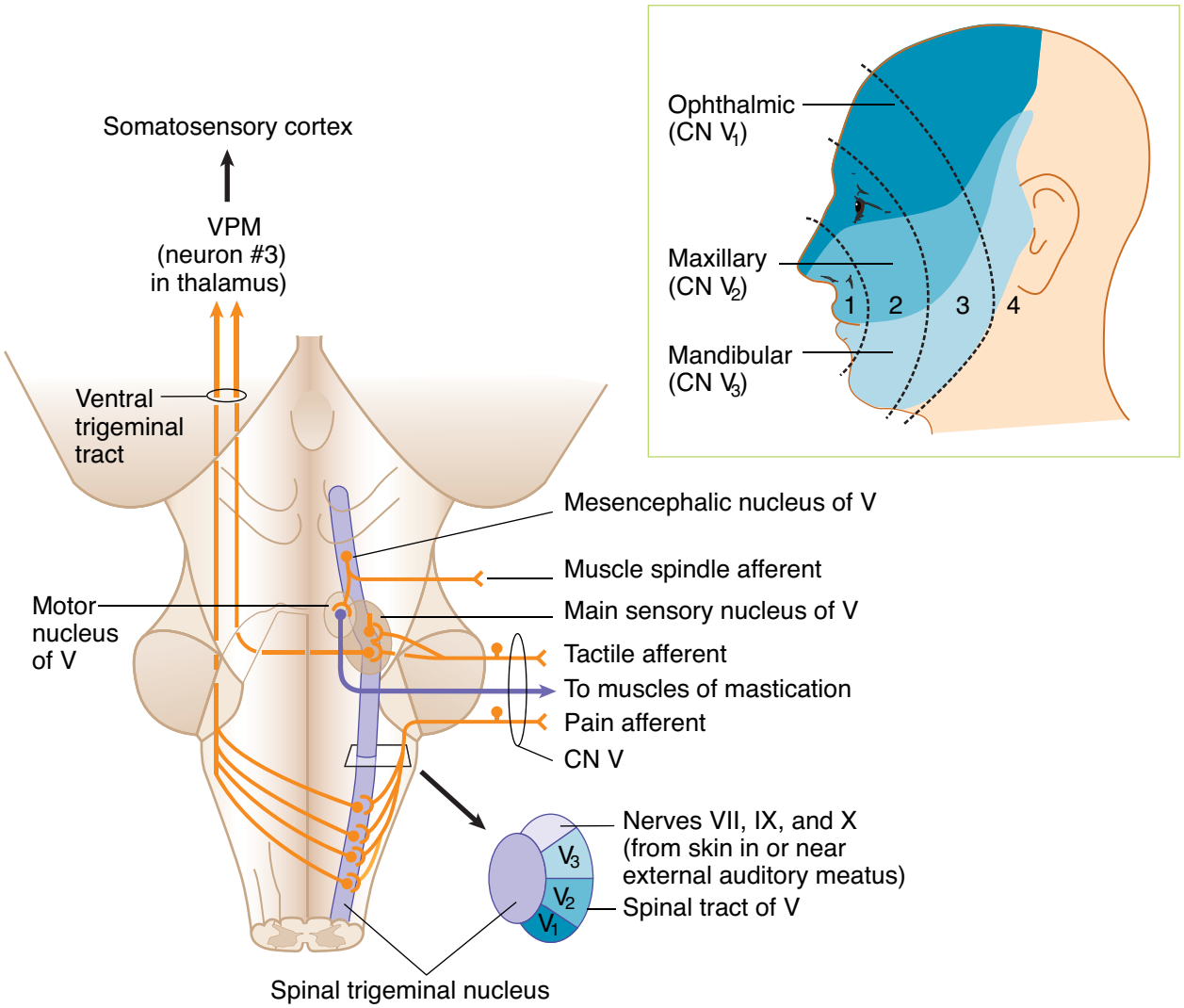

Figure III.5.5 Shaded areas indicate regions of face and scalp innervated by branches of the 3 divisions of CN V.

Dotted lines indicate concentric numbered "onion-skin" regions emanating posteriorly from nose and mouth that have a rostral to caudal representation in the spinal nucleus of V in the brain stem.

Cranial Nerves V, VI, VII, and VIII

Four cranial nerves emerge from the pons. Cranial nerves VI, VII, and VIII emerge from the pontomedullary junction. The facial nerve is located medial to the vestibulocochlear nerve. The abducens nerve (CN VI) emerges near the midline lateral to the corticospinal tract. The trigeminal nerve (CN V) emerges from the middle of the pons.

MIDBRAIN

The midbrain (mesencephalon) is located between the pons and diencephalon. The cerebral aqueduct, a narrow channel that connects the third and fourth ventricles, passes through the midbrain. The inferior colliculi and superior colliculi are found on the dorsal aspect of the midbrain above the cerebral aqueduct. The inferior colliculus processes auditory information received bilaterally from the cochlear nuclei by axon fibers of the lateral lemniscus. The superior colliculi help direct movements of both eyes in gaze. The pretectal region is located just beneath the superior colliculi and in front of the oculomotor complex. This area contains interneurons involved in the pupillary light reflex. The massive cerebral peduncles extend ventrally from the midbrain. The cerebral peduncles contain corticospinal and corticobulbar fibers. The interpeduncular fossa is the space between the cerebral peduncles.

The substantia nigra is the largest nucleus of the midbrain. It appears black to dark brown in the freshly cut brain because nigral cells contain melanin pigments. Neurons in the substantia nigra utilize Dopamine and GABA as neurotransmitters.

The medial lemniscus and spinothalamic tract and descending hypothalamic fibers course together ventrolateral to the periaqueductal gray.

The MLF continues to be located near the midline, just beneath the cerebral aqueduct.

The mesencephalic nuclei of the trigeminal nerve are located on either side of the central gray.

Cranial Nerve Nuclei

The trochlear nucleus is located just beneath the periaqueductal gray near the midline between the superior and inferior colliculi. The oculomotor nucleus and the nucleus of Edinger-Westphal are found just beneath the periaqueductal gray near the midline at the level of the superior colliculi.

Two cranial nerves emerge from the midbrain: the oculomotor (CN III) and the trochlear (CN IV) nerves.

The **oculomotor nerve** arises from the oculomotor nucleus and exits ventrally from the midbrain in the interpeduncular fossa. CN III also contains preganglionic parasympathetic axons that arise from the nucleus of Edinger-Westphal, which lies adjacent to the oculomotor nucleus.

Axons of the **trochlear nerve** decussate in the superior medullary velum and exit the brain stem near the posterior midline just inferior to the inferior colliculi.

Corticobulbar (Corticonuclear) Innervation of Cranial Nerve Nuclei

Corticobulbar fibers serve as the source of upper motoneuron innervation of lower motoneurons in cranial nerve nuclei. Corticobulbar fibers arise in the motor cortex and influence lower motoneurons in all brain stem nuclei that innervate skeletal muscles. This includes:

- Muscles of mastication (CN V)
- Muscles of facial expression (CN VII) – (partially bilateral)
- Palate, pharynx, and larynx (CN X)
- Tongue (CN XII)
- Sternocleidomastoid and trapezius muscles (CN XI)

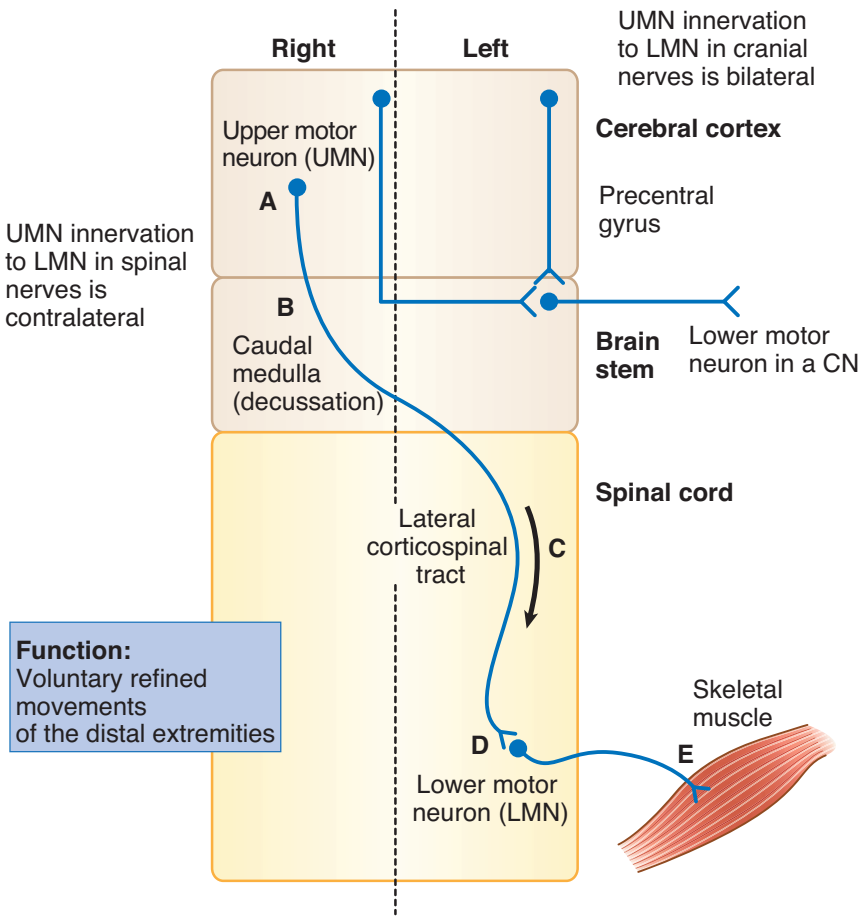

Figure III-5-6. Upper Motor Neuron Innervation of Spinal Nerves and Cranial Nerves

The corticobulbar innervation of cranial nerve lower motoneurons is predominantly bilateral, in that each lower motoneuron in a cranial nerve nucleus receives input from corticobulbar axons arising from both the right and the left cerebral cortex. T he major exception is that only some of the LMNs of the facial nerve (CN VII) receive a contralateral innervation.

Clinical Correlate

Facial Paralysis

The upper motoneuron innervation of lower motoneurons in the facial motor nucleus is different and clinically significant. Like most cranial nerve lower motoneurons, the corticobulbar innervation of facial motoneurons to muscles of the upper face (which wrinkle the forehead and shut the eyes) is bilateral. The corticobulbar innervation of facial motoneurons to muscles of the mouth, however, is contralateral only. Clinically, this means that one can differentiate between a lesion of the seventh nerve and a lesion of the corticobulbar fibers to the facial motor nucleus.

A facial nerve lesion (as in **Bell Palsy**) will result in a complete ipsilateral paralysis of muscles of facial expression, including an inability to wrinkle the forehead or shut the eyes and a drooping of the corner of the mouth. A corticobulbar lesion will result in only a drooping of the corner of the mouth on the contralateral side of the face and no other facial motor deficits. Generally, no other cranial deficits will be seen with corticobulbar lesions because virtually every other cranial nerve nucleus is bilaterally innervated. In some individuals, the hypoglossal nucleus may receive mainly contralateral corticobulbar innervation. If these corticobulbar fibers are lesioned, the tongue muscles undergo transient weakness without atrophy or fasciculations and may deviate away from the injured corticobulbar fibers. If, for example, the lesion is in corticobulbar fibers on the left, there is transient weakness of the right tongue muscles, causing a deviation of the tongue toward the right side upon protrusion.

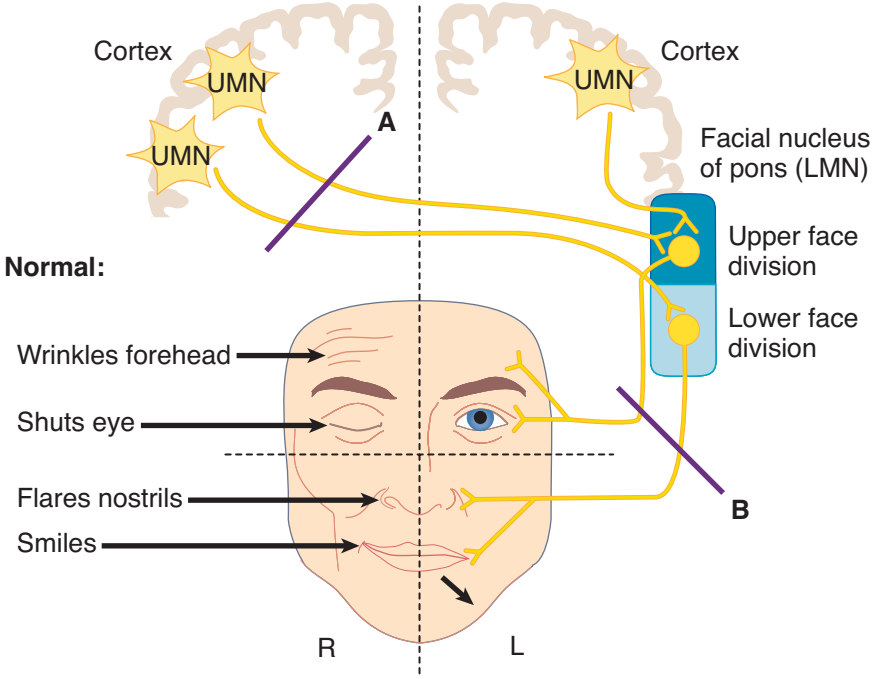

Figure III-5-7. Corticobulbar Innervation of the Facial Motor Nucleus

Clinical Correlate

Lesion A: left lower face weakness

Lesion B: complete left face weakness

Abbreviations

UMN = upper motoneuron

LMN = lower motoneuron

EAR, AUDITORY, AND VESTIBULAR SYSTEMS

Each ear consists of 3 components: 2 air-filled spaces, the external ear and the middle ear; and the fluid-filled spaces of the inner ear.

The external ear includes the pinna and the external auditory meatus, which extends to the tympanic membrane. Sound waves travel through the external auditory canal and cause the tympanic membrane (eardrum) to vibrate. Movement of the eardrum causes vibrations of the ossicles in the middle ear (i.e., the malleus, incus, and stapes). Vibrations of the ossicles are transferred through the oval window and into the inner ear.

The middle ear lies in the temporal bone, where the chain of 3 ossicles connects the tympanic membrane to the oval window. These auditory ossicles amplify the vibrations received by the tympanic membrane and transmit them to the fluid of the inner ear with minimal energy loss. The malleus is inserted in the tympanic membrane, and the stapes is inserted into the membrane of the oval window. Two small skeletal muscles, the tensor tympani and the stapedius, contract to prevent damage to the inner ear when the ear is exposed to loud sounds. The middle-ear cavity communicates with the nasopharynx via the eustachian tube, which allows air pressure to be equalized on both sides of the tympanic membrane.

The inner ear consists of a labyrinth (osseous and membranous) of interconnected sacs (utricle and saccule) and channels (semicircular ducts and the cochlear duct) that contain patches of receptor or hair cells that respond to airborne vibrations or movements of the head. Both the cochlear duct and the sacs and channels of the vestibular labyrinth are filled with endolymph, which bathes the hairs of the hair cells. Endolymph is unique because it has the inorganic ionic composition of an intracellular fluid but it lies in an extracellular space. The intracellular ionic composition of endolymph is important for the function of hair cells. Perilymph, ionically like a typical extracellular fluid, lies outside the endolymph-filled labyrinth.

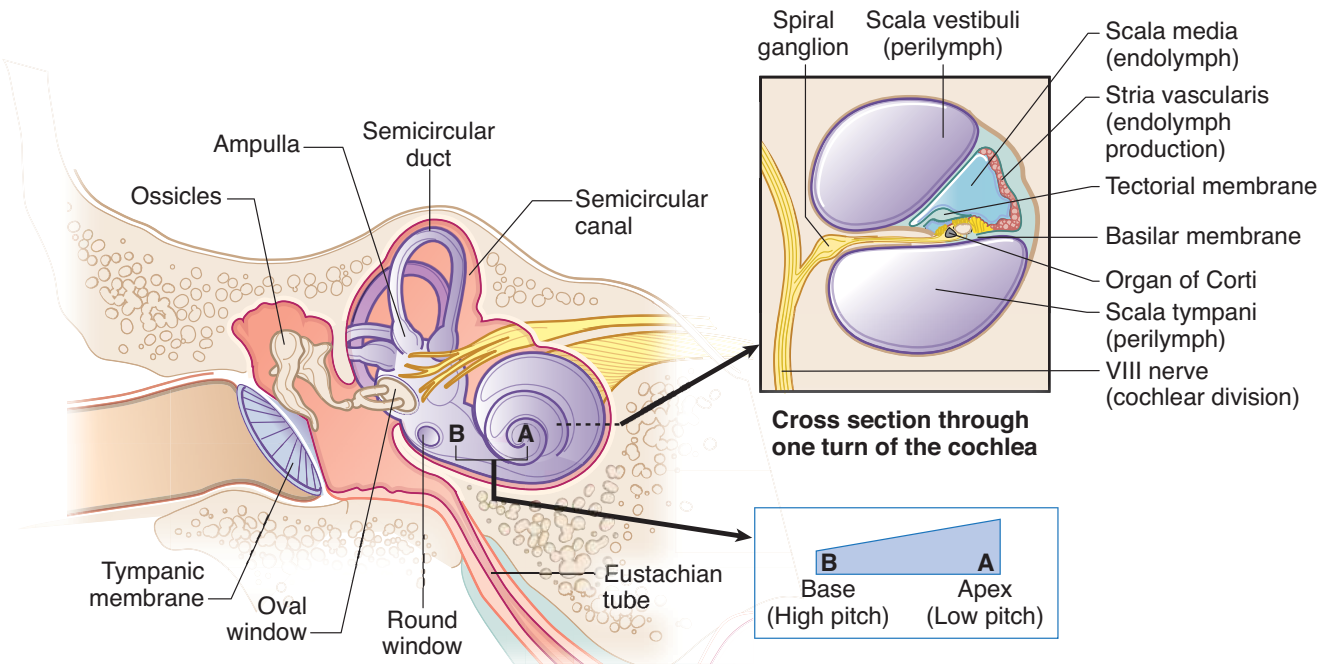

Figure III-5-8. Structures of the Inner Ear

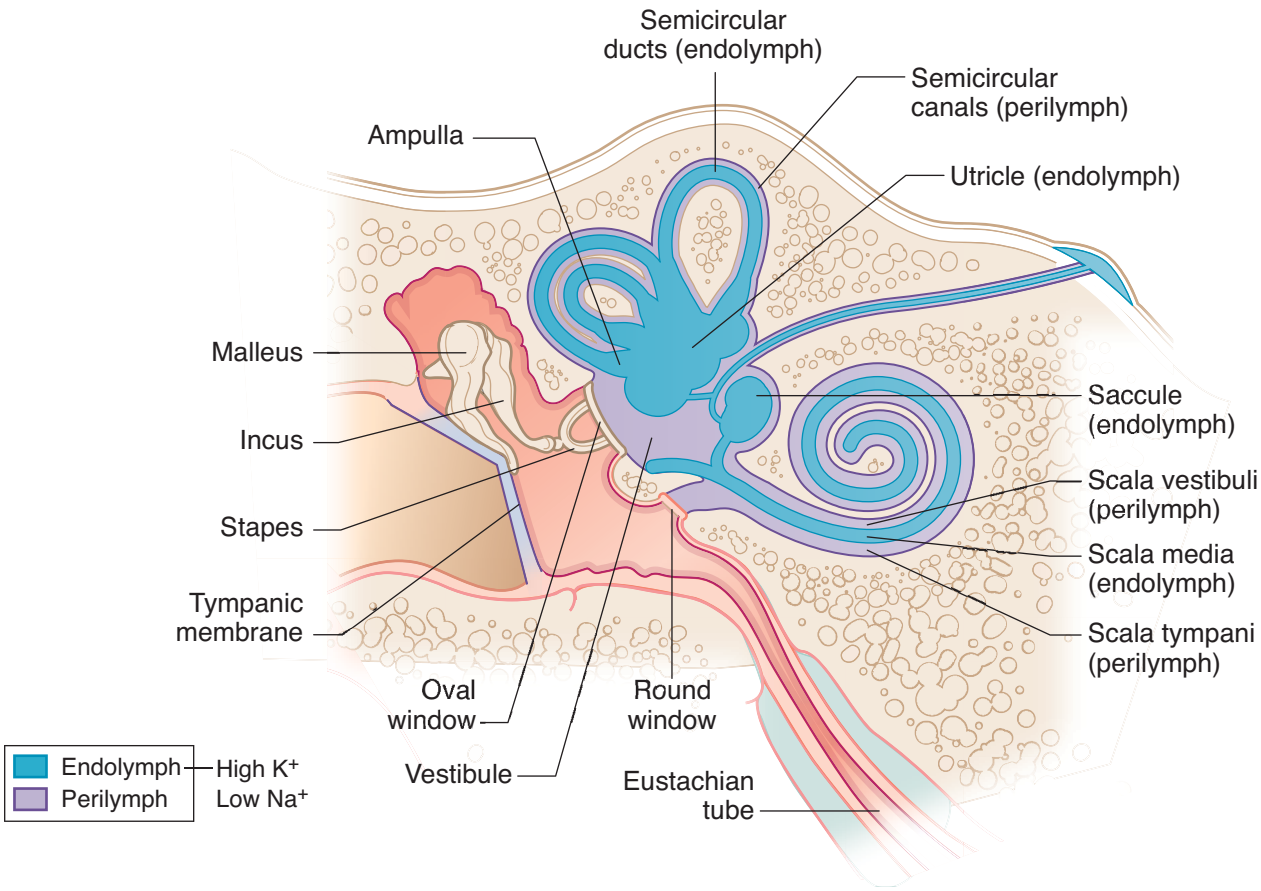

Figure III-5-9. Distribution of Endolymph and Perilymph in Inner Ear

Auditory System

The **cochlear duct** is the auditory receptor of the inner ear. It contains hair cells, which respond to airborne vibrations transmitted by the ossicles to the oval window. The cochlear duct coils 2 and a quarter turns within the bony cochlea and contains hair cells situated on an elongated, highly flexible, basilar membrane. High-frequency sound waves cause maximum displacement of the basilar membrane and stimulation of hair cells at the base of the cochlea, whereas low-frequency sounds maximally stimulate hair cells at the apex of the cochlea.

The **spiral ganglion** contains cell bodies whose peripheral axons innervate auditory hair cells of the organ of Corti. The central axons from these bipolar cells form the cochlear part of the eighth cranial nerve. All of the axons in the cochlear part of the eighth nerve enter the pontomedullary junction and synapse in the ventral and dorsal cochlear nuclei. Axons of cells in the ventral cochlear nuclei bilaterally innervate the superior olivary nuclei in the pons. The superior olivary nuclei are the first auditory nuclei to receive binaural input and use the binaural input to localize sound sources. The lateral lemniscus carries auditory input from the cochlear nuclei and the superior olivary nuclei to the inferior colliculus in the midbrain. Each lateral lemniscus carries information derived from both ears; however, input from the contralateral ear predominates.

Clinical Correlate

Middle-ear diseases (otitis media, otosclerosis) result in a conductive hearing loss because of a reduction in amplification provided by the ossicles.

Lesions of the facial nerve in the brain stem or temporal bone (Bell palsy) may result in hyperacusis, an increased sensitivity to loud sounds.

Clinical Correlate

Presbycusis results from a loss of hair cells at the base of the cochlea.

Clinical Correlate

Sensorineural hearing loss: air conduction > bone conduction

Conductive hearing loss: bone conduction > air conduction

The **inferior colliculus** sends auditory information to the medial geniculate body (MGB) of the thalamus. From the MGB, the auditory radiation projects to the primary auditory cortex located on the posterior portion of the transverse temporal gyrus (Heschl's gyrus; Brodmann areas 41 and 42). The adjacent auditory association area makes connections with other parts of the cortex, including Wernicke's area, the cortical area for the comprehension of language.

Clinical Correlate

Lesions Causing Hearing Loss

Lesions of the cochlear part of the eighth nerve or cochlear nuclei inside the brain stem at the pontomedullary junction result in a profound unilateral sensorineural hearing loss (A). All other lesions to auditory structures in the brain stem, thalamus, or cortex result in a bilateral suppression of hearing and a decreased ability to localize a sound source (B). If a patient presents with a significant hearing loss in one ear, the lesion is most likely in the middle ear, inner ear, eighth nerve, or cochlear nuclei, and not at higher levels of the auditory system.

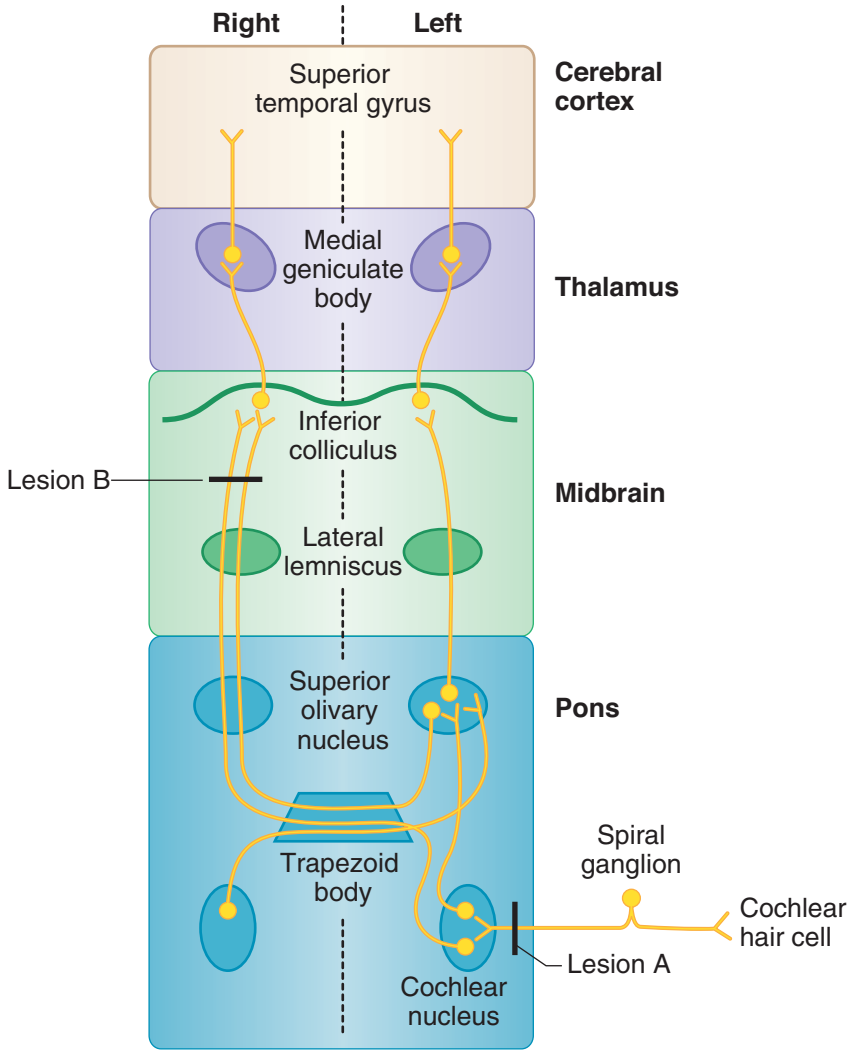

Figure III-5-10. Auditory System

Hearing Loss

Conductive: passage of sound waves through external or middle ear is interrupted. Causes: obstruction, otosclerosis, otitis media

Sensorineural: damage to cochlea, CN VIII, or central auditory connections

Auditory Tests

Weber test: place tuning fork on vertex of skull. If **unilateral conductive loss** → vibration is louder in affected ear; if **unilateral sensorineural loss** → vibration is louder in normal ear.

Rinne test: place tuning fork on mastoid process (bone conduction) until vibration is not heard, then place fork in front of ear (air conduction). If **unilateral conductive loss** → no air conduction after bone conduction is gone; if **unilateral sensorineural loss** → air conduction present after bone conduction is gone.

Vestibular System

Sensory receptors

The vestibular system contains 2 kinds of sensory receptors, one kind in the utricle and the saccule and the other in the semicircular ducts.

The utricle and the saccule are 2 large sacs, each containing a patch of hair cells in a macula. Each macula responds to linear acceleration and detects positional changes in the head relative to gravity. There are 3 semicircular ducts in the inner ear, each lying in a bony semicircular canal. Each semicircular duct contains an ampullary crest of hair cells that detect changes in angular acceleration resulting from circular movements of the head. The 3 semicircular ducts—anterior, posterior, and horizontal—are oriented such that they lie in the 3 planes of space. Circular movements of the head in any plane will depolarize hair cells in a semicircular duct in one labyrinth and hyperpolarize hair cells in the corresponding duct in the opposite labyrinth.

Vestibular nuclei

There are 4 vestibular nuclei located in the rostral medulla and caudal pons. The vestibular nuclei receive afferents from the vestibular nerve, which innervates receptors located in the semicircular ducts, utricle, and saccule. Primary vestibular fibers terminate in the vestibular nuclei and the flocculonodular lobe of the cerebellum.

Vestibular fibers

Secondary vestibular fibers, originating in the vestibular nuclei, join the MLF and supply the motor nuclei of CN III, IV, and VI. These fibers are involved in the production of conjugate eye movements. These compensatory eye movements represent the efferent limb of the vestibulo-ocular reflex, which enables the eye to remain focused on a stationary target during movement of the head or neck. Most of our understanding of the vestibulo-ocular reflex is based on horizontal head turning and a corresponding horizontal movement of the eyes in the direction opposite to that of head turning. For example, when the head turns horizontally to the right, both eyes will move to the left using the following vestibulo-ocular structures. Head turning to the right stimulates hairs cells in the right semicircular ducts. The right eighth nerve increases its firing rate to the right vestibular nuclei. These nuclei then send axons by way of the MLF to the right oculomotor nucleus and to the left abducens nucleus. The right oculomotor nerve to the right medial rectus adducts the right eye, and the left abducens nerve to the left lateral rectus abducts the left eye. The net effect of stimulating these nuclei is that both eyes will look to the left.

Note

Vestibular Functions:

- Equilibrium
- Posture
- VOR

Clinical Correlate

A lesion of the vestibular nuclei or nerve (in this example, on the left) produces a vestibular nystagmus with a slow deviation of the eyes toward the lesion and a fast correction back to the right.

Vestibular System (VIII)

Three semicircular ducts respond to **angular acceleration and deceleration** of the head. The **utricle** and **saccule** respond to **linear acceleration** and the pull of **gravity**. There are 4 **vestibular nuclei** in the medulla and pons, which receive information from CN VIII. Fibers from the vestibular nuclei join the MLF and supply the motor nuclei of CNs III, IV, and VI, thereby regulating conjugate eye movements. Vestibular nuclei also receive and send information to the **flocculonodular lobe** of the cerebellum.

Vestibulo-Ocular Reflex

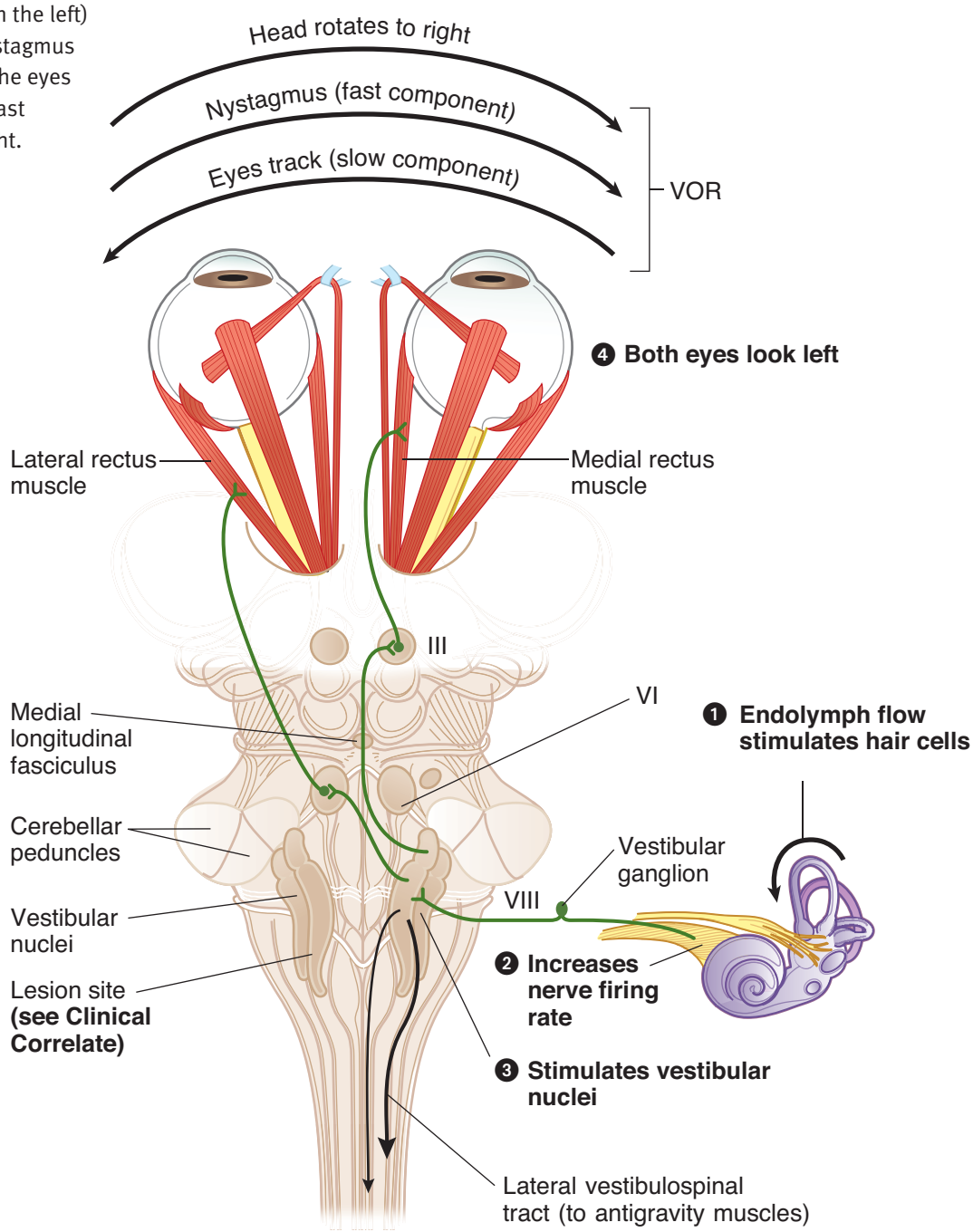

Figure III-5-11. Vestibulo-Ocular Reflex (VOR)

Caloric Test

This stimulates the horizontal semicircular ducts; can be used as a test of brain-stem function in unconscious patients.

Normal results:

- **Cold water** irrigation of ear → nystagmus to opposite side
- **Warm water** irrigation of ear → nystagmus to same side
- **COWS:** cold opposite, warm same

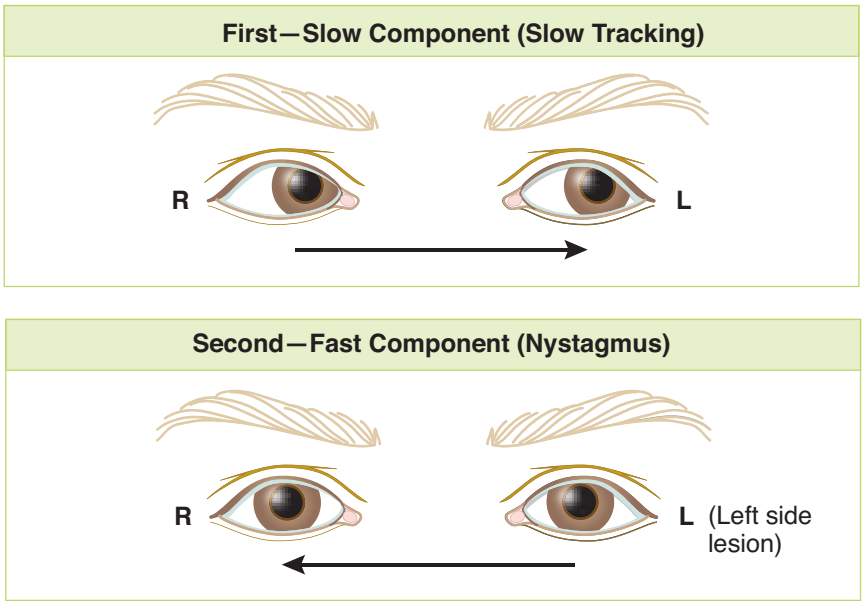

Figure III-5-12. Vestibular System

Clinical Correlate

Vestibular dysfunction may result from a peripheral or central lesion.

Vertigo may result from a lesion of the peripheral (end organ, nerve) or central (nuclear, brain-stem pathways) vestibular structures. Vertigo refers to the perception of rotation, which may involve either the subject or the external space. The vertigo is usually severe in peripheral disease and mild in brain-stem disease. Chronic vertigo (i.e., persisting longer than 2–3 weeks) strongly suggests a central lesion. Vertigo may also be caused by a variety of drugs, including anticonvulsants, aspirin, alcohol, and certain sedatives and antibiotics.

Ménière disease is characterized by abrupt, recurrent attacks of vertigo lasting minutes to hours accompanied by tinnitus or deafness and usually involving only one ear. Nausea and vomiting and a sensation of fullness or pressure in the ear also are common during the acute episode. The attacks are often severe, and the patient may be unable to stand. The disease usually occurs in middle age and results from distention of the fluid spaces in the cochlear and vestibular parts of the labyrinth.

Eye Movement Control Systems

For the eyes to move together **(conjugate gaze)**, the oculomotor nuclei and abducens nuclei are interconnected by the **medial longitudinal fasciculus (MLF)**.

Horizontal gaze is controlled by 2 gaze centers: **frontal eye field** (contralateral gaze), and **PPRF** (paramedian pontine reticular formation, ipsilateral gaze).

Nystagmus

Nystagmus refers to rhythmic oscillations of the eyes slowly to one side followed by a rapid reflex movement in the opposite direction. Nystagmus is defined by the direction of the rapid reflex movement or the fast phase. It is usually horizontal, although rotatory or vertical nystagmus may also occur.

Unilateral vestibular nerve or vestibular nucleus lesions may result in a vestibular nystagmus. In a pathologic vestibular nystagmus, the initial slow phase is the response to the pathology, and the fast phase is the correction attempt made by the cortex in response to the pathology. Consider this example: if the left vestibular nerve or nuclei are lesioned, because of the loss of balance between the 2 sides, the right vestibular nuclei are unopposed and act as if they have been stimulated, causing both eyes to look slowly to the left. This is the slow phase of a pathologic vestibular nystagmus. Because the head did not move, the cortex responds by moving both eyes quickly back to the right, the direction of the fast phase of the nystagmus.

Note

To remember the direction of the fast phase of vestibular nystagmus in a caloric test **toward the warm-water side** and **away from the cool-water side**, remember the mnemonic COWS:

- Cool
- Opposite
- Warm
- Same

The integrity of the vestibulo-ocular reflex can be an indicator of brain-stem integrity in comatose patients. To test this reflex, a vestibular nystagmus is induced by performing a **caloric test** in which an examiner introduces warm or cool water into an external auditory meatus. Warm water introduced into the external ear stimulates the horizontal semicircular duct and causes the eyes to move slowly in the opposite direction. Because the head did not turn, the eyes are moved quickly back by the cortex (if intact) toward the same ear where the warm water was introduced, producing a fast phase of nystagmus to the same side. Introduction of cool water into the external ear mimics a lesion; the horizontal duct activity is inhibited on the cool water side, and the opposite vestibular complex moves the eyes slowly toward the cool-water ear. The corrective or fast phase of the nystagmus moves the eyes quickly away from the ear where the cool water was introduced.

HORIZONTAL CONJUGATE GAZE

The eyeballs move together in conjugate gaze. The ocular muscles function to move and position both eyes as a unit so that an image falls on a corresponding spot on the retina of each eye. The slightest weakness in the movements of one eye causes diplopia, the presence of a double image, indicating that the image has been shifted to a different position on the retina of the affected side. Although gaze in all planes is possible, the muscles and cranial nerves involved in horizontal conjugate gaze, or abduction and adduction of both eyes together, are the most important eye movements.

Abduction of each eyeball is performed largely by the lateral rectus muscle, which is innervated by the abducens nerve (CN VI). Adduction of the eyeball is performed by the medial rectus muscle, which is innervated by the oculomotor nerve (CN III). Therefore, for both eyes to look to the right in horizontal gaze, the right abducens nerve and the right lateral rectus muscle must be active to abduct the right eye, and the left oculomotor nerve and the left medial rectus muscle must be active to adduct the left eye. The net effect is that both eyes will look to the right.

In the brain stem, the abducens nucleus (CN VI) and the oculomotor nucleus (CN III) are situated close to the midline just beneath the fourth ventricle or the cerebral aqueduct, in the pons and midbrain. These nuclei are interconnected by the fibers in the MLF. It is the fibers in the MLF that permit conjugate gaze, either when the target moves or when the head moves, through their interconnections to gaze centers and the vestibular system.

Control of Horizontal Gaze

Horizontal gaze is controlled by 2 interconnected gaze centers. One control center is in the frontal lobe, the frontal eye field (Brodmann area 8). This area acts as a center for **contralateral** horizontal gaze. In the pons is a second gaze center, known as the pontine gaze center or the PPRF, the paramedian pontine reticular formation. This is a center for **ipsilateral** horizontal gaze. When activated by neurons in the frontal eye field, the pontine gaze center neurons send axons to synapse with cell bodies in the abducens nucleus, which is actually contained within the pontine gaze center. The pontine gaze center also sends axons that cross immediately and course in the contralateral MLF to reach the contralateral oculomotor nucleus. The net effect of stimulation of the left frontal eye field, therefore, is activation of the pontine gaze center on the right and a saccadic horizontal eye movement of both eyes to the right. Horizontal gaze to the right results from activation of the right abducens nucleus and the left oculomotor nucleus by fibers in the MLF.

Lesions in the MLF result in an internuclear ophthalmoplegia in which there is an inability to adduct one eye on attempted gaze to the opposite side. For example, a lesion in the right MLF results in an inability to adduct the right eye on an attempted gaze to the left. The left eye abducts normally but exhibits a nystagmus. If the MLF is lesioned bilaterally (as might be the case in multiple sclerosis), neither eye adducts on attempted gaze (Figures III-5-13 and III-5-14), and the abducting eye exhibits a nystagmus.

Lesion sites are indicated by 1–4.

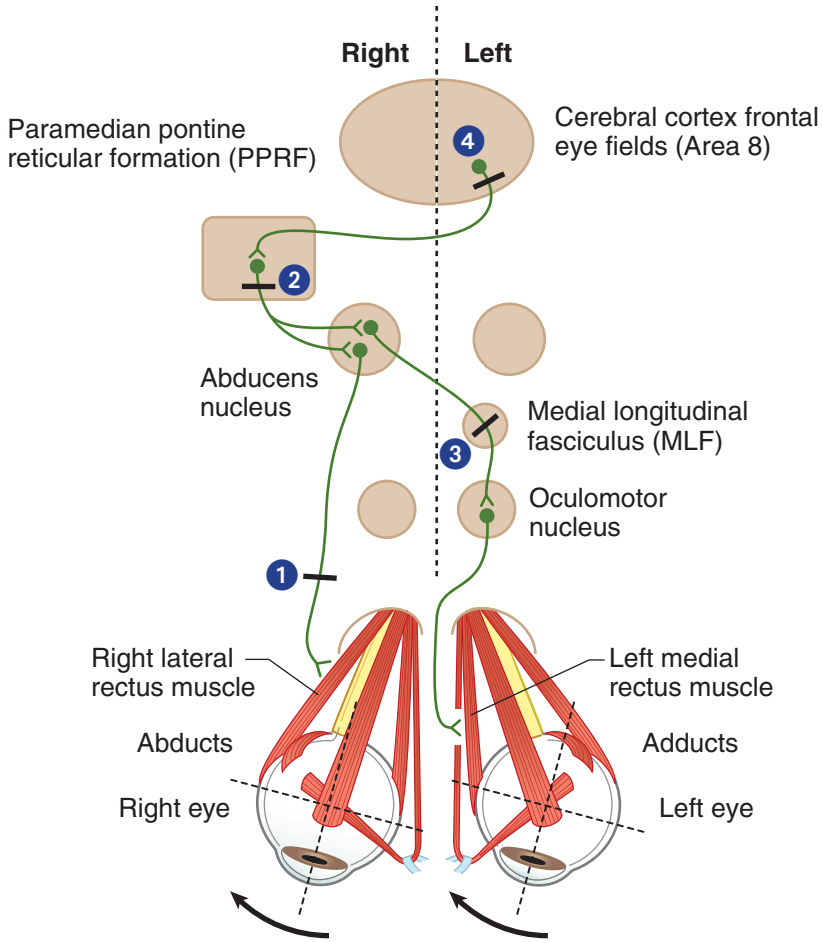

Figure III-5-13. Voluntary Horizontal Conjugate Gaze

Table III-5-2. Clinical Correlate

Lesion Examples	Symptoms
1. Right CN VI	Right eye cannot look right
2. Right PPRF	Neither eye can look right
3. Left MLF	**Internuclear ophthalmoplegia (INO)** Left eye cannot look right; convergence is intact (this is how to distinguish an INO from an oculomotor lesion); right eye has nystagmus; seen in multiple sclerosis
4. Left frontal eye field	Neither eye can look right; but slow drift to left

Abbreviations: MLF, medial longitudinal fasciculus; PPRF, paramedian pontine reticular formation

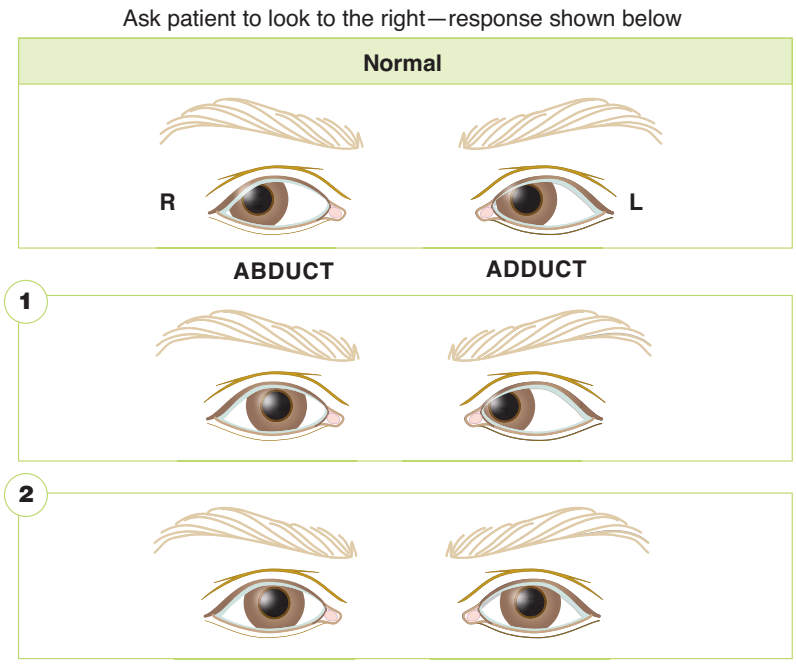

Figure III-5-14. Normal and Abnormal Horizontal Gaze

Clinical Correlate

The abducens nucleus is coexistent with the PPRF, the center for ipsilateral horizontal gaze. Lesions result in an inability to look to the lesion side, and may include a complete ipsilateral facial paralysis because the VIIth nerve fibers loop over the CN VI nucleus.

Table III-5-3. Normal/Abnormal Responses to Horizontal Conjugate Gaze: Part 1

Lesion Location	Symptoms (Results)
Right Abducens nerve, #1	Right eye cannot look right (abduct)
Right Abducens nucleus, #2	Neither eye can look right (lateral gaze paralysis)—may be slow drift left and complete **right facial paralysis**

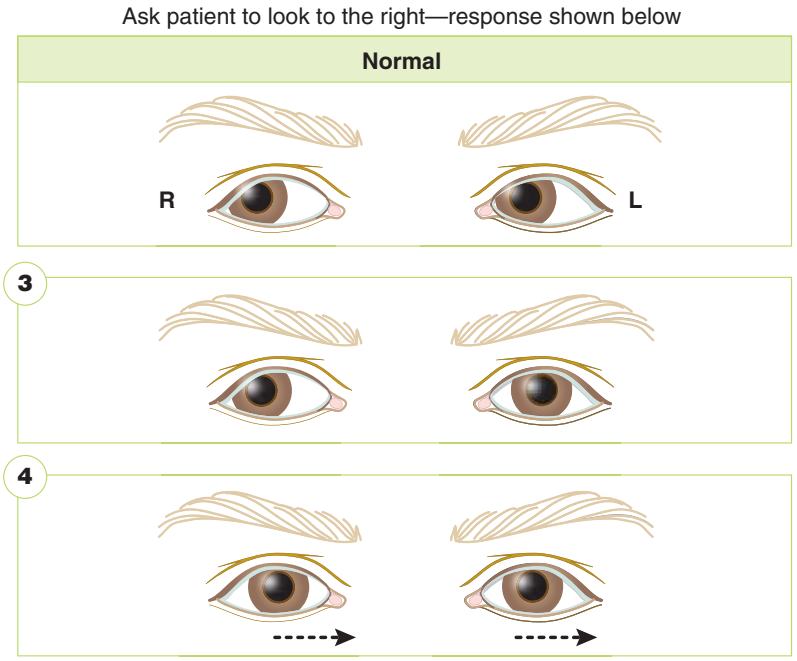

Figure III-5-15. Normal and Abnormal Horizontal Gaze

Table III-5-4. Normal/Abnormal Responses to Horizontal Gaze: Part 2

Lesion Location	Symptoms (Results)
Left MLF, #3 Internuclear ophthalmoplegia	Left eye cannot look right; convergence intact; right eye exhibits nystagmus
Left cerebral cortex, #4	Neither eye can look right: but slow drift to left; may be seen with right lower face weakness and right upper limb weakness
Abbreviation: MLF, medial longitudinal fasciculus	

BLOOD SUPPLY TO THE BRAIN STEM

Vertebral Artery

This artery is a branch of the subclavian that ascends through the foramina of the transverse processes of the upper 6 cervical vertebrae. It enters the posterior fossa by passing through the foramen magnum. The vertebral arteries continue up the ventral surface of the medulla and, at the caudal border of the pons, join to form the basilar artery.

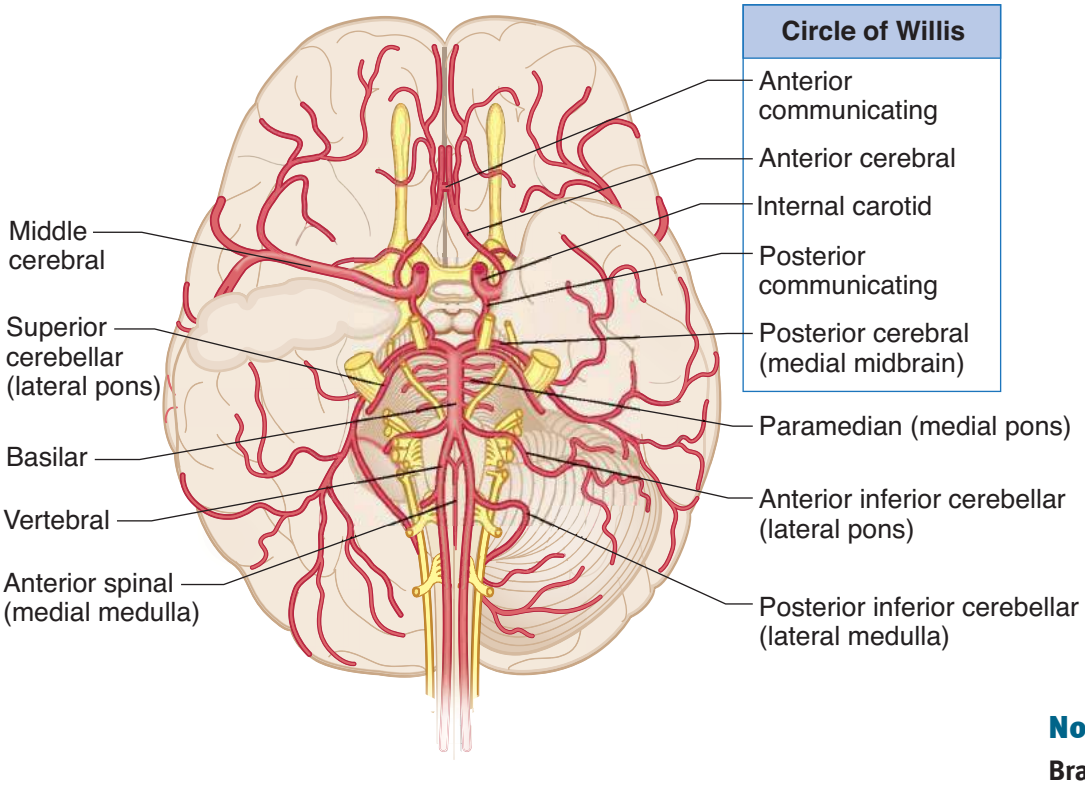

Figure III-5-16. Arterial Supply of the Brain

Branches of the vertebral artery include: the anterior spinal artery, which supplies the ventrolateral two-thirds of the cervical spinal cord and the ventromedial part of the medulla; and the posterior inferior cerebellar artery (PICA), which supplies the cerebellum and the dorsolateral part of the medulla.

Basilar Artery

The basilar artery is formed by the joining of the 2 vertebral arteries at the pontomedullary junction. It ascends along the ventral midline of the pons and terminates near the rostral border of the pons by dividing into the 2 posterior cerebral arteries. Branches include the anterior inferior cerebellar arteries (AICA) and the paramedian arteries.

Branches of the basilar artery include:the labyrinthine artery, which follows the course of the eighth cranial nerve and supplies the inner ear; the anterior inferior cerebellar artery, which supplies part of the pons and the anterior and inferior regions of the cerebellum; the superior cerebellar artery, which supplies part of the rostral pons and the superior region of the cerebellum; and pontine branches, which supply much of the pons via paramedian and circumferential vessels.

At the rostral end of the midbrain, the basilar artery divides into a pair of posterior cerebral arteries. Paramedian and circumferential branches of the posterior cerebral artery supply the midbrain.

Note

Brain stem:

Vertebral Artery:

1. ASA
2. PICA

Basilar:

1. AICA
2. Paramedian
3. Superior cerebellar
4. Posterior cerebral

BRAIN-STEM LESIONS

There are 2 keys to localizing brain-stem lesions. First, it is uncommon to injure parts of the brain stem without involving one or more cranial nerves. The cranial nerve signs will localize the lesion to the midbrain (CN III or IV), upper pons (CN V), lower pons (CN VI, VII, or VIII), or upper medulla (CN IX, X, or XII). Second, if the lesion is in the brain stem, the cranial nerve deficits will be seen with a lesion to one or more of the descending or ascending long tracts (corticospinal, medial lemniscus, spinothalamic, descending hypothalamic fibers). Lesions in the brain stem to any of the long tracts except for the descending hypothalamic fibers will result in a contralateral deficit. A unilateral lesion to the descending hypothalamic fibers that results in Horner syndrome is always seen ipsilateral to the side of the lesion.

Medial Medullary Syndrome

Medial medullary syndrome is most frequently the result of occlusion of the vertebral artery or the anterior spinal artery (Figure III-5-17). Medial medullary syndrome presents with a lesion of the hypoglossal nerve as the cranial nerve sign and lesions to both the medial lemniscus and the corticospinal tract. Corticospinal tract lesions produce contralateral spastic hemiparesis of both limbs.

Medial lemniscus lesions produce a contralateral deficit of proprioception and touch, pressure, and vibratory sensations in the limbs and body.

Lesions of the hypoglossal nerve in the medulla produce an ipsilateral paralysis of half the tongue with atrophy. Upon protrusion, the tongue deviates toward the side of the lesion.

Medulla

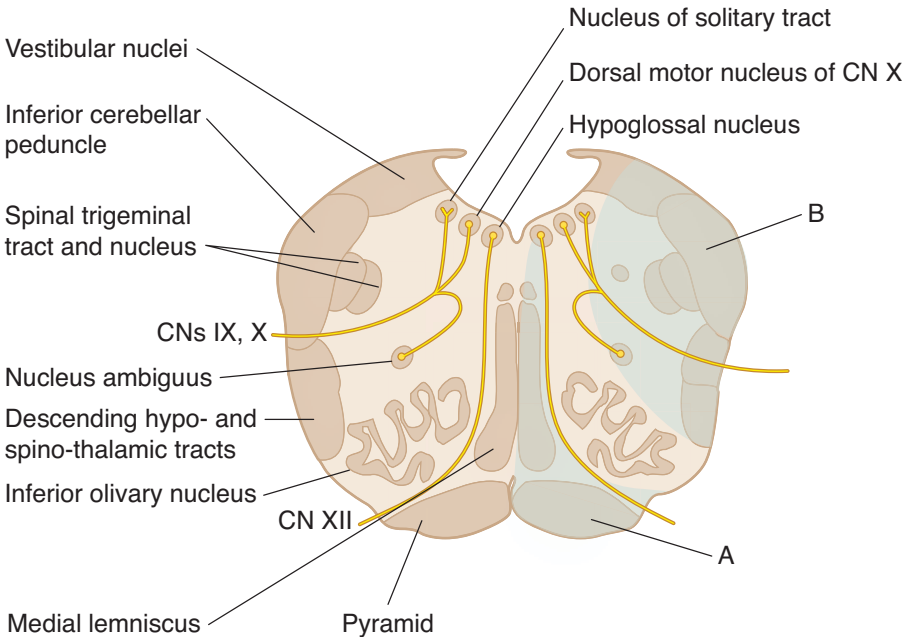

Figure III-5-17. Medulla Lesions

Medial Medullary Syndrome A

Anterior Spinal Artery

- **Pyramid:** contralateral spastic paresis
- **Medial lemniscus:** contralateral loss of tactile, vibration, conscious proprioception
- **XII nucleus/fibers:** ipsilateral flaccid paralysis of tongue with tongue deviation on protrusion to lesion side.

Lateral Medullary Syndrome B

PICA, Wallenberg Syndrome

- **Inferior cerebellar peduncle:** ipsilateral limb ataxia
- **Vestibular nuclei:** vertigo, nausea/vomiting, nystagmus (away from lesion)
- **Nucleus ambiguus (CN IX, X):** ipsilateral paralysis of larynx, pharynx, palate → dysarthria, dysphagia, loss of gag reflex
- **Spinal V:** ipsilateral pain/temperature loss (face)
- **Spinothalamic tract:** Contralateral pain/temperature loss (body)
- **Descending hypothalamics:** ipsilateral Horner syndrome

Lateral Medullary (Wallenberg) Syndrome

Lateral medullary syndrome results from occlusion of the PICA. The cranial nerves or nuclei involved in the lesion are the vestibular or the cochlear parts of CN VIII, the glossopharyngeal and the vagus nerves, and the spinal nucleus or tract of V. The long tracts involved are the spinothalamic tract and the descending hypothalamic fibers.

Spinothalamic tract lesions produce a pain and temperature sensation deficit in the contralateral limbs and body.

Lesions of descending hypothalamic fibers produce an ipsilateral Horner syndrome (i.e., miosis, ptosis, and anhidrosis).

Lesions of the vestibular nuclei and pathways may produce nystagmus, vertigo, nausea, and vomiting. If there is a vestibular nystagmus, the fast component will be away from the side of the lesion.

Lesions of the vagus nerves exiting the medulla may produce dysphagia (difficulty in swallowing) or hoarseness. The palate will droop on the affected side, and the uvula will deviate away from the side of the lesion.

Lesions of the glossopharyngeal nerve result in a diminished or absent gag reflex.

Lesions of the spinal tract and nucleus of the trigeminal nerve produce a loss of just pain and temperature sensations on the ipsilateral side of half the face. Touch sensations from the face and the corneal blink reflex will be intact. In lateral medullary syndrome, the pain and temperature losses are alternating; these sensations are lost from the face and scalp ipsilateral to the lesion but are lost from the contralateral limbs and trunk.

Taste sensations may be altered if the solitary nucleus is involved.

Medial Pontine Syndrome

Medial pontine syndrome results from occlusion of paramedian branches of the basilar artery. At a minimum, this lesion affects the exiting fibers of the abducens nerve and the corticospinal tract. The medial lemniscus may be affected if the lesion is deeper into the pons, and the facial nerve may be affected if the lesion extends laterally.

The long tract signs will be the same as in medial medullary syndrome, involving the corticospinal and medial lemniscus, but the abducens nerve and the facial nerve lesions localize the lesion to the caudal pons.

Corticospinal tract lesions produce contralateral spastic hemiparesis of both limbs.

Medial lemniscus lesions produce a contralateral deficit of proprioception and touch, pressure, and vibratory sensations in the limbs and body.

Lesions of the abducens nerve exiting the caudal pons produce an internal strabismus of the ipsilateral eye (from paralysis of the lateral rectus). This results in diplopia on attempted lateral gaze to the affected side.

Lesions of the facial nerve exiting the caudal pons produce complete weakness of the muscles of facial expression on the side of the lesion.

Lesions of the facial nerve may also include an alteration of taste from the anterior two-thirds of the tongue, loss of lacrimation (eye dry and red), and loss of the motor limb of the corneal blink reflex.

If a lesion extends dorsally to include the abducens nucleus (which includes the horizontal gaze center in the PPRF), there may be a lateral gaze paralysis in which both eyes are forcefully directed to the side contralateral to the lesion.

Lateral Pontine Syndrome

Lesions of the dorsolateral pons usually result from occlusion of the anterior inferior cerebellar artery (caudal pons) or superior cerebellar artery (rostral pons). The long tracts involved will be the same as in lateral medullary syndrome, the spinothalamic tract and the descending hypothalamic fibers. The cranial nerves involved will be the facial and vestibulocochlear in the caudal pons, the trigeminal nerve in the rostral pons, and the spinal nucleus and tract of V in both lesions.

Spinothalamic tract lesions produce a pain and temperature sensation deficit in the contralateral limbs and body.

Lesions of descending hypothalamic fibers produce an ipsilateral Horner syndrome (i.e., miosis, ptosis, and anhidrosis).

Lesions of the vestibular nuclei and pathways (caudal pons) produce nystagmus, vertigo, nausea, and vomiting. Again, the fast phase of the nystagmus will be away from the side of the lesion. Lesions of the cochlear nucleus or auditory nerve produce an ipsilateral sensorineural hearing loss.

Lesions of the spinal tract and nucleus of the trigeminal nerve result only in a loss of pain and temperature sensations on the ipsilateral side of half the face.

Lesions of the facial nerve and associated structures produce ipsilateral facial paralysis, loss of taste from the anterior two-thirds of the tongue, loss of lacrimation and salivation, and loss of the corneal reflex.

Lesions of the trigeminal nerve (rostral pons) result in complete anesthesia of the face on the side of the lesion, weakness of muscles of mastication, and deviation of the jaw toward the lesioned side.

Pons

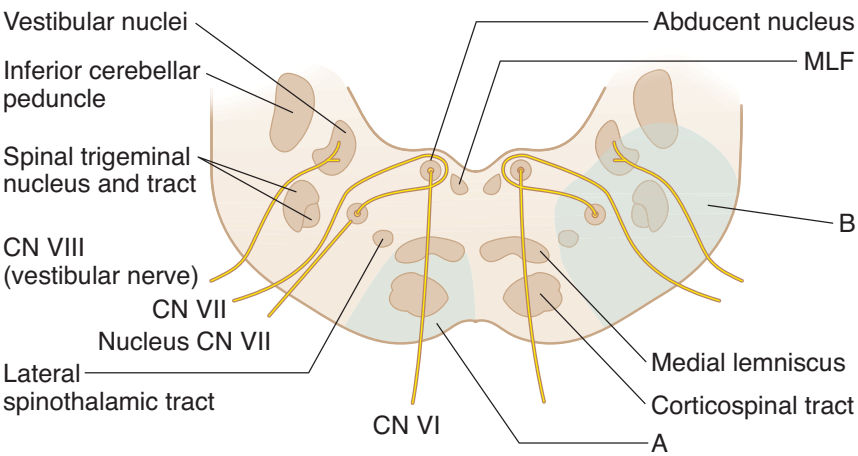

Figure III-5-18. Pons

Medial Pontine Syndrome (A)

Paramedian Branches of Basilar Artery

- **Corticospinal tract:** contralateral spastic hemiparesis
- **Medial lemniscus:** contralateral loss of tactile/position/vibration sensation
- **Fibers of VI:** medial strabismus

Lateral Pontine Syndrome (B)

AICA

- **Middle cerebellar peduncle:** ipsilateral ataxia
- **Vestibular nuclei:** vertigo, nausea and vomiting, nystagmus
- **Facial nucleus and fibers:** ipsilateral facial paralysis; ipsilateral loss of taste (anterior two-thirds of tongue), lacrimation, salivation, and corneal reflex; hyperacusis
- **Spinal trigeminal nucleus/tract:** ipsilateral pain/temperature loss (face)
- **Spinothalamic tract:** contralateral pain/temperature loss (body)
- **Cochlear nucleus/VIII fibers:** ipsilateral hearing loss
- **Descending hypothalamics:** ipsilateral Horner syndrome

Pontocerebellar Angle Syndrome

Pontocerebellar angle syndrome is usually caused by an acoustic neuroma (schwannoma) of CN VIII. This is a slow-growing tumor, which originates from Schwann cells in the vestibular nerve (or less commonly the auditory nerve). As the tumor grows, it exerts pressure on the lateral part of the caudal pons where CN VII emerges and may expand anteriorly to compress the fifth nerve. The cranial nerve deficits seen together localize the lesion to the brain stem, but the absence of long tract signs indicates that the lesion must be outside of the brain stem.

Medial Midbrain (Weber) Syndrome

Medial midbrain (Weber) syndrome results from occlusion of branches of the posterior cerebral artery. Exiting fibers of CN III are affected, along with corticobulbar and corticospinal fibers in the medial aspect of the cerebral peduncle. Third-nerve lesions result in a ptosis, mydriasis (dilated pupil), and an external strabismus. As with any brain-stem lesion affecting CN III, accommodation and convergence will also be affected. Corticospinal tract lesions produce contralateral spastic hemiparesis of both limbs. The involvement of the cortico-bulbar fibers results in a contralateral lower face weakness seen as a drooping of the corner of the mouth. The patient will be able to shut the eye (blink reflex is intact) and wrinkle the forehead.

Midbrain

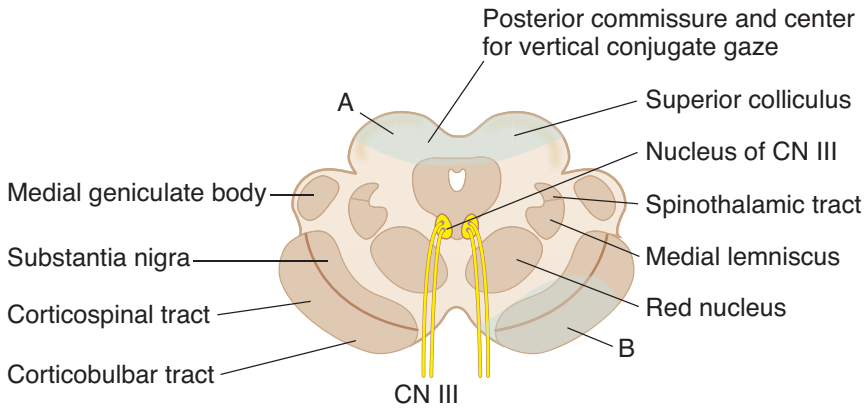

Figure III-5-19. Midbrain

Dorsal Midbrain (Parinaud) Syndrome (A)

Tumor in Pineal Region

- **Superior colliculus/pretectal area:** paralysis of upward gaze, various pupillary abnormalities
- **Cerebral aqueduct:** noncommunicating hydrocephalus

Medial Midbrain (Weber) Syndrome (B)

Branches of PCA

- **Fibers of III:** ipsilateral oculomotor palsy (lateral strabismus, dilated pupil, ptosis)
- **Corticospinal tract:** contralateral spastic hemiparesis
- **Corticobulbar tract:** contralateral hemiparesis of lower face

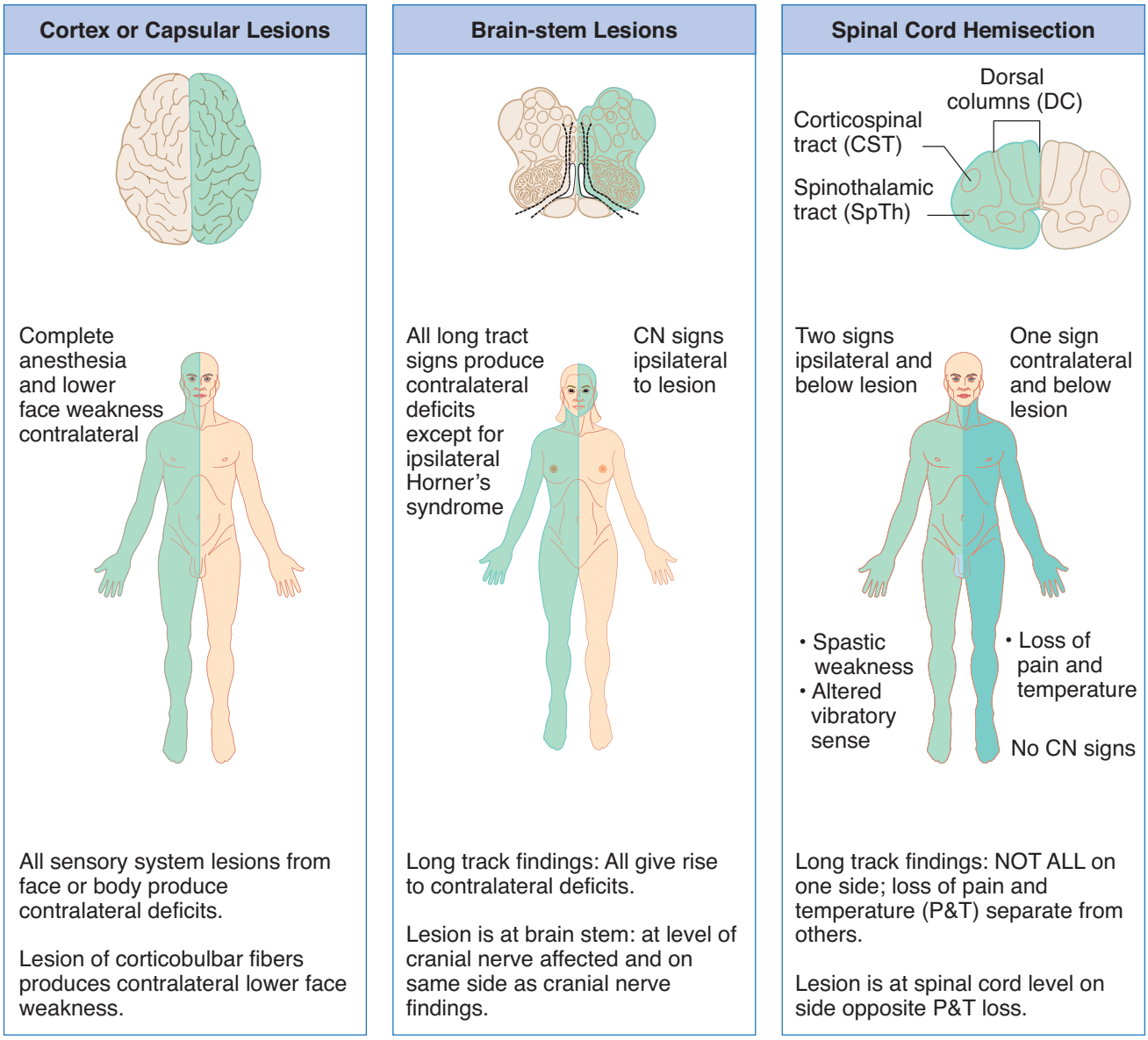

Figure III-5-20. Strategy for the Study of Lesions

Clinical Correlate

Neurons in both the raphe and locus caeruleus degenerate in Alzheimer disease.

Parinaud Syndrome

Parinaud syndrome usually occurs as a result of a pineal tumor compressing the superior colliculi. The most common sign is paralysis of upward or vertical gaze, combined with bilateral pupillary abnormalities (e.g., slightly dilated pupils, which may show an impaired light or accommodation reaction) and signs of elevated intracranial pressure. Compression of the cerebral aqueduct can result in noncommunicating hydrocephalus.

RETICULAR FORMATION

The reticular formation is located in the brain stem and functions to coordinate and integrate the actions of different parts of the CNS. It plays an important role in the regulation of muscle and reflex activity and control of respiration, cardiovascular responses, behavioral arousal, and sleep.

Reticular Nuclei

The **raphe nuclei** are a narrow column of cells in the midline of the brain stem, extending from the medulla to the midbrain. Cells in some of the raphe nuclei (e.g., the dorsal raphe nucleus) synthesize serotonin (5-hydroxytryptamine [5-HT]) from l-tryptophan and project to vast areas of the CNS. They play a role in mood, aggression, and the induction of non–rapid eye movement (non-REM) sleep.

Cells in the **locus caeruleus** synthesize norepinephrine and send projections to most brain areas involved in the control of cortical activation (arousal). Decreased levels of norepinephrine are evident in REM (paradoxic) sleep.

The **periaqueductal (central) gray** is a collection of nuclei surrounding the cerebral aqueduct in the midbrain. Opioid receptors are present on many periaqueductal gray cells, the projections from which descend to modulate pain at the level of the dorsal horn of the spinal cord.

The Cerebellum 6

Learning Objectives

- ❑ Use knowledge of general features
- ❑ Use knowledge of cerebellar cytoarchitecture
- ❑ Solve problems concerning circuitry

GENERAL FEATURES

The cerebellum, located dorsal to the pons and the medulla, is derived from the metencephalon. The fourth ventricle is found between the cerebellum and the dorsal aspect of the pons. The cerebellum functions in the planning and fine-tuning of skeletal muscle contractions; it performs these tasks by comparing an intended with an actual performance.

The cerebellum consists of a midline vermis and 2 lateral cerebellar hemispheres. The cerebellar cortex consists of multiple parallel folds (or folia) and contains several maps of the skeletal muscles in the body. The topographic arrangement of these maps indicates that the vermis controls the axial and proximal musculature of the limbs, the intermediate part of the hemisphere controls distal musculature, and the lateral part of the hemisphere is involved in motor planning.

The flocculonodular lobe is involved in control of balance and eye movements.

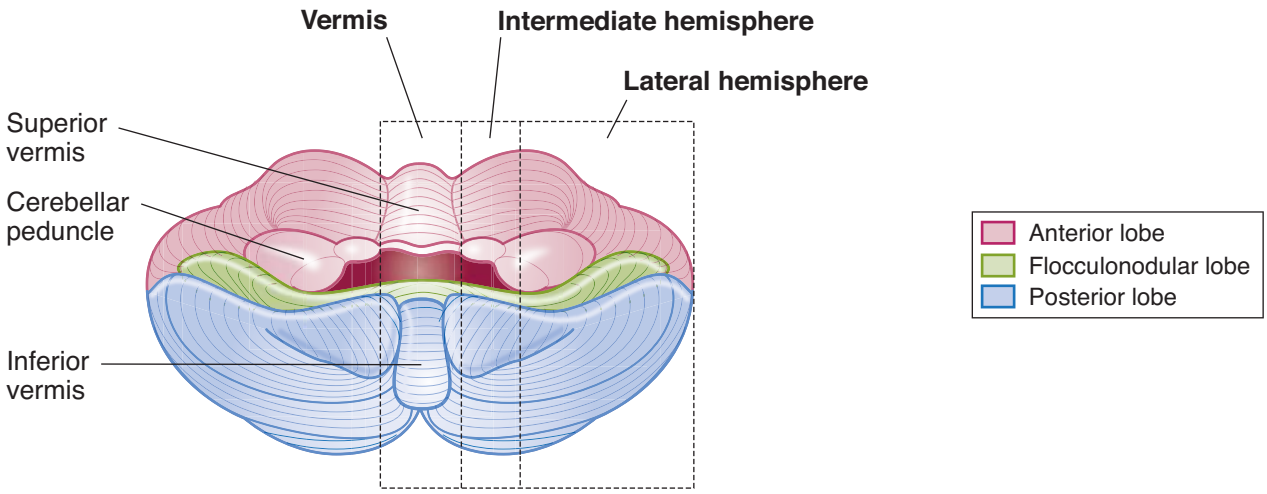

Figure III-6-1. Cerebellum

Table III-6-1. Cerebellum

Region	Function	Principle Input
Vermis and intermediate zones	Ongoing motor execution	Spinal cord
Hemisphere (lateral)	Planning/coordination	Cerebral cortex and inferior olivary nucleus
Flocculonodular lobe	Balance and eye movements	Vestibular nuclei (VIII)

Major input to the cerebellum travels in the inferior cerebellar peduncle (ICP) (restiform body) and middle cerebellar peduncle (MCP). Major outflow from the cerebellum travels in the superior cerebellar peduncle (SCP).

CEREBELLAR CYTOARCHITECTURE

All afferent and efferent projections of the cerebellum traverse the ICP, MCP, or SCP. Most afferent input enters the cerebellum in the ICP and MCP; most efferent outflow leaves in the SCP.

Table III-6-2. Major Afferents to the Cerebellum

Name	Tract	Enter Cerebellum Via	Target and Function
Mossy fibers	Vestibulocerebellar Spinocerebellar (Cortico) pontocerebellar	ICP ICP and SCP MCP (decussate)	Excitatory terminals on granule cells (glutamate)
Climbing fibers	Olivocerebellar	ICP (decussate)	Excitatory terminals on Purkinje cells

Abbreviations: ICP, inferior cerebellar peduncle; MCP, middle cerebellar peduncle; SCP, superior cerebellar peduncle

Internally, the cerebellum consists of an outer cortex and an internal white matter (medullary substance).

The 3 cell layers of the cortex are the molecular layer, the Purkinje layer, and the granule cell layer.

The **molecular layer** is the outer layer and is made up of basket and stellate cells as well as parallel fibers, which are the axons of the granule cells. The extensive dendritic tree of the Purkinje cell extends into the molecular layer.

The **Purkinje layer** is the middle and most important layer of the cerebellar cortex. All of the inputs to the cerebellum are directed toward influencing the firing of Purkinje cells, and only axons of Purkinje cells leave the cerebellar cortex. A

single axon exits from each Purkinje cell and projects to one of the deep cerebellar nuclei or to vestibular nuclei of the brain stem.

The **granule cell layer** is the innermost layer of cerebellar cortex and contains Golgi cells, granule cells, and glomeruli. Each glomerulus is surrounded by a glial capsule and contains a granule cell and axons of Golgi cells, which synapse with granule cells. The granule cell is the only excitatory neuron within the cerebellar cortex. All other neurons in the cerebellar cortex, including Purkinje, Golgi, basket, and stellate cells, are inhibitory.

Table III-6-3. Cerebellum: Cell Types

Name	Target (Axon Termination)	Transmitter	Function
Purkinje cell	Deep cerebellar nuclei	GABA	Inhibitory*
Granule cell	Purkinje cell	Glutamate	Excitatory
Stellate cell	Purkinje cell	GABA	Inhibitory
Basket cell	Purkinje cell	GABA	Inhibitory
Golgi cell	Granule cell	GABA	Inhibitory
*Purkinje cells are the only outflow from the cerebellar cortex.			

The internal white matter contains the deep cerebellar nuclei.

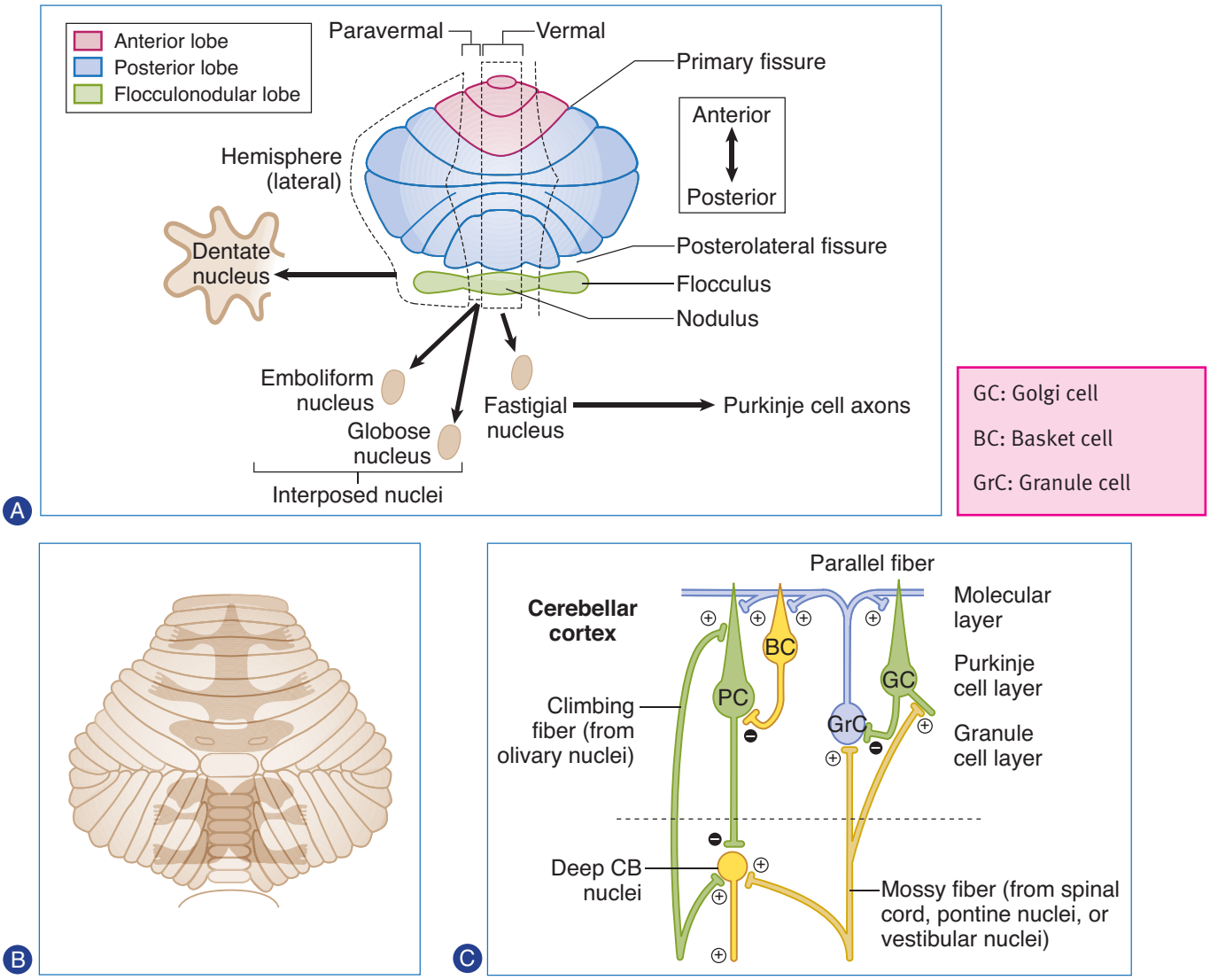

Figure III-6-2. Cerebellar Organization

(A) Parts of the cerebellar cortex and the deep cerebellar nuclei linked together by Purkinje cells
(B) Topographic arrangement of skeletal muscles controlled by parts of the cerebellum
(C) Cytology of the cerebellar cortex

From medial to lateral, the deep cerebellar nuclei in the internal white matter are the fastigial nucleus, interposed nuclei, and dentate nucleus.

Two kinds of excitatory input enter the cerebellum in the form of climbing fibers and mossy fibers. Both types influence the firing of deep cerebellar nuclei by axon collaterals.

Climbing fibers originate exclusively from the inferior olivary complex of nuclei on the contralateral side of the medulla. Climbing fibers provide a direct powerful monosynaptic excitatory input to Purkinje cells.

Mossy fibers represent the axons from all other sources of cerebellar input. Mossy fibers provide an indirect, more diffuse excitatory input to Purkinje cells.

All mossy fibers exert an excitatory effect on **granule cells**. Each granule cell sends its axon into the molecular layer, where it gives off collaterals at a 90-degree angle that run parallel to the cortical surface (i.e., parallel fibers). These granule cell axons stimulate the apical dendrites of the Purkinje cells. Golgi cells receive excitatory input from mossy fibers and from the parallel fibers of the granule cells. The Golgi cell in turn inhibits the granule cell, which activated it in the first place.

The **basket** and **stellate cells**, which also receive excitatory input from parallel fibers of granule cells, inhibit Purkinje cells.

CIRCUITRY

The basic cerebellar circuits begin with Purkinje cells that receive excitatory input directly from climbing fibers and from parallel fibers of granule cells.

Purkinje cell axons project to and inhibit the deep cerebellar nuclei or the vestibular nuclei in an orderly fashion.

- Purkinje cells in the flocculonodular lobe project to the lateral vestibular nucleus.
- Purkinje cells in the vermis project to the fastigial nuclei.
- Purkinje cells in the intermediate hemisphere primarily project to the interposed (globose and emboliform) nuclei.
- Purkinje cells in the lateral cerebellar hemisphere project to the dentate nucleus.

Dysfunction

- **Hemisphere lesions** → ipsilateral symptoms: **intention** tremor, dysmetria, dysdiadochokinesia, scanning dysarthria, nystagmus, hypotonia
- **Vermal lesions** → truncal ataxia

Major Pathway

Purkinje cells → deep cerebellar nucleus; dentate nucleus → contralateral VL → first-degree motor cortex → pontine nuclei → contralateral cerebellar cortex

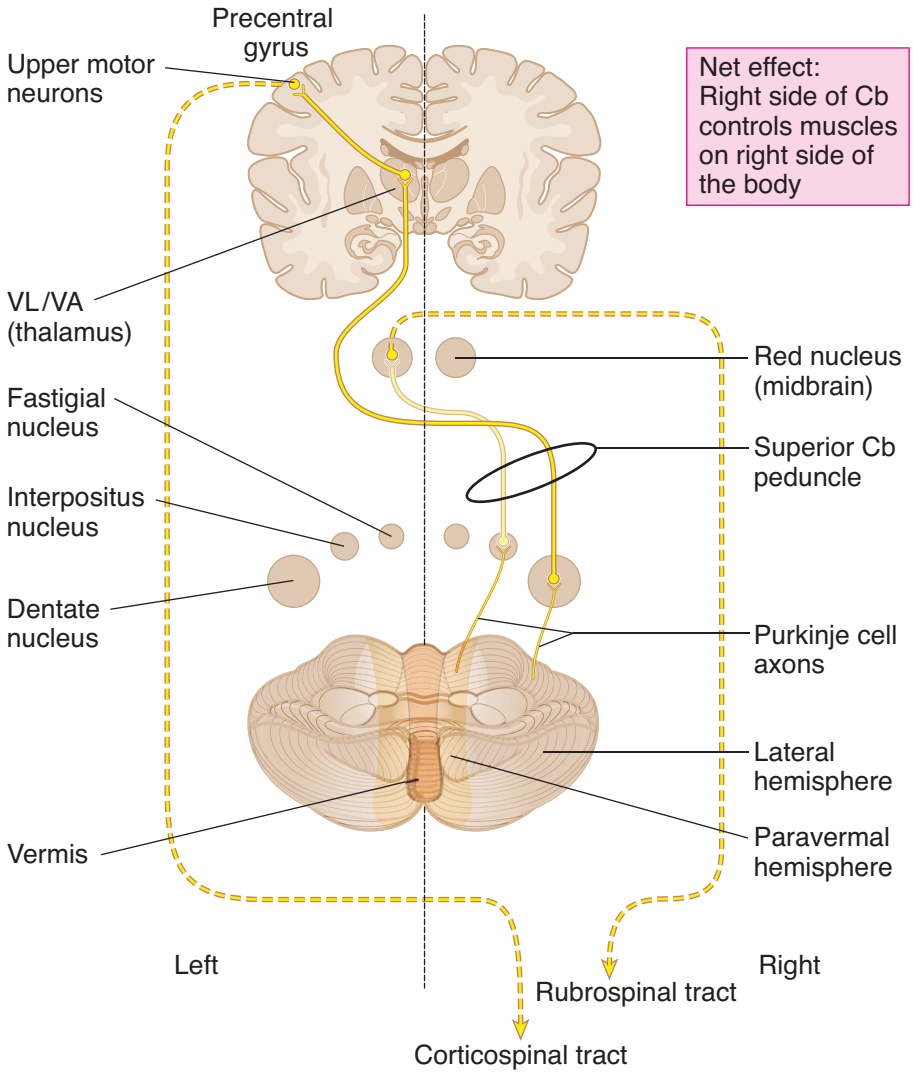

Figure III-6-3. Cerebellar Efferents

Table III-6-4. Major Efferents From the Cerebellum

Cerebellar Areas	Deep Cerebellar Nucleus	Efferents to:	Function
Vestibulocerebellum (flocculonodular lobe)	Fastigial nucleus	Vestibular nucleus	Elicit positional changes of eyes and trunk in response to movement of the head
Spinocerebellum (intermediate hemisphere)	Interpositus nucleus	Red nucleus Reticular formation	Influence LMNs via the reticulospinal and rubrospinal tracts to adjust posture and effect movement
Pontocerebellum (lateral hemispheres)	Dentate nucleus	Thalamus (VA, VL) then cortex	Influence on LMNs via the corticospinal tract, which effect voluntary movements, especially sequence and precision

Efferents from the deep cerebellar nuclei leave mainly through the SCP and influence all upper motoneurons. In particular, axons from the dentate and interposed nuclei leave through the SCP, cross the midline, and terminate in the ventrolateral (VL) nucleus of the thalamus.

The VL nucleus of the thalamus projects to primary motor cortex and influences the firing of corticospinal and corticobulbar neurons.

Axons from other deep cerebellar nuclei influence upper motoneurons in the red nucleus and in the reticular formation and vestibular nuclei.

Cerebellar Lesions

The hallmark of cerebellar dysfunction is a tremor with intended movement without paralysis or paresis. Symptoms associated with cerebellar lesions are expressed ipsilaterally because the major outflow of the cerebellum projects to the contralateral motor cortex, and then the corticospinal fibers cross on their way to the spinal cord. Thus, unilateral lesions of the cerebellum will result in a patient falling toward the side of the lesion.

Lesions that include the hemisphere

Lesions that include the hemisphere produce a number of dysfunctions, mostly involving distal musculature.

An intention tremor is seen when voluntary movements are performed. For example, if a patient with a cerebellar lesion is asked to pick up a penny, a slight tremor of the fingers is evident and increases as the penny is approached. The tremor is barely noticeable or is absent at rest.

Dysmetria (past pointing) is the inability to stop a movement at the proper place. The patient has difficulty performing the finger-to-nose test.

Dysdiadochokinesia (adiadochokinesia) is the reduced ability to perform alternating movements, such as pronation and supination of the forearm, at a moderately quick pace.

Scanning dysarthria is caused by asynergy of the muscles responsible for speech. In scanning dysarthria, patients divide words into syllables, thereby disrupting the melody of speech.

Gaze dysfunction occurs when the eyes try to fix on a point: They may pass it or stop too soon and then oscillate a few times before they settle on the target. A nystagmus may be present, particularly with acute cerebellar damage. The nystagmus is often coarse, with the fast component usually directed toward the involved cerebellar hemisphere.

Hypotonia usually occurs with an acute cerebellar insult that includes the deep cerebellar nuclei. The muscles feel flabby on palpation, and deep tendon reflexes are usually diminished.

Lesions to the vermal region

Vermal lesions result in difficulty maintaining posture, gait, or balance (an ataxic gait). Patients with vermal damage may be differentiated from those with a lesion of the dorsal columns by the Romberg sign. In cerebellar lesions, patients will sway or lose their balance with their eyes open; in dorsal column lesions, patients sway with their eyes closed.

Clinical Correlate

Anterior vermis lesions are usually the result of degeneration from alcohol abuse and are present with gait ataxia. Posterior vermis lesions result from medulloblastomas or ependymomas and present with truncal ataxia.

Basal Ganglia 7

Learning Objectives

- ❑ Solve problems concerning general features of the basal ganglia

GENERAL FEATURES

The basal ganglia initiate and provide gross control over skeletal muscle movements. The major components of the basal ganglia include:

- Striatum, which consists of the caudate nucleus and the putamen (telencephalon)
- External and internal segments of the globus pallidus (telencephalon)
- Substantia nigra (in midbrain)
- Subthalamic nucleus (in diencephalon)

Together with the cerebral cortex and the ventrolateral (VL) nucleus of the thalamus, these structures are interconnected to form 2 parallel but antagonistic circuits known as the direct and indirect basal ganglia pathways. Both pathways are driven by extensive inputs from large areas of cerebral cortex, and both project back to the motor cortex after a relay in the VL nucleus of the thalamus. Both pathways use a process known as "disinhibition" to mediate their effects, whereby one population of inhibitory neurons inhibits a second population of inhibitory neurons.

Direct Basal Ganglia Pathway

In the direct pathway, excitatory input from the cerebral cortex projects to striatal neurons in the caudate nucleus and putamen. Through disinhibition, activated inhibitory neurons in the striatum, which use γ-aminobutyric acid (GABA) as their neurotransmitter, project to and inhibit additional GABA neurons in the internal segment of the globus pallidus.

The GABA axons of the internal segment of the globus pallidus project to the thalamus (VL). Because their input to the thalamus is disinhibited, the thalamic input excites the motor cortex. The net effect of the disinhibition in the direct pathway results in an **increased** level of cortical excitation and the promotion of movement.

Indirect Basal Ganglia Pathway

In the indirect pathway, excitatory input from the cerebral cortex also projects to striatal neurons in the caudate nucleus and putamen. These inhibitory neurons in the striatum, which also use GABA as their neurotransmitter, project to and inhibit additional GABA neurons in the external segment of the globus pallidus.

The GABA axons of the external segment of the globus pallidus project to the subthalamic nucleus. Through disinhibition, the subthalamic nucleus excites inhibitory GABA neurons in the internal segment of the globus pallidus, which inhibits the thalamus. This decreases the level of cortical excitation, inhibiting movement. The net effect of the disinhibition in the indirect pathway results in a **decreased** level of cortical excitation, and a suppression of unwanted movement.

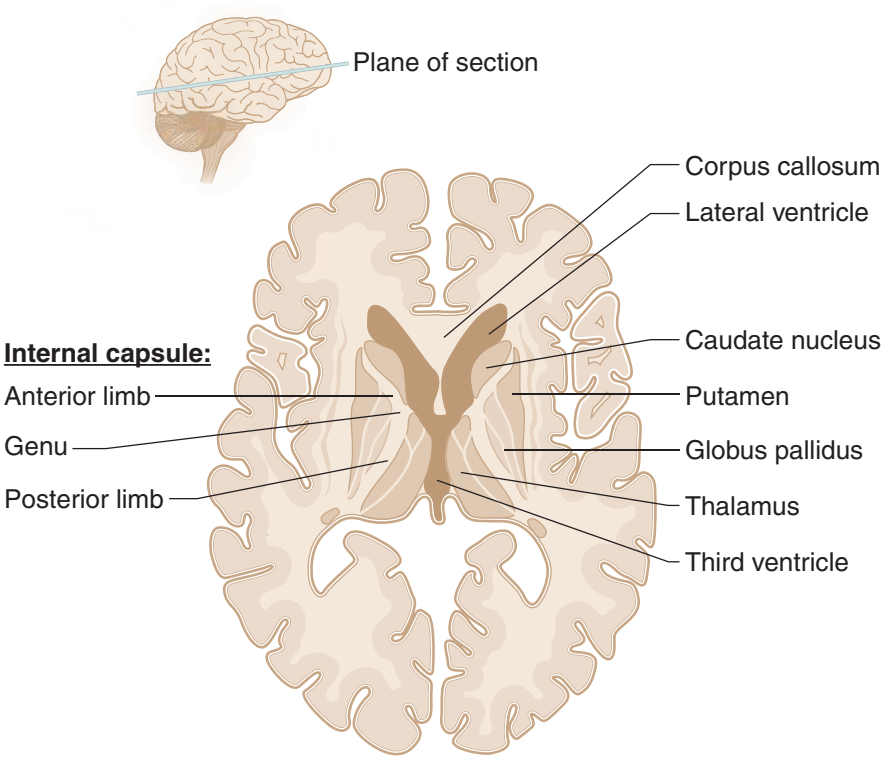

Figure III-7-1. Horizontal or Axial Section through Basal Ganglia

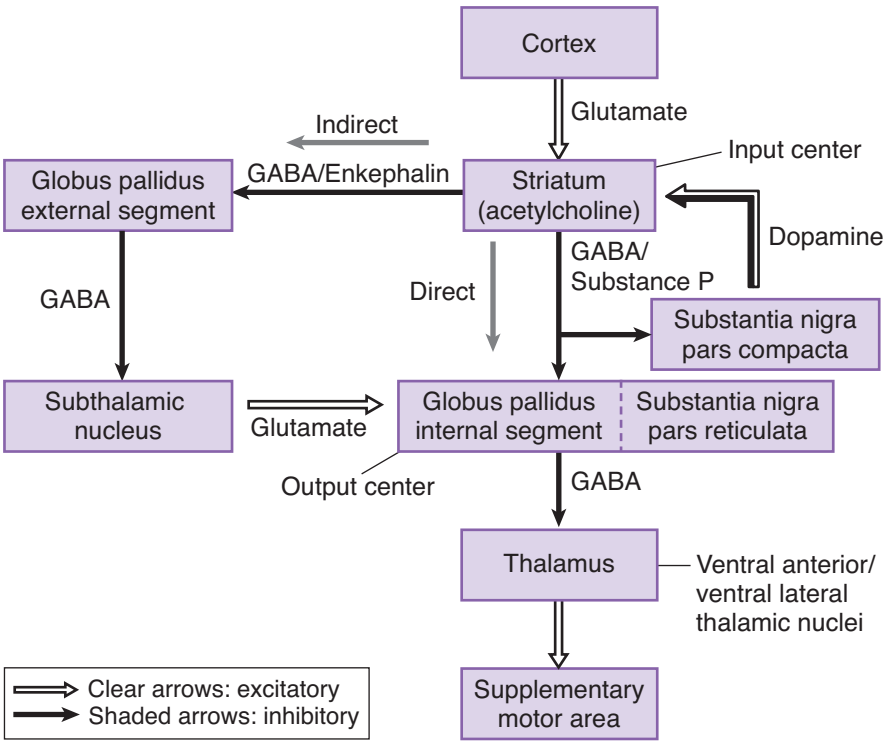

Figure III-7-2. Basal Ganglia Pathways

Dopamine and cholinergic effects

In addition to the GABA neurons, 2 other sources of chemically significant neurons enhance the effects of the direct or indirect pathways.

Dopaminergic neurons in the substantia nigra in the midbrain project to the striatum. The effect of dopamine excites or drives the direct pathway, increasing cortical excitation. Dopamine excites the direct pathway through D_1 receptors and inhibits the indirect pathway through D_2 receptors.

Cholinergic neurons found within the striatum have the opposite effect. Acetylcholine (Ach) drives the indirect pathway, decreasing cortical excitation.

Note

Both basal ganglia pathways utilize 2 GABA neurons in series, and a "disinhibition."

Note

Dopamine drives the direct pathway; acetylcholine (ACh) drives the indirect pathway.

Note

All basal ganglia connections are with ipsilateral cortex.

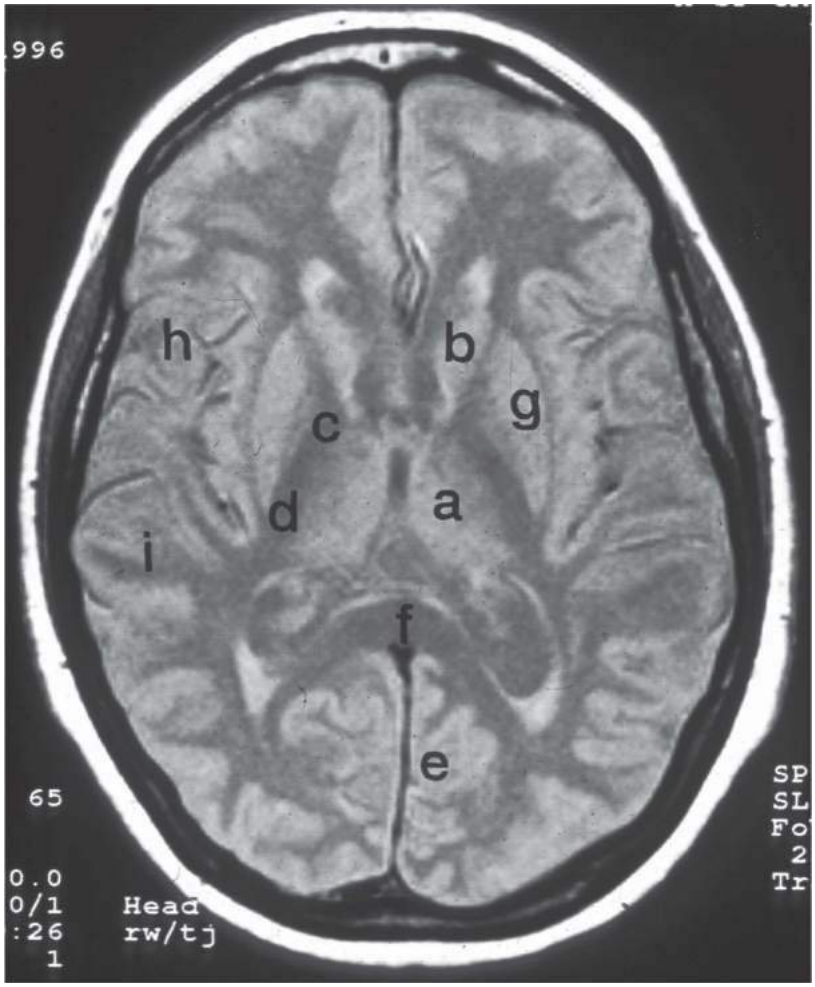

Figure III-7-3. MRI of Horizontal Section through Diencephalon, Basal Ganglia, and Cortex

(a) Thalamus (b) Head of Caudate Nucleus (c) Genu of Internal Capsule Containing Corticobulbar Axons (d) Posterior Limb of Internal Capsule (e) Primary Visual Cortex (f) Splenium of Corpus Callosum (g) Putamen (h) Broca's Motor Speech Area (i) Wernicke's Oral Comprehension Area

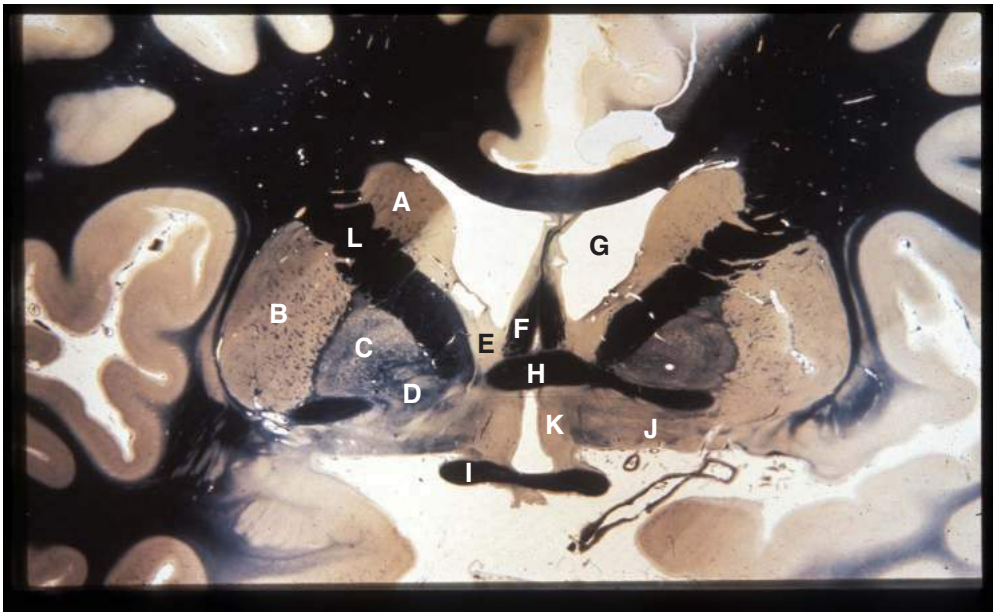

Figure III-7-4. Coronal Section through Basal Ganglia and Other Subcortical Structures

(A) caudate nucleus (B) putamen (C) globus pallidus external segment (D) globus pallidus internal segment (E) septal nuclei (F) fornix (G) lateral ventricle (H) anterior commissure (I) optic chiasm (J) basal nucleus of Meynert (K) preoptic hypothalamus (L) internal capsule, anterior limb

Table III-7-1. Diseases of the Basal Ganglia

Disease	Clinical Manifestations	Notes
Parkinson disease	Bradykinesia, cogwheel rigidity, pill-rolling (resting) tremor, shuffling gate, stooped posture, masked face, depression, dementia	**Loss of pigmented dopaminergic neurons from substantia nigra** **Lewy bodies:** intracytoplasmic eosinophilic inclusions, contain α-synuclein Known causes of parkinsonism: infections, vascular, and toxic insults (e.g., **MPTP**)
Disease	**Clinical Manifestations**	**Notes**
Huntington disease	Chorea (multiple, rapid, random movements), athetosis (slow, writhing movements), personality changes, dementia Onset: 20–40 years	**Degeneration** of GABAergic neurons in **neostriatum**, causing atrophy of head of caudate nucleus (and ventricular dilatation) **Autosomal dominant** **Unstable nucleotide repeat** on gene in chromosome 4, which codes for huntingtin protein Disease shows **anticipation** and **genomic imprinting** **Treatment:** antipsychotic agents, benzodiazepines, anticonvulsants
Wilson disease (hepatolenticular degeneration)	Tremor, asterixis, parkinsonian symptoms, chorea, neuropsychiatric symptoms; fatty change, hepatitis, or cirrhosis of liver, tremor may be "wing beating"	**Autosomal recessive defect in copper transport** Accumulation of copper in liver, brain, and eye (Descemet membrane, producing **Kayser-Fleischer ring**) Lesions in basal ganglia (especially putamen) **Treatment: penicillamine** (a chelator), zinc acetate (blocks absorption)
Hemiballism	Wild, flinging movements of limbs	Hemorrhagic destruction of **contralateral subthalamic nucleus** Hypertensive patients
Tourette syndrome	Motor tics and vocal tics (e.g., snorting, sniffing, uncontrolled and often obscene vocalizations), commonly associated with OCD and ADHD	**Treatment:** Antipsychotic agents

Abbreviations: ADHD, attention deficit hyperactivity disorder; MPTP, 1-methyl-4-phenyl-1,2,3, 6-tetrahydropyridine; OCD, obsessive-compulsive disorder

Clinical Correlate

Lesions or diseases of the basal ganglia generally present with movement disorders, known as dyskinesias, and an involuntary tremor or tremor at rest.

Most basal ganglia disorders seem to preferentially affect either the direct or the indirect pathway, altering the balance between the two.

Lesions of the direct pathway result in an underactive cortex and hypokinetic disturbances in which there is a slowing or absence of spontaneous movements. The best-known disorder is caused by the degeneration of dopaminergic neurons of the substantia nigra in Parkinson disease. Because the cortex is underactive, Parkinson patients have problems initiating movements, combined with a reduction in the velocity and amplitude of the movements. The tremor at rest is the classic pill-rolling tremor seen in the fingers. Skeletal muscles in the upper limbs exhibit a cogwheel rigidity because of increased muscle tone. Patients also present with stooped posture, an expressionless face, and a festinating or accelerating gait during which individuals seem to chase their center of gravity. Strategies for Parkinson are L-dopa, a dopamine precursor that crosses the blood–brain barrier, anticholinergic drugs, which inhibit the effects of acetylcholine on the indirect pathway.

Other common disorders of the basal ganglia (chorea, athetosis, dystonia, tics) result from **lesions to parts of the indirect pathway**, which result in an overactive motor cortex. An overactive cortex produces hyperkinetic disturbances, expressed in numerous spontaneous movements. The involuntary tremors seen in these diseases range from being dancelike in chorea to ballistic with lesions to the subthalamic nucleus.

Chorea produces involuntary movements that are purposeless, quick jerks that may be superimposed on voluntary movements. Huntington chorea exhibits autosomal dominant inheritance (chromosome 4) and is characterized by severe degeneration of GABA neurons in the striatum. Patients suffer from athetoid movements, progressive dementia, and behavioral disorders. Sydenham chorea is a transient complication in some children with rheumatic fever.

Athetosis refers to slow, wormlike, involuntary movements that are most noticeable in the fingers and hands but may involve any muscle group. It is present in Huntington disease and may be observed in many diseases that involve the basal ganglia.

Dystonia refers to a slow, prolonged movement involving predominantly the truncal musculature. Dystonia often occurs with athetosis. Blepharospasm (contraction of the orbicularis oculi causing the eyelids to close), spasmodic torticollis (in which the head is pulled toward the shoulder), and writer's cramp (contraction of arm and hand muscles on attempting to write) are all examples of dystonic movements.

Hemiballismus results from a lesion of the subthalamic nucleus usually seen in hypertensive patients. Hemiballismus refers to a violent projectile movement of a limb and is typically observed in the upper limb contralateral to the involved subthalamic nucleus.

Tourette syndrome involves facial and vocal tics that progress to jerking movements of the limbs. It is frequently associated with explosive, vulgar speech.

Wilson disease results from an abnormality of copper metabolism, causing the accumulation of copper in the liver and basal ganglia. Personality changes, tremor, dystonia, and athetoid movements develop. Untreated patients usually succumb because of hepatic cirrhosis. A thin brown ring around the outer cornea, the Kayser-Fleischer ring, may be present and aid in the diagnosis.

Visual Pathways 8

Learning Objectives

- ❑ Use knowledge of eyeball and optic nerve
- ❑ Solve problems concerning visual reflexes
- ❑ Answer questions about lesions of the visual pathways

EYEBALL AND OPTIC NERVE

Light must pass through the cornea, aqueous humor, pupil, lens, and vitreous humor before reaching the retina. It must then pass through the layers of the retina to reach the photoreceptive layer of rods and cones. The outer segments of rods and cones transduce light energy from photons into membrane potentials. Photopigments in rods and cones absorb photons, and this causes a conformational change in the molecular structure of these pigments. This molecular alteration causes sodium channels to close, a hyperpolarization of the membranes of the rods and cones, and a reduction in the amount of neurotransmitter released. Thus, rods and cones release less neurotransmitter in the light and more neurotransmitter in the dark.

Rods and cones have synaptic contacts on bipolar cells that project to ganglion cells (Figure III-8-2). Axons from the ganglion cells converge at the optic disc to form the optic nerve, which enters the cranial cavity through the optic foramen. At the optic disc, these axons acquire a myelin sheath from the oligodendrocytes of the central nervous system (CNS).

Clinical Correlate

Vitamin A, necessary for retinal transduction, cannot be synthesized by humans. Dietary deficiency of vitamin A causes visual impairment resulting in night blindness.

Clinical Correlate

Decreased drainage into the canal of Schlemm is the most common cause of open-angle glaucoma.

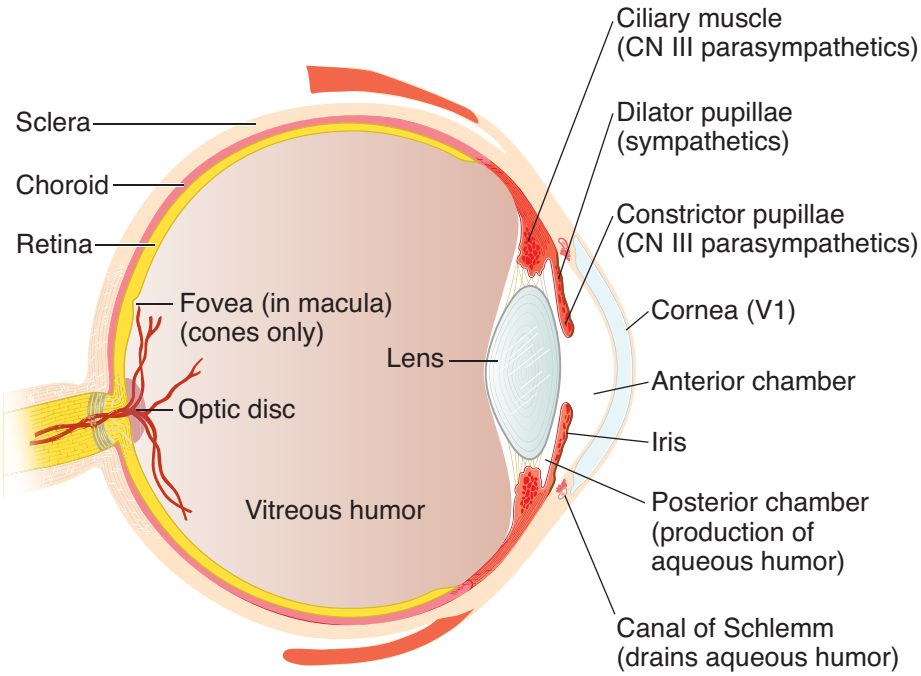

Figure III-8-1. The Eyeball

Open-Angle Glaucoma

A chronic condition (often with increased intraocular pressure [IOP]) due to decreased reabsorption of aqueous humor, leading to progressive (painless) visual loss and, if left untreated, blindness. IOP is a balance between fluid formation and its drainage from the globe.

Narrow-Angle Glaucoma

An acute (painful) or chronic (genetic) condition with increased IOP due to blockade of the canal of Schlemm. Emergency treatment prior to surgery often involves cholinomimetics, carbonic anhydrase inhibitors, and/or mannitol.

VISUAL REFLEXES

Pupillary Light Reflex

When light is directed into an eye, it stimulates retinal photoreceptors and results in impulses carried in the optic nerve to the pretectal area. Cells in the pretectal area send axons to the Edinger-Westphal nuclei on both sides.

The Edinger-Westphal nucleus is the parasympathetic nucleus of the oculomotor nerve and gives rise to preganglionic parasympathetic fibers that pass in the third cranial nerve to the ciliary ganglion. Because cells in the pretectal area supply both Edinger-Westphal nuclei, shining light into one eye results in constriction of both the ipsilateral pupil (direct light reflex) and contralateral pupil (consensual light reflex).

Accommodation-Convergence Reaction

This reaction occurs when an individual attempts to focus on a nearby object after looking at a distant object. The oculomotor nerve carries the efferent fibers from the accommodation–convergence reaction, which consists of 3 components: accommodation, convergence, and pupillary constriction.

Accommodation refers to the reflex that increases the curvature of the lens needed for near vision. Preganglionic parasympathetic fibers arise in the Edinger-Westphal nucleus and pass via the oculomotor nerve to the ciliary ganglion. Postganglionic parasympathetic fibers from the ciliary ganglion supply the ciliary muscle. Contraction of this muscle relaxes the suspensory ligaments and allows the lens to increase its convexity (become more round). This increases the refractive index of the lens, permitting the image of a nearby object to focus on the retina.

Convergence results from contraction of both medial rectus muscles, which pull the eyes to look toward the nose. This allows the image of the near object to focus on the same part of the retina in each eye.

Pupillary constriction (miosis) results from contraction of the constrictor muscle of the iris. A smaller aperture gives the optic apparatus a greater depth of field. With Argyll Robertson pupils, both direct and consensual light reflexes are lost, but the accommodation–convergence reaction remains intact. This type of pupil is often seen in cases of neurosyphilis; however, it is sometimes seen in patients with multiple sclerosis, pineal tumors, or tabes dorsalis. The lesion site is believed to occur near the pretectal nuclei just rostral to the superior colliculi.

Table III-8-1. Pupillary Light Reflex Pathway

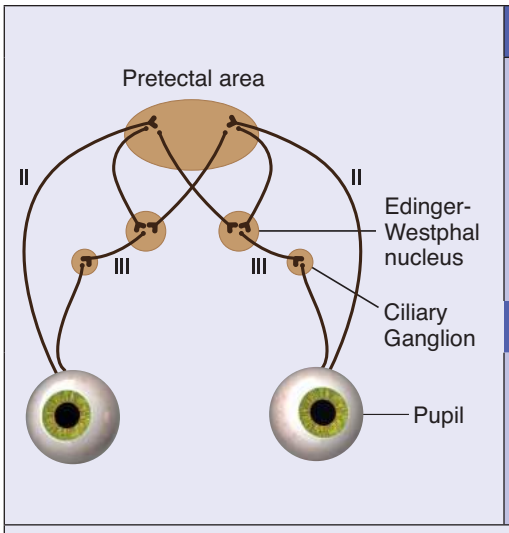

Afferent Limb: CN II
Light stimulates ganglion retinal cells → impulses travel up **CNII** which projects **bilaterally** to the **pretectal nuclei** (midbrain) The pretectal nucleus projects **bilaterally** → **Edinger-Westphal nuclei (CN III)**
Efferent Limb: CN III
Edinger-Westphal nucleus (preganglionic parasympathetic) → **ciliary ganglion** (postganglionic parasympathetic) → **pupillary sphincter muscle** → **miosis**

Because cells in the pretectal area supply the Edinger-Westphal nuclei bilaterally, shining light in one eye → constriction in the ipsilateral pupil (direct light reflex) and the contralateral pupil (consensual light reflex).

Because this reflex does not involve the visual cortex, a person who is cortically blind can still have this reflex.

The eye is predominantly innervated by the parasympathetic nervous system. Therefore, application of muscarinic antagonists or ganglionic blockers has a large effect by blocking the parasympathetic nervous system.

Table III-8-2. Pharmacology of the Eye

Structure	Predominant Receptor	Receptor Stimulation	Receptor Blockade
Pupillary sphincter ms. (iris)	M_3 receptor (PANS)	Contraction → miosis	Relaxation → mydriasis
Radial dilator ms. (iris)	α receptor (SANS)	Contraction → mydriasis	Relaxation → miosis
Ciliary ms.	M_3 receptor (PANS)	Contraction → accommodation for near vision	Relaxation → focus for far vision
Ciliary body epithelium	β receptor (SANS)	Secretion of aqueous humor	Decreased aqueous humor production

Abbreviations: ms., muscle; PANS, parasympathetic nervous system; SANS, sympathetic nervous system

Table III-8-3. Accommodation-Convergence Reaction

When an individual focuses on a nearby object after looking at a distant object, 3 events occur: 1. **Accommodation** 2. **Convergence** 3. **Pupillary constriction (miosis)** In general, stimuli from light → visual cortex → superior colliculus and pretectal nucleus → Edinger-Westphal nucleus (1, 3) and oculomotor nucleus (2).
Accommodation: Parasympathetic fibers contract the ciliary muscle, which relaxes suspensory ligaments, allowing the lens to increase its convexity (become more round). This increases the refractive index of the lens, thereby focusing a nearby object on the retina.
Convergence: Both medial rectus muscles contract, adducting both eyes.
Pupillary constriction: Parasympathetic fibers contract the pupillary sphincter muscle → miosis.

Table III-8-4. Clinical Correlates

	Pupillary Abnormalities
Argyll Robertson pupil (pupillary light-near dissociation)	• No direct or consensual light reflex; accommodation-convergence intact • Seen in **neurosyphilis,** diabetes
Relative afferent (Marcus Gunn) pupil	• Lesion of afferent limb of pupillary light reflex; diagnosis made with swinging flashlight • Shine light in Marcus Gunn pupil → pupils do not constrict fully • Shine light in normal eye → pupils constrict fully • Shine light immediately again in affected eye → apparent dilation of both pupils because stimulus carried through that CN II is weaker; seen in multiple sclerosis
Horner syndrome	• Caused by a lesion of the oculosympathetic pathway; syndrome consists of miosis, ptosis, apparent enophthalmos, and hemianhidrosis
Adie pupil	• Dilated pupil that reacts sluggishly to light, but better to accommodation; often seen in women and often associated with loss of knee jerks. Ciliary ganglion lesion
Transtentorial (uncal) herniation	• Increased intracranial pressure → leads to uncal herniation → CN III compression → fixed and dilated pupil, "down-and-out" eye, ptosis

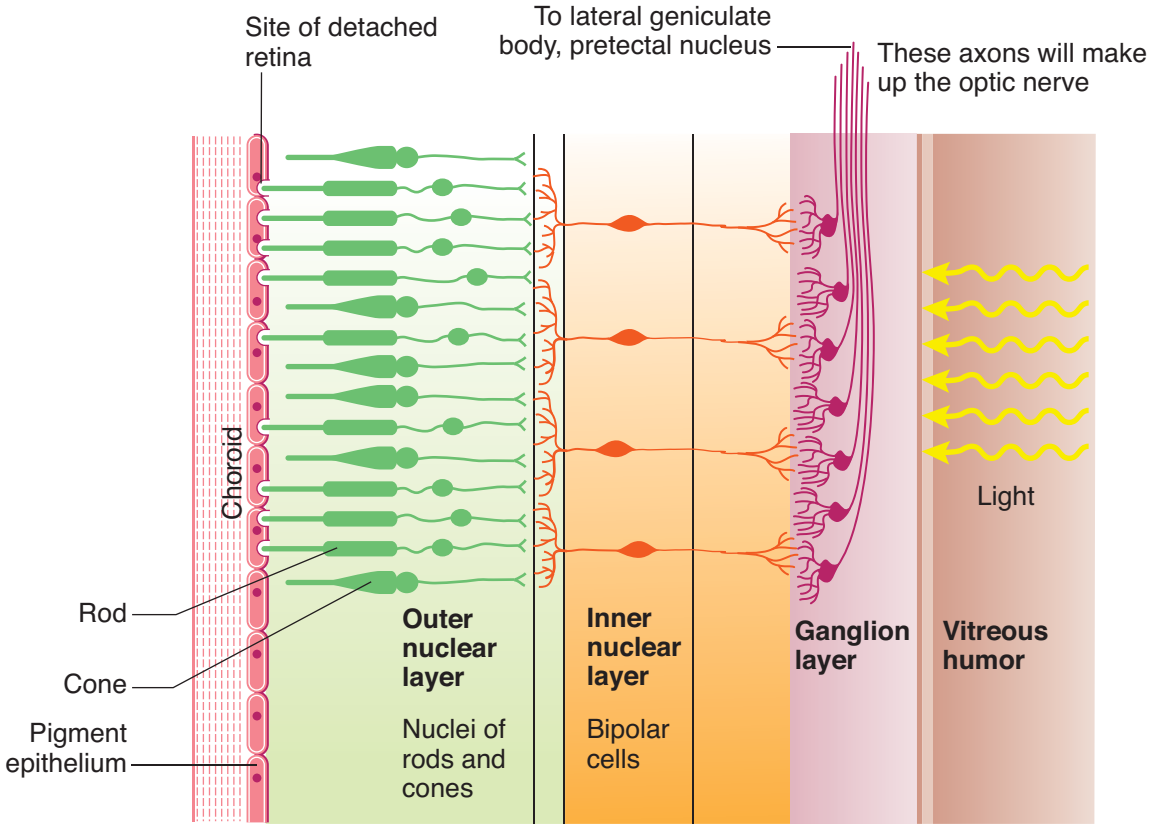

Figure III-8-2. Retina

Note

Photoreceptor Rods: 1 kind

- Achromatic
- Low-light sensitive
- Night vision, motion

Cones: 3 kinds

- Red, green, blue
- Chromatic
- Bright light sensitive
- Object recognition

At the optic chiasm, 60% of the optic nerve fibers from the nasal half of each retina cross and project into the contralateral optic tract (Figure III-8-3). Fibers from the temporal retina do not cross at the chiasm and instead pass into the ipsilateral optic tract. The optic tract contains remixed optic nerve fibers from the temporal part of the ipsilateral retina and fibers from the nasal part of the contralateral retina. Because the eye inverts images like a camera, in reality each nasal retina receives information from a temporal hemifield, and each temporal retina receives information from a nasal hemifield. Most fibers in the optic tract project to the lateral geniculate nucleus. Optic tract fibers also project to the superior colliculi for reflex gaze, to the pretectal area for the light reflex, and to the suprachiasmatic nucleus of the hypothalamus for circadian rhythms.

Visual Field Defects

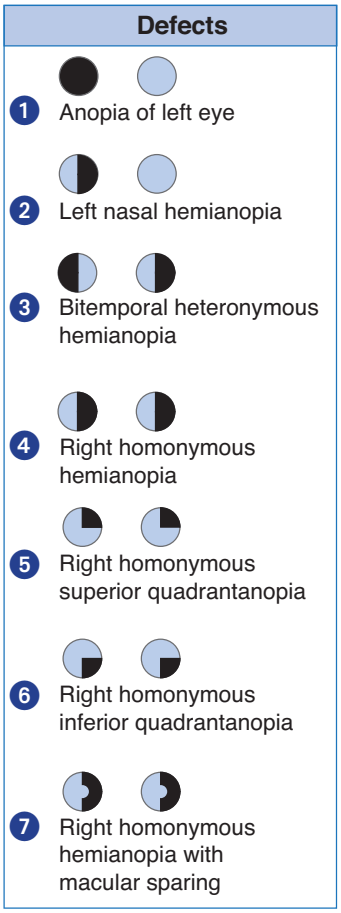

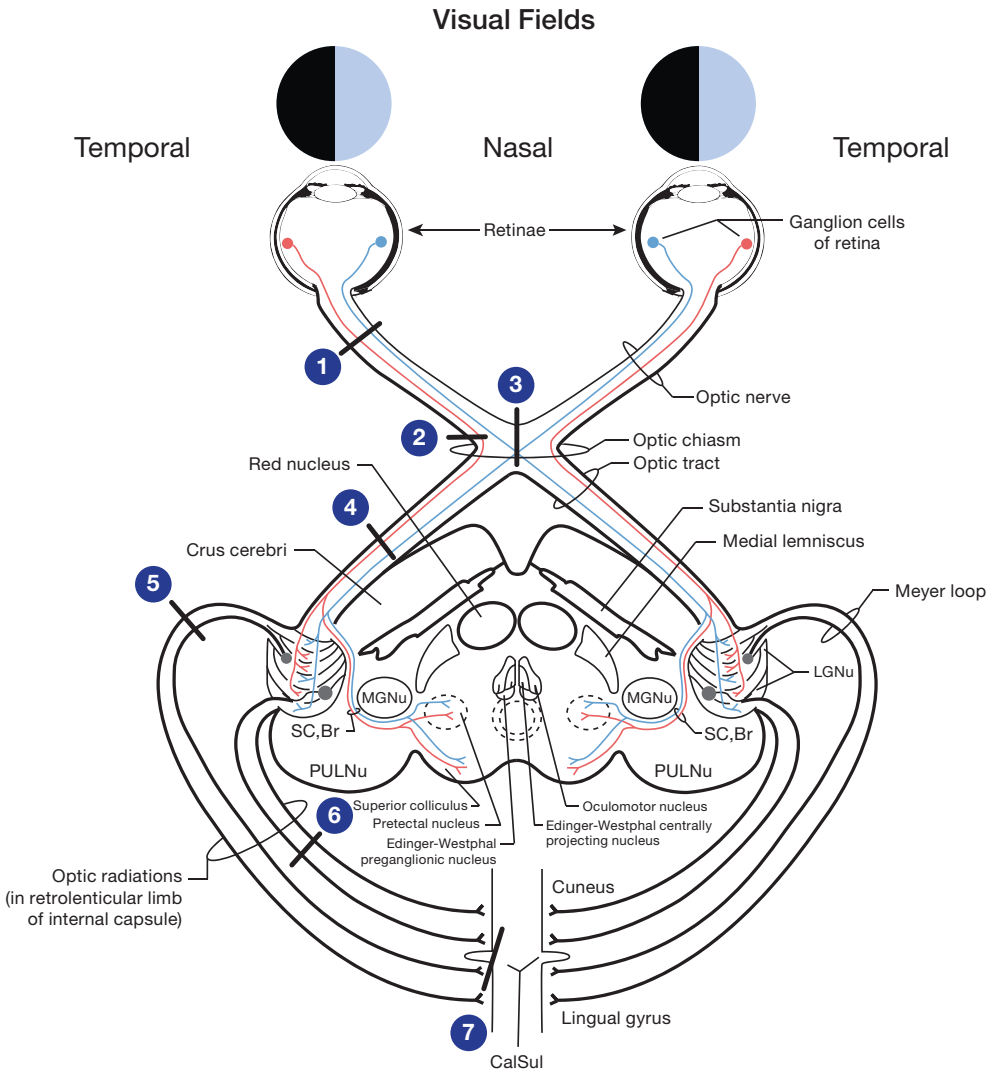

Figure III-8-3. Visual Pathways

1, 2 Optic nerve, 3 Chiasm, 4 Tract

Note

Visual information from **lower** retina courses in **lateral** fibers forming Meyer's **loop**, which projects to the lingual gyrus.

Clinical Correlate

Some Causes of Lesions

1. Optic neuritis, central retinal artery occlusion
2. Internal carotid artery aneurysm
3. Pituitary adenoma (begins as superior quadrantanopia) Craniopharyngioma (begins as inferior quadrantanopia)
4. Vascular
5. Middle cerebral artery (MCA) occlusion

6,7. Posterior cerebral artery occlusion Macula is spared in 7 due to collateral blood supply from MCA.

Note

Lesions to the visual radiations are more common than lesions to the optic tract.

Most fibers from the **optic tract** project to the **lateral geniculate body (LGB)**; some also project to the pretectal area (light reflex), the superior colliculi (reflex gaze), and the suprachiasmatic nuclei (circadian rhythm). The LGB projects to the **primary visual cortex** (striate cortex, Brodmann area 17) of the occipital lobe via the optic radiations.

- Visual information from the lower retina (upper contralateral visual field) → temporal lobe (**Meyer loop**) → **lingual gyrus**
- Visual information from the upper retina (lower contralateral visual field) → parietal lobe → **cuneus gyrus**

Notes

Like a camera, the lens inverts the image of the visual field, so the nasal retina receives information from the temporal visual field, and the temporal retina receives information from the nasal visual field.

At the **optic chiasm**, optic nerve fibers from the nasal half of each retina cross and project to the contralateral optic tract.

The lateral geniculate body (LGB) is a laminated structure that receives input from the optic tract and gives rise to axons that terminate on cells in the primary visual cortex (striate cortex, Brodmann area 17) of the occipital lobe. The LGB laminae maintain a segregation of inputs from the ipsilateral and contralateral retina.

The axons from the LGB that project to the striate cortex are known asoptic radiations, visual radiations, or the geniculocalcarine tract. The calcarine sulcus divides the striate cortex (primary visual cortex or Brodmann area 17) into the cuneus and the lingual gyri. The cuneus gyrus, which lies on the superior bank of the calcarine cortex, receives the medial fibers of the visual radiations. The lingual gyrus, which lies on the inferior bank of the calcarine cortex, receives the lateral fibers of the visual radiation. The medial fibers coursing in the visual radiations, which carry input from the upper retina (i.e., the lower contralateral visual field), pass from the LGB directly through the parietal lobe to reach the cuneus gyrus. Significantly, the lateral fibers coursing in the visual radiations, which carry input from the lower retina (i.e., the upper contralateral visual field), take a circuitous route from the LGB through Meyer loop anteriorly into the temporal lobe. The fibers of Meyer loop then turn posteriorly and course through the parietal lobe to reach the lingual gyrus in the striate cortex.

Clinical Correlate

Unilateral optic nerve lesions are seen in MS, where there is an immune-related inflammatory demyelination of the nerve. The lesion typically presents with a central scotoma due to involvement of the deep fibers in the nerve from the macula.

LESIONS OF THE VISUAL PATHWAYS

Lesions of the retina that include destruction of the macula produce a central scotoma. The macula is quite sensitive to intense light, trauma, aging, and neurotoxins.

Lesions of an optic nerve produce blindness (anopsia) in that eye and a loss of the sensory limb of the light reflex. The pupil of the affected eye constricts when light is shined into the opposite eye (consensual light reflex) but not when light is shined into the blinded eye (absence of direct light reflex).

Compression of the optic chiasm, often the result of a pituitary tumor or meningioma, results in a loss of peripheral vision in both temporal fields because the crossing fibers from each nasal retina are damaged. The resulting visual field defect is called a bitemporal heteronymous hemianopia.

All lesions past the chiasm produce contralateral defects. Lesions of the optic tract result in a loss of visual input from the contralateral visual field. For example, a lesion of the right optic tract results in a loss of input from the left visual field. This is called a homonymous hemianopia; in this example, a left homonymous hemianopia.

Lesions of the visual radiations are more common than lesions to the optic tract or lateral geniculate body and produce visual field defects (a contralateral homonymous hemianopia) similar to those of the optic tract if all fibers are involved.

Lesions restricted to the lateral fibers in Meyer loop, usually in the temporal lobe, result in a loss of visual input from the contralateral upper quarter of the visual field. For example, a lesion of the temporal fibers in the **right** visual radiation results in loss of visual input from the upper left quarter of the field (a **left** superior quadrantanopia).

Lesions restricted to the medial fibers in the visual radiation in the parietal lobe result in a loss of visual input from the contralateral lower quarter of the field (an inferior quadrantanopia).

Lesions inside the primary visual cortex are equivalent to those of the visual radiations, resulting in a contralateral homonymous hemianopsia, except that macular (central) vision is spared.

Lesions of the cuneus gyrus are equivalent to lesions restricted to the parietal fibers of the visual radiation, with macular sparing.

Lesions of the lingula are similar to lesions of the Meyer's loop fibers except for the presence of macular sparing. The pupillary light reflex is spared in lesions of the radiations or inside visual cortex because fibers of the pupillary light reflex leave the optic tracts to terminate in the pretectal area. The combination of blindness with intact pupillary reflexes is termed cortical blindness.

Diencephalon 9

Learning Objectives

- ❑ Interpret scenarios on thalamus
- ❑ Demonstrate understanding of hypothalamus
- ❑ Use knowledge of epithalamus

DIENCEPHALON

The diencephalon can be divided into 4 parts: the thalamus, the hypothalamus, the epithalamus, and the subthalamus.

Table III-9-1. Thalamus

Thalamus—serves as a major sensory relay for information that ultimately reaches the neocortex. Motor control areas (basal ganglia, cerebellum) also synapse in the thalamus before reaching the cortex. Other nuclei regulate states of consciousness.

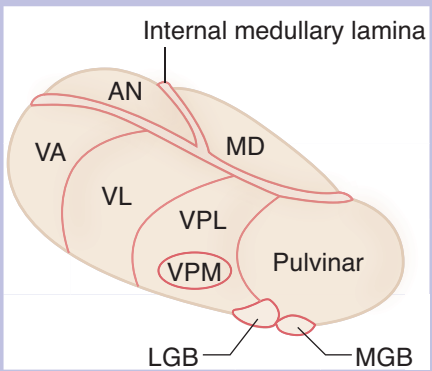

Thalamic Nuclei	Input	Output
VPL	Sensory from **body and limbs**	Somatosensory cortex
VPM	Sensory from **face, taste**	Somatosensory cortex
VA/VL	**Motor** info from BG, cerebellum	Motor cortices
LGB	**Visual** from optic tract	First-degree visual cortex
MGB	**Auditory** from inferior colliculus	First-degree auditory cortex
AN	Mamillary nucleus (via mammillothalamic tract)	Cingulate gyrus (part of **Papez** circuit)
MD	(Dorsomedial nucleus). Involved in **memory** Damaged in **Wernicke-Korsakoff** syndrome	
Pulvinar	Helps integrate somesthetic, visual, and auditory input	
Midline/intralaminar	Involved in **arousal**	

Abbreviations: AN, anterior nuclear group; BG, basal ganglia; LGB, lateral geniculate body; MD, mediodorsal nucleus; MGB, medial geniculate body; VA, ventral anterior nucleus; VL, ventral lateral nucleus; VPL, ventroposterolateral nucleus; VPM, ventroposteromedial nucleus

Thalamus

The thalamus serves as the major sensory relay for the ascending tactile, visual, auditory, and gustatory information that ultimately reaches the neocortex. Motor control areas such as the basal ganglia and cerebellum also synapse in thalamic nuclei before they reach their cortical destinations. Other nuclei participate in the regulation of states of consciousness.

Clinical Correlate

Thiamine deficiency in alcoholics results in degeneration of the dorsomedial nucleus of thalamus and the mammillary bodies, hippocampus, and vermis of the cerebellum.

Major Thalamic Nuclei and Their Inputs and Outputs

Anterior nuclear group (part of the Papez circuit of limbic system)

Input is from the mammillary bodies via the mammillothalamic tract and from the cingulate gyrus; output is to the cingulate gyrus via the anterior limb of the internal capsule.

Medial nuclear group (part of limbic system)

Input is from the amygdala, prefrontal cortex, and temporal lobe; output is to the prefrontal cortex and cingulate gyrus. The most important nucleus is the dorsomedial nucleus.

Clinical Correlate

Thalamic pain syndrome affects the ventral nuclear group. Patients present with burning, aching pain in contralateral limbs or body. Involvement of the dorsal column-medial lemniscal part of VPL increases the sensitivity to pain and presents as contralateral loss of vibratory sense and gait ataxia. Thalamic pain syndrome is resistant to analgesic medications.

Ventral nuclear group

Motor Nuclei

Ventral anterior nucleus (VA): Input to VA is from the globus pallidus, substantia nigra. Output is to the premotor and primary motor cortex.

Ventral lateral nucleus (VL): Input to VL is mainly from the globus pallidus and the dentate nucleus of the cerebellum. Output is to the primary motor cortex (Brodmann area 4).

Sensory Nuclei

Ventral posterolateral (VPL) nucleus: Input to VPL conveying somatosensory and nociceptive information ascends in the medial lemniscus and spinothalamic tract. Output is to primary somatosensory cortex (Brodmann areas 3, 1, and 2) of the parietal lobe.

Ventral posteromedial (VPM) nucleus: Input to VPM is from the ascending trigeminal and taste pathways. Output is to primary somatosensory cortex (Brodmann areas 3, 1, and 2) of the parietal lobe.

Medial geniculate body (nucleus): Input is from auditory information that ascends from the inferior colliculus. Output is to primary auditory cortex.

Lateral geniculate body (nucleus): Input is from the optic tract. Output is in the form of the geniculocalcarine or visual radiations that project to the primary visual (striate) cortex in the occipital lobe.

Midline and Intralaminar Nuclei

Midline and intralaminar nuclei receive input from the brain-stem reticular formation, and from the spinothalamic tract. Intralaminar nuclei send pain information to the cingulate gyrus. These nuclei appear to be important in mediating desynchronization of the EEG during behavioral arousal.

Hypothalamus

The hypothalamus is composed of numerous nuclei that have afferent and efferent connections with widespread regions of the nervous system, including the pituitary gland, the autonomic system, and the limbic system (Figure III-9-1).

Table III-9-2. Hypothalamus, Epithalamus, Subthalamus

Hypothalamus— helps maintain homeostasis; has roles in the autonomic, endocrine, and limbic systems	
Hypothalamic Nuclei	Functions and Lesions
Lateral hypothalamic	**Feeding center;** lesion → starvation
Ventromedial	**Satiety center;** lesion → hyperphagia, obesity, savage behavior
Suprachiasmatic	Regulates circadian rhythms, receives direct retinal input
Supraoptic and paraventricular	Synthesizes **ADH** and **oxytocin; regulates water balance** Lesion → **diabetes insipidus**, characterized by polydipsia and polyuria
Mamillary body	Input from hippocampus; damaged in Wernicke encephalopathy
Arcuate	Produces hypothalamic releasing and inhibiting factors and gives rise to tuberohypophysial tract Has neurons that produce dopamine (prolactin-inhibiting factor)
Anterior region	**Temperature regulation;** lesion → hyperthermia Stimulates the parasympathetic nervous system
Posterior region	**Temperature regulation;** lesion → poikilothermia (inability to thermoregulate) Stimulates sympathetic nervous system
Preoptic area	Regulates release of gonotrophic hormones; contains sexually dimorphic nucleus Lesion before puberty → arrested sexual development; lesion after puberty → amenorrhea or impotence
Dorsomedial	Stimulation → savage behavior
Epithalamus— Consists of pineal body and habenular nuclei. The **pineal body** secretes melatonin with a **circadian rhythm**.	
Subthalamus— The **subthalamic nucleus** is involved in **basal ganglia** circuitry. Lesion → **hemiballismus** (contralateral flinging movements of one or both extremities)	

Abbreviation: ADH, antidiuretic hormone

Clinical Correlate

Dopaminergic projections from the arcuate nuclei inhibit prolactin secretion from the anterior pituitary. Lesions result in galactorrhea (milk discharge) and amenorrhea.

Clinical Correlate

Lesions of the mammillary bodies occur in **Korsakoff syndrome** and are usually associated with thiamine deficiency associated with chronic alcoholism. Korsakoff syndrome results in both anterograde and retrograde amnesia with confabulations.

Major Hypothalamic Regions or Zones, and Their Nuclei

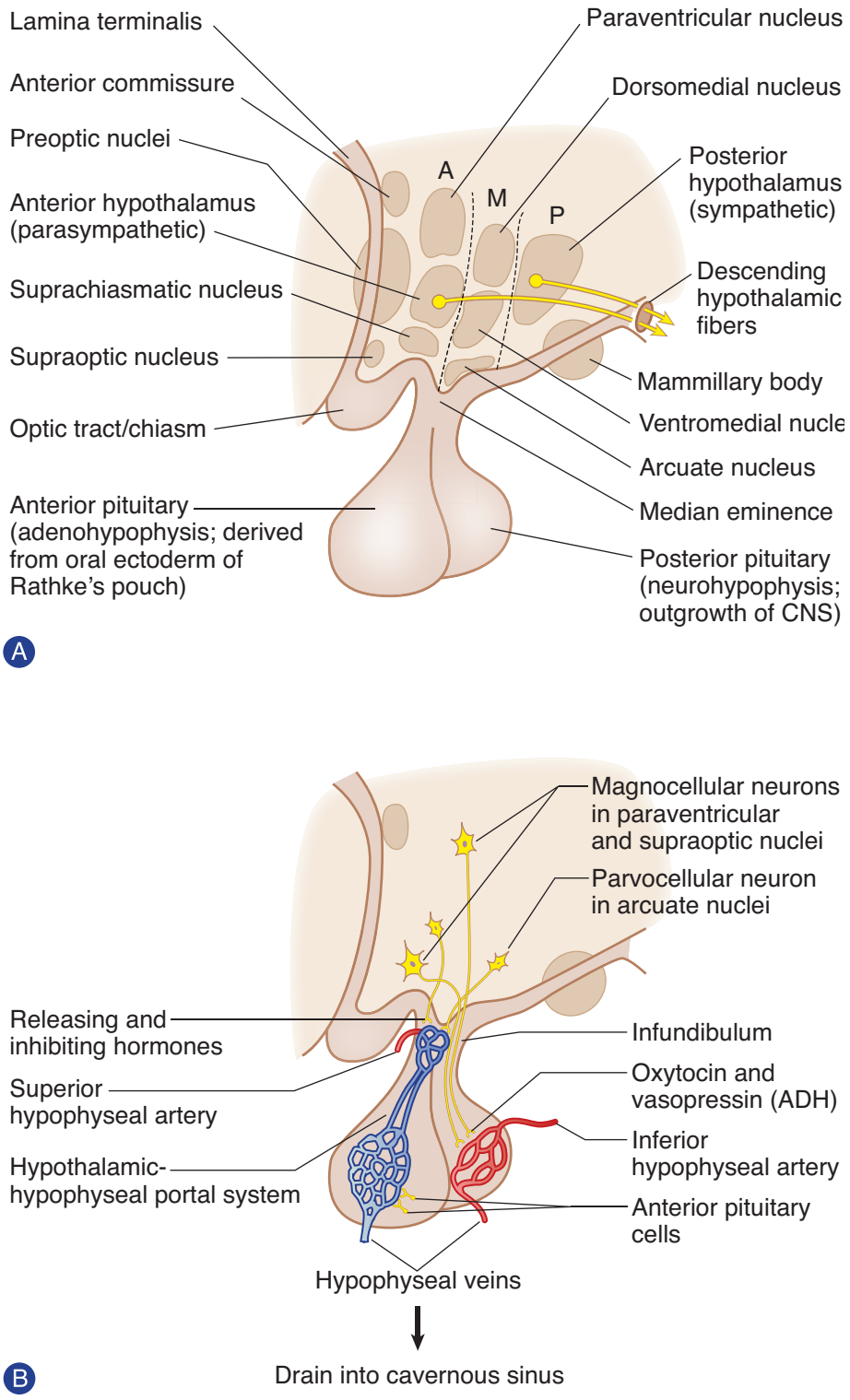

Figure III-9-1. (A) Organization of the Hypothalamus (Sagittal Section) (B) Secretory Mechanisms of the Adeno- and Neuro-Hypophysis

Anterior region

The **paraventricular and supraoptic nuclei** synthesize the neuropeptides antidiuretic hormone (ADH) and oxytocin. Axons arising from these nuclei leave the hypothalamus and course in the supraopticohypophysial tract, which carries neurosecretory granules to the posterior pituitary gland, where they are released into capillaries. Lesions of the supraoptic nuclei lead to diabetes insipidus, which is characterized by polydipsia (excess water consumption) and polyuria (excess urination).

Visual input from the retina by way of the optic tract terminates in the **suprachiasmatic nucleus**. This information helps set certain body rhythms to the 24-hour light-dark cycle (circadian rhythms).

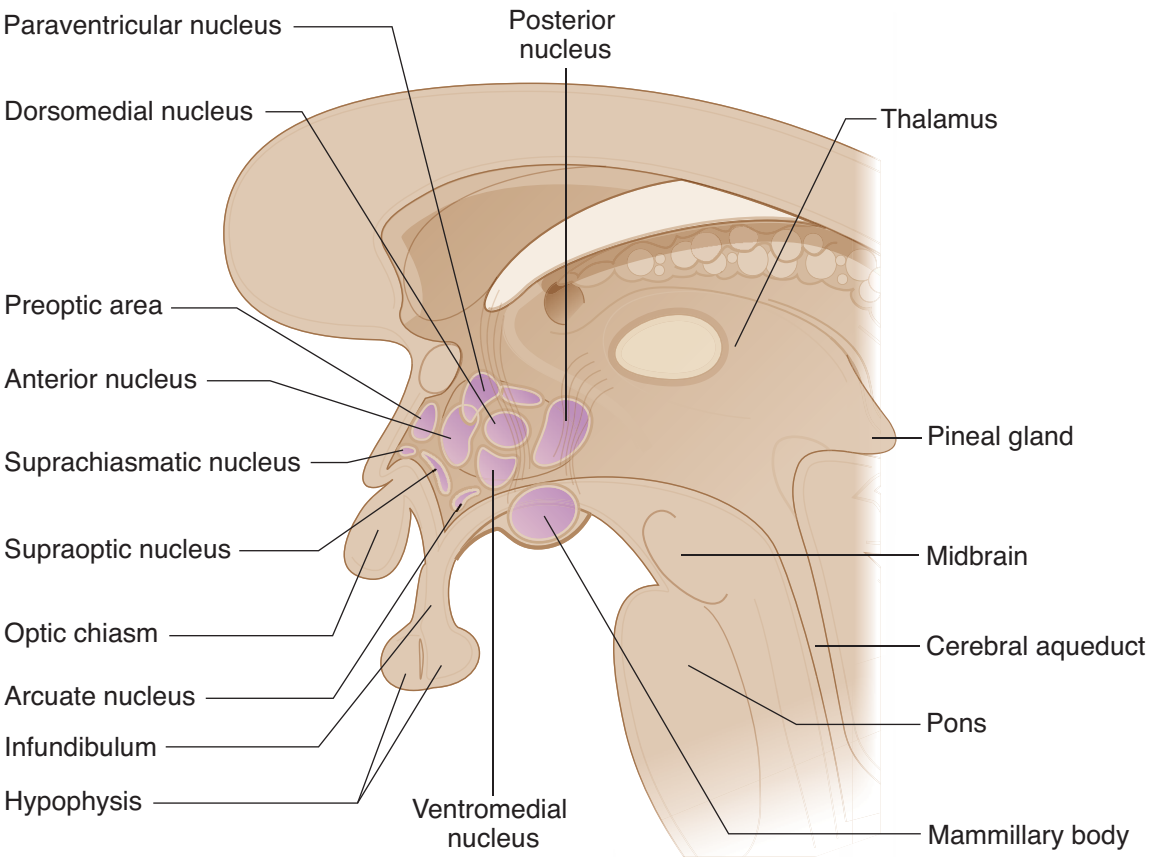

Figure III-9-2. The Hypothalamic Nuclei

Tuberal region

Cells in the **arcuate nucleus** produce releasing hormones and inhibitory factors, which enter capillaries in the tuberoinfundibular tract and pass through the hypophyseal-portal veins to reach the secondary capillary plexus in the anterior pituitary gland. Releasing hormones and inhibitory factors influence the secretory activity of the acidophils and basophils in the anterior pituitary. (See Histology section.)

The **ventromedial hypothalamus** is a satiety center and regulates food intake. Lesions of the ventromedial hypothalamus result in obesity.

Posterior region

The mammillary nuclei are located in the **mammillary bodies** and are part of the limbic system. The mammillothalamic tract originates in the mammillary nuclei and terminates in the anterior nuclear group of the thalamus.

Anterior hypothalamic zone

The anterior hypothalamic zone senses an elevation of body temperature and mediates the response to dissipate heat. Lesions of the anterior hypothalamus lead to hyperthermia.

Posterior hypothalamic zone

The posterior hypothalamic zone senses a decrease of body temperature and mediates the conservation of heat. Lesions of the posterior hypothalamus lead to poikilothermy (i.e., cold-blooded organisms). An individual with a lesion of the posterior hypothalamus has a body temperature that varies with the environmental temperature.

Lateral hypothalamic zone

The lateral hypothalamic zone is a feeding center; lesions of the lateral hypothalamus produce severe aphagia.

Preoptic area

The preoptic area is sensitive to androgens and estrogens, whereas other areas influence the production of sex hormones through their regulation of the anterior pituitary. Before puberty, hypothalamic lesions here may arrest sexual development.

After puberty, hypothalamic lesions in this area may result in amenorrhea or impotence.

Epithalamus

The epithalamus is the part of the diencephalon located in the region of the posterior commissure which consists of the pineal body and the habenular nuclei.

- The pineal body is a small, highly vascularized structure situated above the posterior commissure and attached by a stalk to the roof of the third ventricle. It contains pinealocytes and glial cells but no neurons. Pinealocytes synthesize melatonin, serotonin, and cholecystokinin.
- The pineal gland plays a role in growth, development, and the regulation of circadian rhythms.
- Environmental light regulates the activity of the pineal gland through a retinal–suprachiasmatic– pineal pathway.
- The subthalamus is reviewed with the basal ganglia.

Clinical Correlate

- In young males, pineal lesions may cause **precocious puberty**.
- **Pineal tumors** may cause obstruction of CSF flow and increased intracranial pressure. Compression of the upper midbrain and pretectal area by a pineal tumor results in Parinaud syndrome, in which there is impairment of conjugate vertical gaze and pupillary reflex abnormalities.

Cerebral Cortex 10

Learning Objectives

- Answer questions about general features
- Solve problems concerning language and the dominant hemisphere
- Solve problems concerning blood supply

GENERAL FEATURES

The surface of the cerebral cortex is highly convoluted with the bulges or eminences, referred to as gyri; and the spaces separating the gyri, called sulci. Lobes of the cerebrum are divided according to prominent gyri and sulci that are fairly constant in humans.

Two prominent sulci on the lateral surface are key to understanding the divisions of the hemispheres. The lateral fissure (of Sylvius) separates the frontal and temporal lobes rostrally; further posteriorly, it partially separates the parietal and the temporal lobes. The central sulcus (of Rolando) is situated roughly perpendicular to the lateral fissure. The central sulcus separates the frontal and the parietal lobes. The occipital lobe extends posteriorly from the temporal and parietal lobes, but its boundaries on the lateral aspect of the hemisphere are indistinct. On the medial aspect of the hemisphere, the frontal and parietal lobes are separated by a cingulate sulcus from the cingulate gyrus. The cingulate is part of an artificial limbic lobe. Posteriorly, the parieto-occipital sulcus separates the parietal lobe from the occipital lobe. The calcarine sulcus divides the occipital lobe horizontally into a superior cuneus and an inferior lingual gyrus.

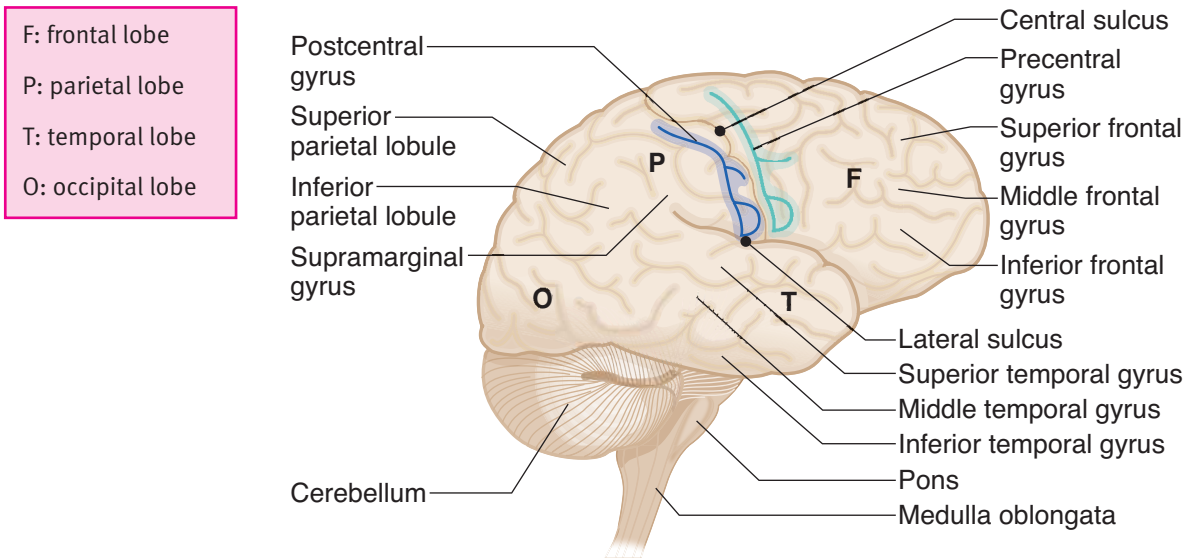

Figure III-10-1. Lateral View of the Right Cerebral Hemisphere

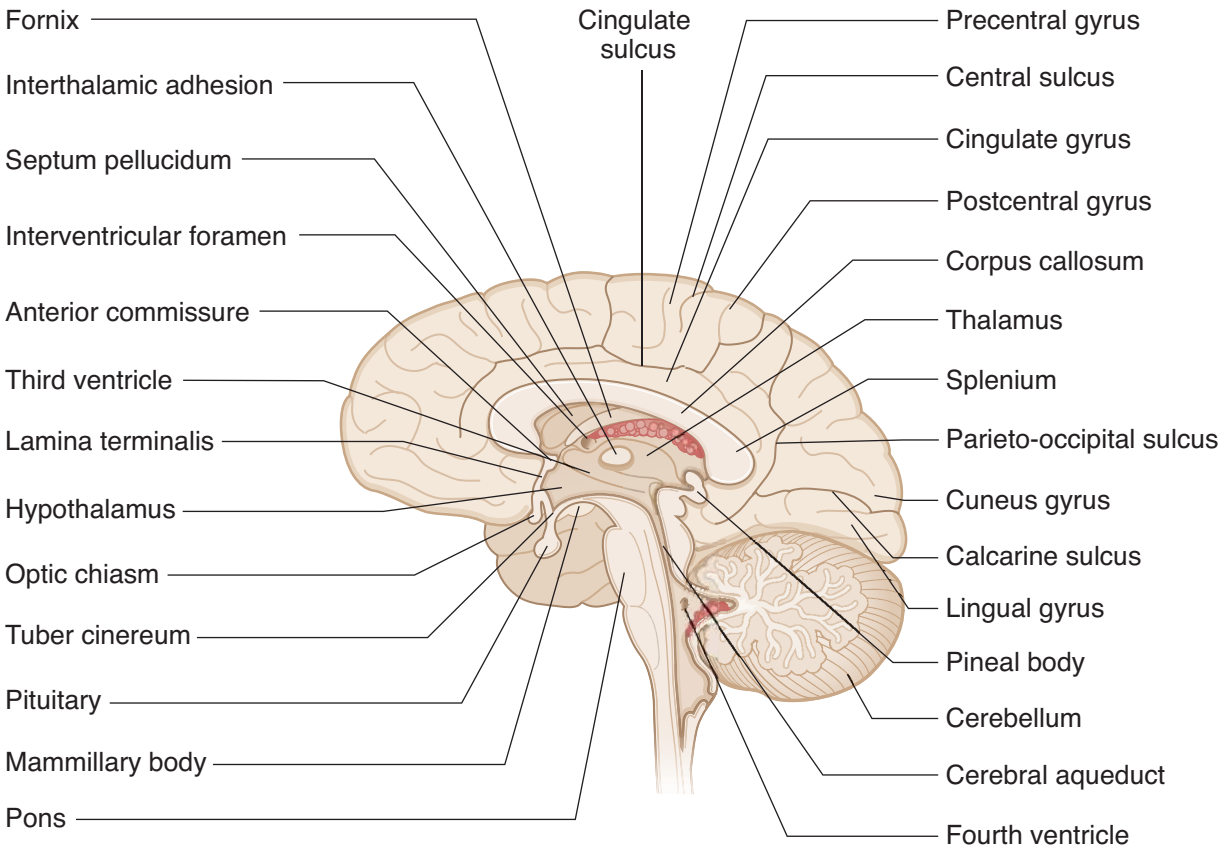

Figure III-10-2. Medial View of the Right Cerebral Hemisphere

About 90% of the cortex is composed of 6 layers, which form the neocortex (Figure III-10-5). The olfactory cortex and hippocampal formation are 3-layered structures and together comprise the allocortex. All of the neocortex contains

a 6-layer cellular arrangement, but the actual structure varies considerably between different locations. On the basis of these variations in the cytoarchitecture, Brodmann divided the cortex into 47 areas, but only a few Brodmann numbers are used synonymously with functionally specific cortical areas.

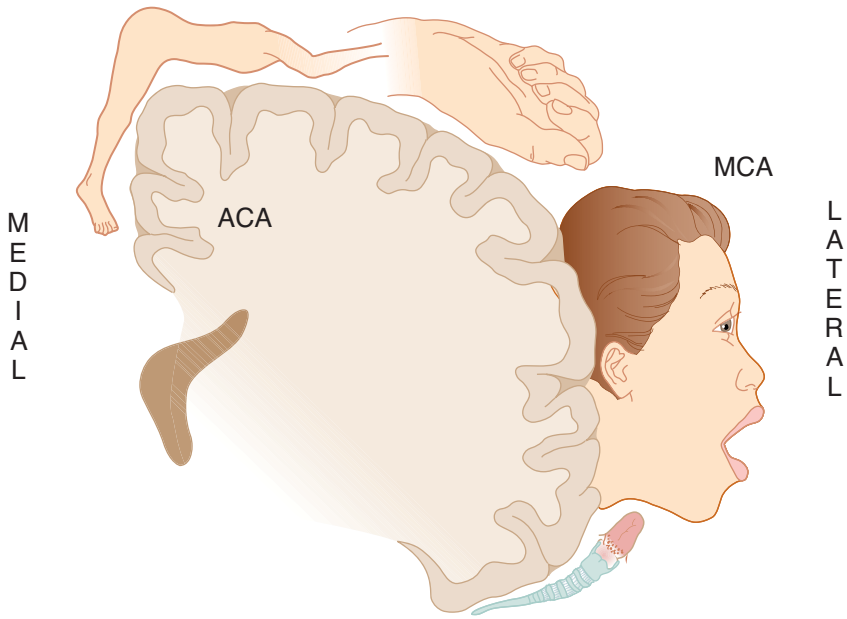

Figure III-10-3. Motor Homunculus in Precentral Gyrus (Area 4) Frontal Lobe (Coronal Section)

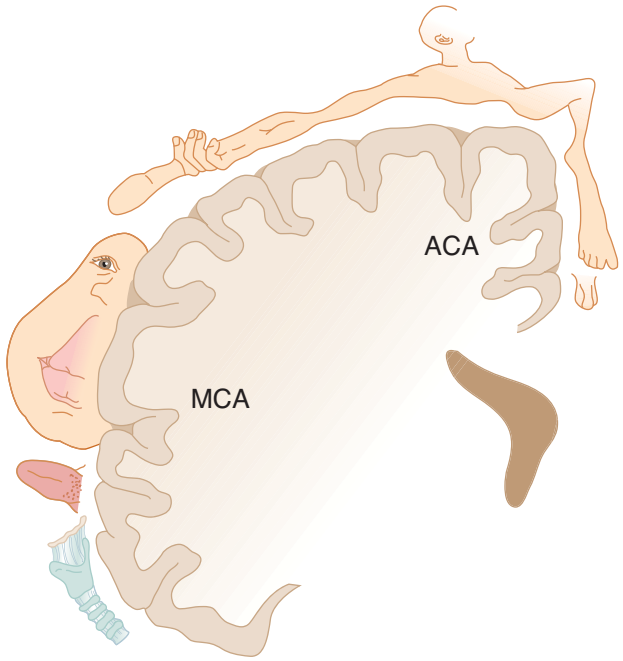

Figure III-10-4. Sensory Homunculus in Postcentral Gyrus (Areas 3, 1, 2) Parietal Lobe (Coronal Section)

Note

The internal granular layer is the site of termination of the thalamocortical projections. In primary visual cortex, these fibers form a distinct Line of Gennari. The internal pyramidal layer gives rise to axons that form the corticospinal and corticobulbar tracts.

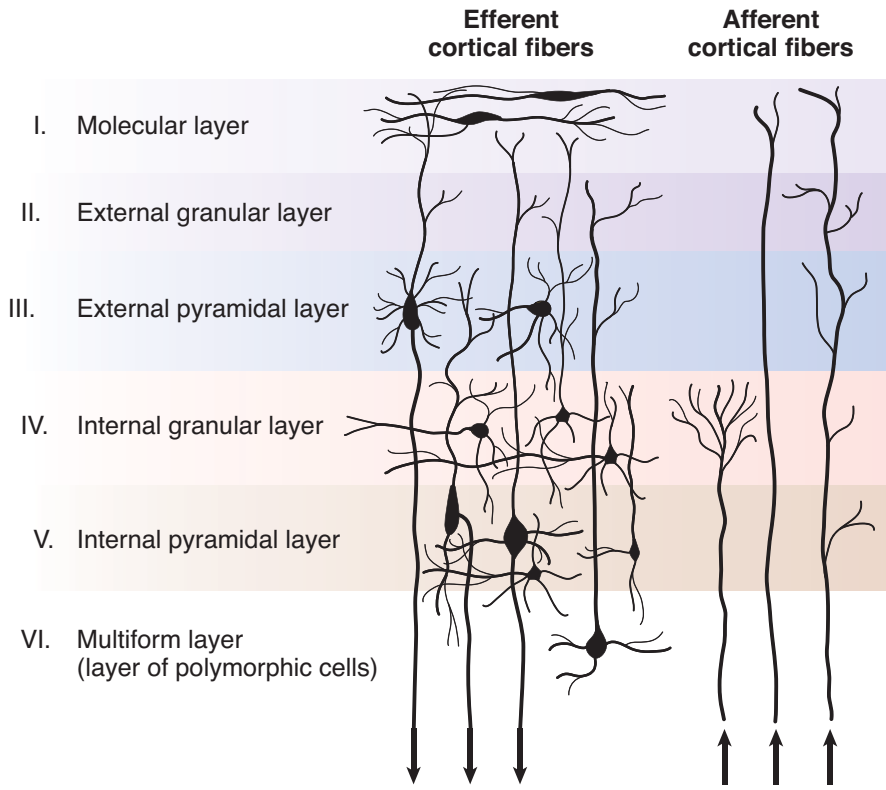

Figure III-10-5. The 6-Layered Neocortex

LANGUAGE AND THE DOMINANT HEMISPHERE

Most people (about 80%) are right-handed, which implies that the left side of the brain has more highly developed hand-controlling circuits. In the vast majority of right-handed people, speech and language functions are also predominantly organized in the left hemisphere. Most left-handed people show language functions bilaterally, although a few, with strong left-handed preferences, show right-sided speech and language functions.

BLOOD SUPPLY

The cortex is supplied by the 2 internal carotid arteries and the 2 vertebral arteries (Figures III-10-6 and III-10-7). On the base (or inferior surface) of the brain, branches of the internal carotid arteries and the basilar artery anastomose to form the circle of Willis. The anterior part of the circle lies in front of the optic chiasm, whereas the posterior part is situated just below the mammillary bodies. The circle of Willis is formed by the terminal part of the internal carotid arteries; the proximal parts of the anterior and posterior cerebral arteries and the anterior and posterior communicating arteries. The middle, anterior, and posterior cerebral arteries, which arise from the circle of Willis, supply all of the cerebral cortex, basal ganglia, and diencephalon.

The internal carotid artery arises from the bifurcation of the common carotid and enters the skull through the carotid canal. It enters the subarachnoid space and terminates by dividing into the anterior and middle cerebral arteries.

Just before splitting into the middle and anterior cerebral arteries, the internal carotid artery gives rise to the ophthalmic artery. The ophthalmic artery enters the orbit through the optic canal and supplies the eye, including the retina and optic nerve.

The middle cerebral artery is the larger terminal branch of the internal carotid artery. It supplies the bulk of the lateral surface of the hemisphere. Exceptions are the superior inch of the frontal and parietal lobes, which are supplied by the anterior cerebral artery, and the inferior part of the temporal lobe and the occipital pole, which are supplied by the posterior cerebral artery. The middle cerebral artery also supplies the genu and posterior limb of the internal capsule and the basal ganglia.

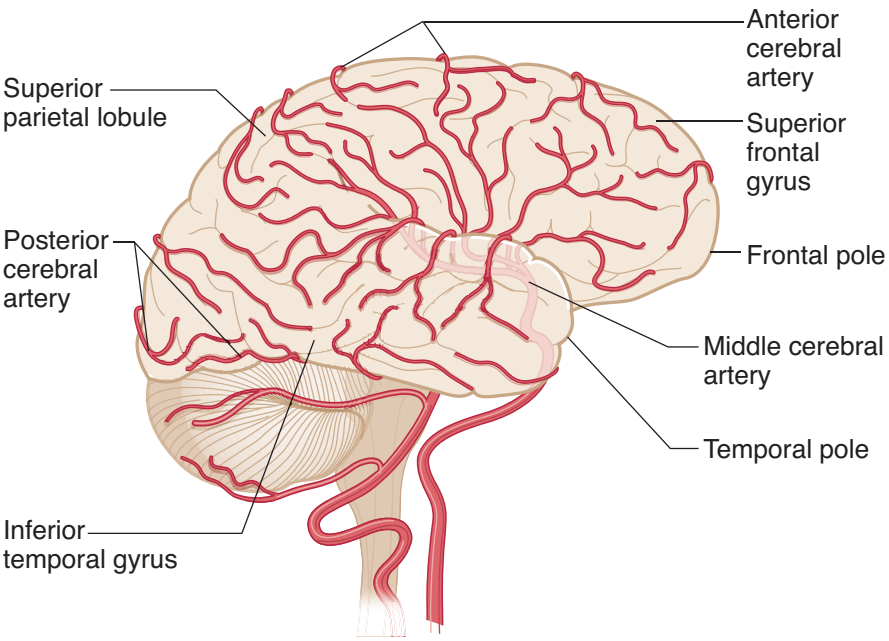

Figure III-10-6. The Distributions of the Cerebral Arteries: Part 1

The anterior cerebral artery is the smaller terminal branch of the internal carotid artery. It is connected to the opposite anterior cerebral artery by the anterior communicating artery, completing the anterior part of the circle of Willis. The anterior cerebral artery supplies the medial surface of the frontal and parietal lobes, which include motor and sensory cortical areas for the pelvis and lower limbs. The anterior cerebral artery also supplies the anterior four-fifths of the corpus callosum and approximately 1 inch of the frontal and parietal cortex on the superior aspect of the lateral aspect of the hemisphere.

Occlusion of the anterior cerebral artery results in spastic paresis of the contralateral lower limb and anesthesia of the contralateral lower limb. Urinary incontinence may be present, but this usually occurs only with bilateral damage. A transcortical apraxia of the left limbs may result from involvement of the anterior portion of the corpus callosum. A transcortical apraxia occurs because the left hemisphere (language dominant) has been disconnected from the motor cortex of the right hemisphere. The anterior cerebral artery also supplies the anterior limb of the internal capsule.

Clinical Correlate

Occlusion of the middle cerebral artery results in spastic paresis of the contralateral lower face and upper limb and anesthesia of the contralateral face and upper limb.

An aphasia (e.g., Broca, Wernicke, or conduction) may result when branches of the left middle cerebral artery are affected, and left-sided neglect may be seen with a blockage of branches of the right middle cerebral artery to the right parietal lobe.

The middle cerebral artery also supplies the proximal parts of the visual radiations as they emerge from the lateral geniculate nucleus of the thalamus and course in Meyer's loop. These fibers course into the temporal lobe before looping posteriorly to rejoin the rest of the visual radiation fibers.

Occlusion of the branches that supply Meyer's loop fibers in the temporal lobe results in a contralateral superior quadrantanopsia.

Note

The middle cerebral artery (MCA) supplies:

- the lateral surface of the frontal, parietal, and upper temporal lobes
- the posterior limb and genu of the internal capsule
- most of the basal ganglia

Note

The anterior cerebral artery (ACA) supplies medial surface of frontal and parietal lobes; anterior 4/5 of corpus callosum; anterior limb of internal capsule

The posterior cerebral artery (PCA) supplies occipital lobe; lower temporal lobe; splenium; midbrain

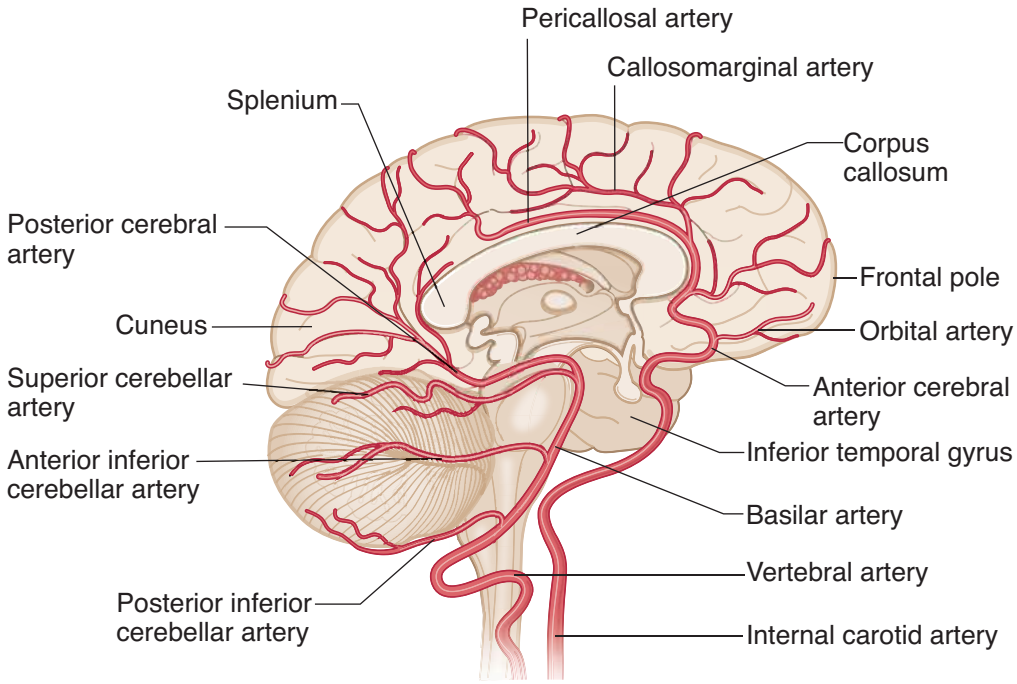

Figure III-10-7. The Distributions of the Cerebral Arteries: Part 2

Clinical Correlate

The most common aneurysm site in the circle of Willis is where the anterior communicating artery joins an anterior cerebral artery.

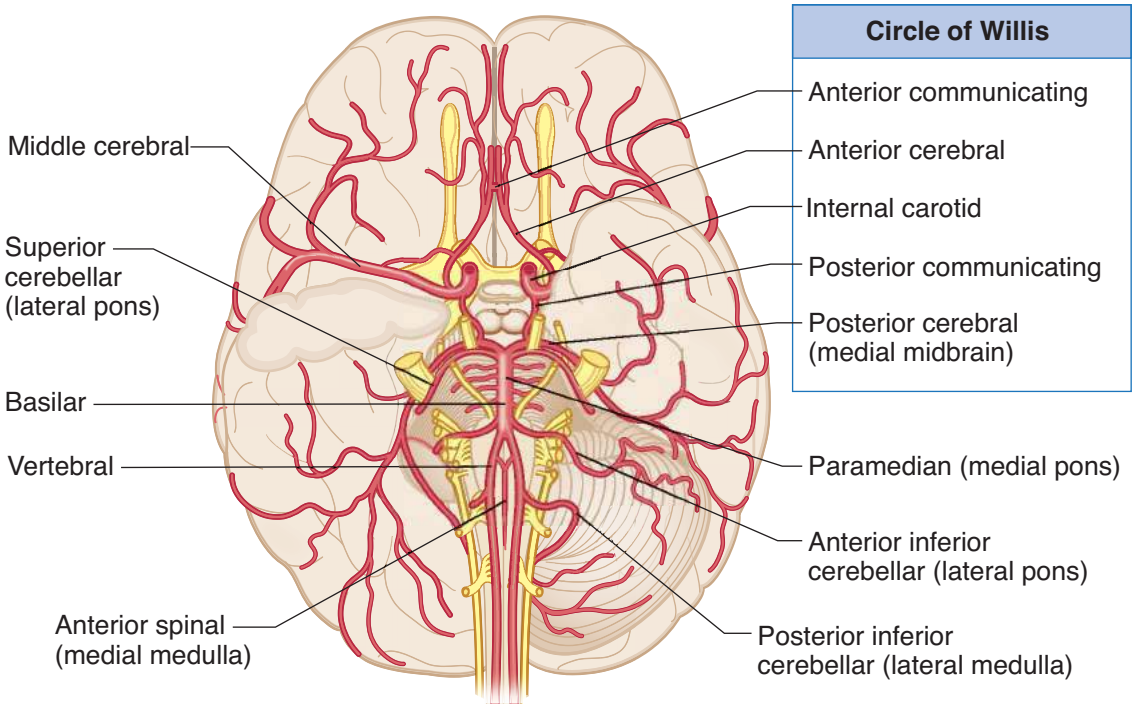

Figure III-10-8. Arterial Supply of the Brain

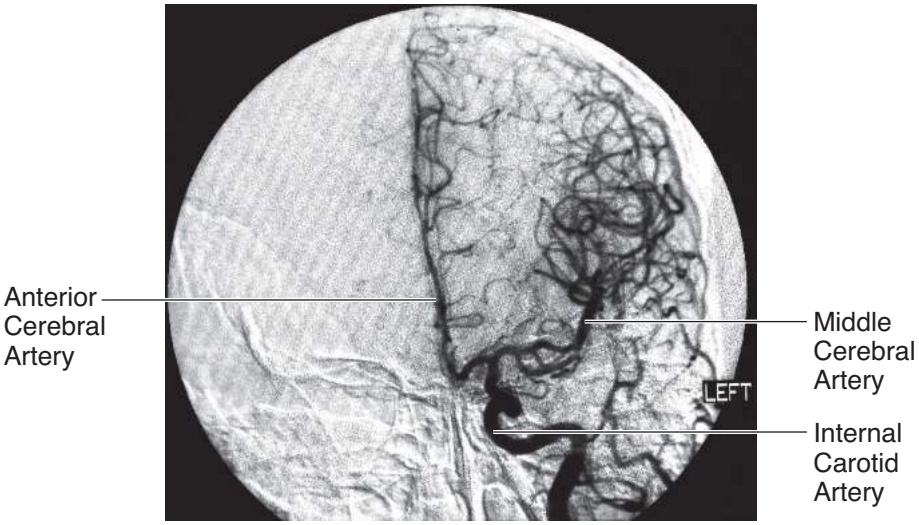

Figure III-10-9. Anteroposterior View of Left Internal Carotid

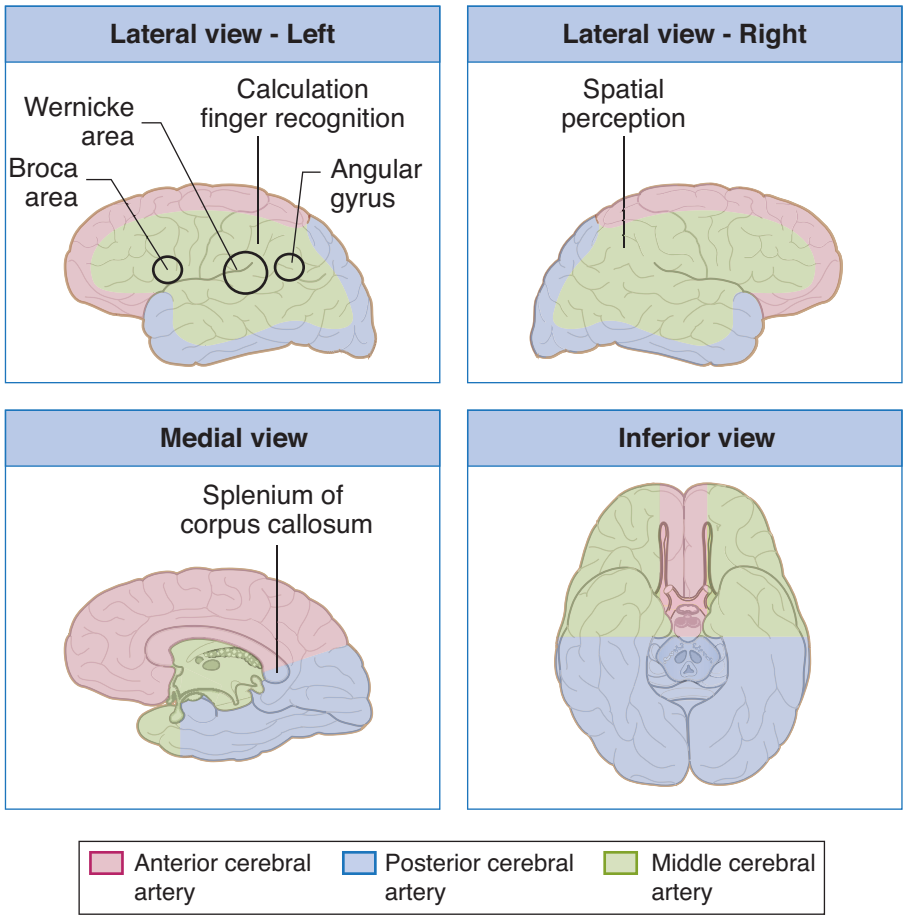

Figure III-10-10. Territories Supplied by the Cerebral Arteries

The posterior cerebral artery is formed by the terminal bifurcation of the basilar artery. The posterior communicating artery arises near the termination of the internal carotid artery and passes posteriorly to join the posterior cerebral artery. The posterior communicating arteries complete the circle of Willis by joining the vertebrobasilar and carotid circulations. The posterior cerebral artery supplies the occipital and temporal cortex on the inferior and lateral surfaces of the hemisphere, the occipital lobe and posterior 2/3 of the temporal lobe on the medial surface of the hemisphere, and the thalamus and subthalamic nucleus.

Occlusion of the posterior cerebral artery results in a homonymous hemianopia of the contralateral visual field with macular sparing.

Table III-10-1. Cerebrovascular Disorders

Disorder	Types	Key Concepts
Cerebral infarcts	Thrombotic	**Anemic/pale** infarct; usually atherosclerotic complication
	Embolic	**Hemorrhagic/red** infarct; from heart or atherosclerotic plaques; **middle cerebral artery** most vulnerable to emboli
	Hypotension	**"Watershed"** areas and deep cortical layers most affected
	Hypertension	Lacunar infarcts; basal ganglia, internal capsule, and pons most affected
Hemorrhages	Epidural hematoma	Almost always traumatic Rupture of **middle meningeal artery** after skull fracture Lucid interval before loss of consciousness ("talk and die" syndrome)
	Subdural hematoma	Usually caused by trauma Rupture of **bridging veins** (drain brain to dural sinuses)
	Subarachnoid hemorrhage	**Ruptured berry aneurysm** is most frequent cause Predisposing factors: Marfan syndrome, Ehlers-Danlos type 4, adult polycystic kidney disease, hypertension, smoking
	Intracerebral hemorrhage	Common causes: hypertension, trauma, infarction

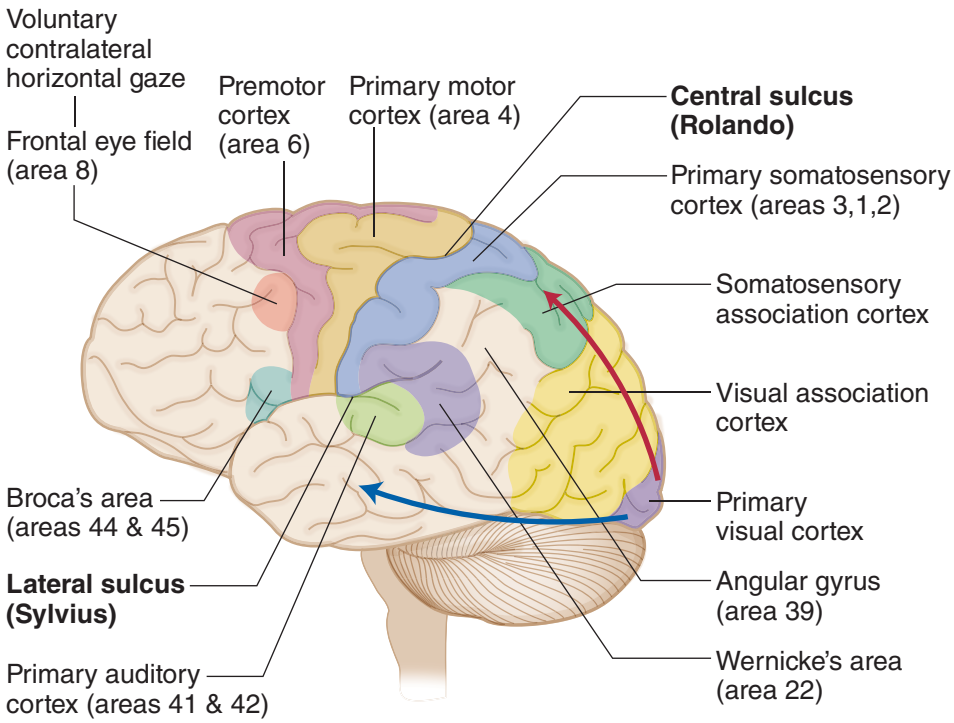

Figure III-10-11. Cerebral Cortex: Functional Areas of Left (Dominant) Hemisphere

Frontal Lobe

A large part of the frontal cortex rostral to the central sulcus is related to the control of movements, primarily on the opposite side of the body. These areas include primary motor cortex (Brodmann area 4), premotor cortex (area 6), the frontal eye field (area 8), and the motor speech areas of Broca (area 44 and 45). Traditionally, area 4 is considered the primary motor cortex. It is in the precentral gyrus, immediately anterior to the central sulcus, and contains an orderly skeletal motor map of the contralateral side of the body.

The muscles of the head are represented most ventrally closest to the lateral fissure; then, proceeding dorsally, are the regions for the neck, upper limb, and trunk on the lateral aspect of the hemisphere. On the medial aspect of the hemisphere is the motor representation for the pelvis and lower limb.

Premotor cortex

Just anterior to area 4 is the premotor cortex (area 6). Neurons here are particularly active prior to the activation of area 4 neurons, so it is thought that the premotor cortex is involved in the planning of motor activities. Damage here results in an apraxia, a disruption of the patterning and execution of learned motor movements. Individual movements are intact, and there is no weakness, but the patient is unable to perform movements in the correct sequence.

Clinical Correlate

Lesion of the Frontal Eye Field

The frontal eye field lies in front of the motor cortex in Brodmann area 8. This cortical area is the center for contralateral horizontal gaze. A lesion here results in an inability to make voluntary eye movements toward the contralateral side. Because the activity of the intact frontal eye field in the opposite cortex would also be unopposed after such a lesion, the result is conjugate slow deviation of the eyes toward the side of the lesion.

If motor cortex is involved in the lesion, the patient may have a contralateral spastic paresis. The intact frontal eye field in the opposite hemisphere deviates the eyes **away** from the paralyzed limbs.

Prefrontal cortex

The prefrontal cortex is located in front of the premotor area and represents about a quarter of the entire cerebral cortex in the human brain. This area is involved in organizing and planning the intellectual and emotional aspects of behavior, much as the adjacent premotor cortex is involved in planning its motor aspects.

Clinical Correlate

Lesions in the Prefrontal Area

Lesions in the prefrontal area produce what is called the frontal lobe syndrome. The patient cannot concentrate and is easily distracted; there is a general lack of initiative, foresight, and perspective. Another common aspect is apathy (i.e., severe emotional indifference). Apathy is usually associated with abulia, a slowing of intellectual faculties, slow speech, and decreased participation in social interactions. Prefrontal lesions also result in the emergence of infantile suckling or grasp reflexes that are suppressed in adults. In the suckling reflex, touching the cheek causes the head to turn toward the side of the stimulus as the mouth searches for a nipple to suckle. In the grasp reflex, touching the palm of the hand results in a reflex closing of the fingers, which allows an infant to grasp anything that touches the hand.

Clinical Correlate

Expressive Aphasia

Broca area is just anterior to the motor cortex region that provides upper motoneuron innervation of cranial nerve motor nuclei. This area in the left or dominant hemisphere is the center for motor speech and corresponds to Brodmann areas 44 and 45. Damage to Broca area produces a motor, nonfluent, or expressive aphasia that reflects a difficulty in piecing together words to produce expressive speech. Patients with this lesion can understand written and spoken language but normally say almost nothing. When pressed on a question such as "What did you do today?" they might reply "Went town." The ability to write is usually also affected in a similar way (agraphia) in all aphasias, although the hand used for writing can be used normally in all other tasks. Patients are keenly aware of and frustrated by an expressive aphasia, because of their lack of the ability to verbalize their thoughts orally or in writing.

Broca area damage often extends posteriorly into the primary motor cortex and might be combined with a contralateral paralysis of the muscles of the lower face, resulting in a drooping of the corner of the mouth. If the lesion is larger, the patient might have a spastic hemiparesis of the contralateral upper limb.

Parietal Lobe

Primary somatosensory cortex

The parietal lobe begins just posterior to the central sulcus with the postcentral gyrus. The postcentral gyrus corresponds to Brodmann areas 3, 1, and 2 and contains primary somatosensory cortex. Like primary motor cortex, there is a similar somatotopic representation of the body here, with head, neck, upper limb, and trunk represented on the lateral aspect of the hemisphere, and pelvis and lower limb represented medially. These areas are concerned with discriminative touch, vibration, position sense, pain, and temperature. Lesions in somatosensory cortex result in impairment of all somatic sensations on the opposite side of the body, including the face and scalp.

Posterior parietal association cortex

Just posterior and ventral to the somatosensory areas is the posterior parietal association cortex, including Brodmann areas 5 and 7.

Clinical Correlate

Lesions, usually in the dominant hemisphere and which include areas 5 and 7 of the posterior parietal association areas, often result in apraxia (also seen with lesions to the premotor cortex). Apraxia is a disruption of the patterning and execution of learned motor movements. This deficit seems to reflect a lack of understanding how to organize the performance of a pattern of movements (i.e., what should be done first, then next, etc.). The patient may be unable, for example, to draw a simple diagram (constructional apraxia) or describe how to get from his home to his work.

Another deficit, with lesions of areas 5 and 7 is astereognosia (inability to recognize objects by touch). There is no loss of tactile or proprioceptive sensation; rather, it is the integration of visual and somatosensory information that is impaired. Both apraxia and astereognosia are more common after left hemisphere damage than in right hemisphere damage. The astereognosia is usually confined to the contralateral side of the body; in contrast, apraxia is usually bilateral. Apraxia is probably a result of the loss of input to the premotor cortex (area 6), which is involved in the actual organization of motor movements into a goal-directed pattern.

Wernicke area

The inferior part of the parietal lobe and adjacent part of the temporal lobe in the dominant (left) hemisphere, known as Wernicke area, are cortical regions that function in language comprehension. At a minimum, Wernicke area consists of area 22 in the temporal lobe but may also include areas 39 and 40 in the parietal lobe. Areas 39 (the angular gyrus) and 40 (the supramarginal gyrus) are regions of convergence of visual, auditory, and somatosensory information.

Note

Any blockage of the left middle cerebral artery that results in an aphasia (Broca Wernicke, conduction) or Gerstmann syndrome will also result in **agraphia.**

Clinical Correlate

Receptive Aphasia

Lesions in area 22 in the temporal lobe and area 39 or 40 in the parietal lobe produce a fluent, receptive, or Wernicke aphasia. The patient with Wernicke aphasia cannot comprehend spoken language and may or may not be able to read (alexia) depending on the extent of the lesion. The deficit is characterized by fluent verbalization but lacks meaning. Patients are paraphasic, often misusing words as if speaking using a "word salad."

Patients with Wernicke aphasia are generally unaware of their deficit and show no distress as a result of their condition.

Gerstmann Syndrome

If the lesion is confined to just the angular gyrus (area 39), the result is a loss of ability to comprehend written language (alexia) and to write it (agraphia), but spoken language may be understood. Alexia with agraphia in pure angular gyrus lesions is often seen with 3 other unique symptoms: acalculia (loss of the ability to perform simple arithmetic problems), finger agnosia (inability to recognize one's fingers), and right–left disorientation. This constellation of deficits constitutes Gerstmann syndrome and underscores the role of this cortical area in the integration of how children begin to count, add, and subtract using their fingers.

Conduction Aphasia

There is a large fiber bundle connecting areas 22, 39, and 40 with Broca area in the frontal lobe, known as the superior longitudinal fasciculus (or the arcuate fasciculus). A lesion affecting this fiber bundle results in a conduction aphasia. In this patient, verbal output is fluent, but there are many paraphrases and word-finding pauses. Both verbal and visual language comprehension are also normal, but if asked to, the patient cannot repeat words or execute verbal commands by an examiner (such as "Count backwards beginning at 100") and also demonstrates poor object naming. This is an example of a disconnect syndrome in which the deficit represents an inability to send information from one cortical area to another. As with an expressive aphasia, these patients are aware of the deficit and are frustrated by their inability to execute a verbal command that they fully understand.

Transcortical Apraxia

Lesions to the corpus callosum caused by an infarct of the anterior cerebral artery may result in another type of disconnect syndrome known as a transcortical apraxia. As in other cases of apraxia, there is no motor weakness, but the patient cannot execute a command to move the left arm. They understand the command, which is perceived in the Wernicke area of the left hemisphere, but the callosal lesion disconnects the Wernicke area from the right primary motor cortex so that the command cannot be executed. The patient is still able to execute a command to move the right arm because Wernicke area in the left hemisphere is able to communicate with the left primary motor cortex without using the corpus callosum.

Asomatognosia

The integration of visual and somatosensory information is important for the formation of the "body image" and awareness of the body and its position in space. Widespread lesions in areas 7, 39, and 40 in the nondominant right parietal lobe may result in unawareness or neglect of the contralateral half of the body, known as asomatognosia. Although somatic sensation is intact, the patients ignore half of their body and may fail to dress, undress, or wash the affected (left) side. Patients will have no visual field deficits, so they can see, but deny the existence of things in the left visual field. Asking them to bisect a horizontal line produces a point well to the right of true center. If asked to draw a clock face from memory, they will draw only the numbers on the right side, ignoring those on the left. Patients may deny that the left arm or leg belongs to them when the affected limb is passively brought into their field of vision. Patients may also deny their deficit, an anosognosia.

Occipital Lobe

The occipital lobe is essential for the reception and recognition of visual stimuli and contains primary visual and visual association cortex.

Visual cortex

The visual cortex is divided into striate (area 17) and extrastriate (areas 18 and 19). Area 17, also referred to as the primary visual cortex, lies on the medial portion of the occipital lobe on either side of the calcarine sulcus. Its major thalamic input is from the lateral geniculate nucleus. Some input fibers are gathered in a thick bundle that can be visible on the cut surface of the gross brain, called the line of Gennari. The retinal surface (and therefore the visual field) is represented in an orderly manner on the surface of area 17, such that damage to a discrete part of area 17 will produce a scotoma (i.e., a blind spot) in the corresponding portion of the visual field. A unilateral lesion inside area 17 results in a contralateral homonymous hemianopsia with macular sparing, usually caused by an infarct of a branch of the posterior cerebral artery. The area of the macula of the retina containing the fovea is spared because of a dual blood supply from both the posterior and middle cerebral arteries. The actual cortical area serving the macula is represented in the most posterior part of the occipital lobe. Blows to the back of the head or a blockage in occipital branches of the middle cerebral artery that supply this area may produce loss of macular representation of the visual fields. Bilateral visual cortex lesions result in cortical blindness; the patient cannot see, but pupillary reflexes are intact.

Visual association cortex

Anterior to the primary visual or striate cortex are extensive areas of visual association cortex. Visual association cortex is distributed throughout the entire occipital lobe and in the posterior parts of the parietal and temporal lobes. These regions receive fibers from the striate cortex and integrate complex visual input from both hemispheres. From the retina to the visual association cortex, information about form and color, versus motion, depth and spatial information are processed separately. Form and color information is processed by the parvocellular-blob system. This "cone stream" originates mainly in the central part of the retina, relays through separate layers of the lateral geniculate, and projects to blob zones of primary visual cortex.

Blob zones project to the inferior part of the temporal lobe in areas 20 and 21. Unilateral lesions here result in achromatopsia, a complete loss of color vision in the contralateral hemifields. Patients see everything in shades of gray. Additionally, these patients may also present with prosopagnosia, an inability to recognize faces.

Motion and depth are processed by the magnocellular system. This "rod stream" originates in the peripheral part of the retina, relays through separate layers of the lateral geniculate, and projects to thick stripe zones of primary visual cortex. Striped areas project through the middle temporal lobe to the parietal lobe in areas 18 and 19. Lesions here result in a deficit in perceiving visual motion; visual fields, color vision, and reading are unaffected.

Clinical Correlate

Visual Agnosia

Damage to parts of the temporal lobes involving the cone stream produces a visual agnosia. Visual agnosia is the inability to recognize visual patterns (including objects) in the absence of a visual field deficit. For example, you might show a patient with an object agnosia a pair of glasses, and the patient would describe them as 2 circles and a bar. Lesions in areas 20 and 21 of the temporal lobe that also include some destruction of adjacent occipital lobe in either hemisphere result in prosopagnosia, a specific inability to recognize faces. The patient can usually read and name objects. The deficiency is an inability to form associations between faces and identities. On hearing the voice of the same person, the patient can immediately identify the person.

Alexia Without Agraphia

A principal "higher-order" deficit associated with occipital lobe damage is alexia without agraphia (or pure word blindness). The patients are unable to read at all and, curiously, often have a color anomia (inability to name colors). However, they are able to write. This is another example of a disconnect syndrome in which information from the occipital lobe is not available to the parietal or frontal lobes to either understand or express what has been seen.

(Recall that alexia *with* agraphia–inability to read or write–occurs with lesions encompassing the angular gyrus in the dominant parietal lobe.) The cause of the syndrome is usually an infarction of the left posterior cerebral artery that affects not only the anterior part of the occipital lobe but the splenium of the corpus callosum. Involvement of the left occipital cortex results in a right homonymous hemianopsia with macular sparing. Involvement of the splenium of the corpus callosum prevents visual information from the intact right occipital cortex from reaching language comprehension centers in the left hemisphere. Patients can see words in the left visual field but do not understand what the words mean.

Temporal Lobe

Primary auditory cortex

On its superior and lateral aspect, the temporal lobe contains the primary auditory cortex. Auditory cortex (areas 41 and 42) is located on the 2 transverse gyri of Heschl, which cross the superior temporal lobe deep within the lateral sulcus. Much of the remaining superior temporal gyrus is occupied by area 22 (auditory association cortex), which receives a considerable projection from both areas 41 and 42 and projects widely to both parietal and occipital cortices.

Patients with unilateral damage to the primary auditory cortex show little loss of auditory sensitivity but have some difficulty in localizing sounds in the contralateral sound field. Area 22 is a component of Wernicke area in the dominant hemisphere, and lesions here produce a Wernicke aphasia.

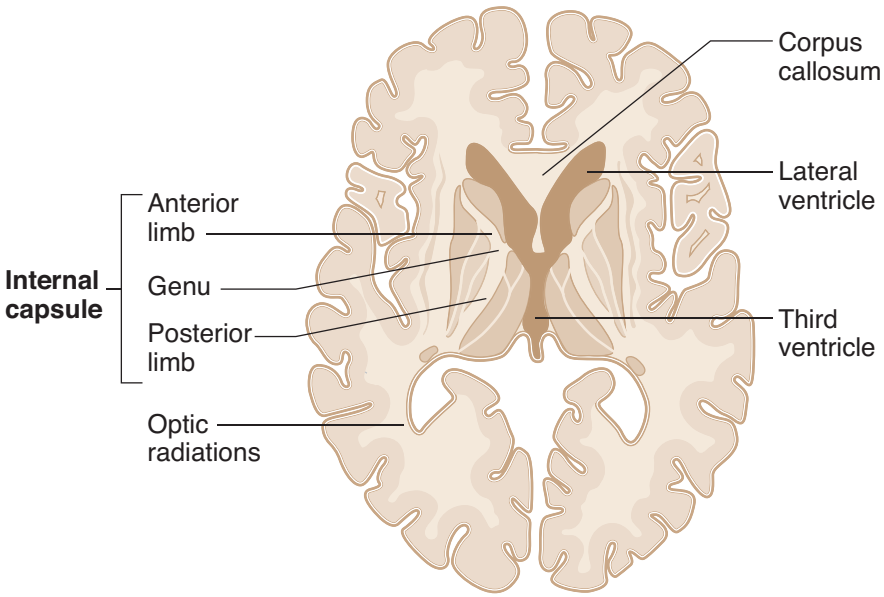

Figure III-10-12. Internal Capsule: Arterial Supply

Table III-10-2. Internal Capsule: Arterial Supply

Internal Capsule	Arterial Supply	Tracts
Anterior limb	Medial striate br. of ACA	Thalamocortical
Genu	Lenticulostriate br. of MCA	Corticobulbar
Posterior limb	Lenticulostriate br. of MCA	Corticospinal, all somatosensory thalamocortical projections

Note: The posterior cerebral artery also supplies the optic radiations.
Abbreviations: ACA, anterior cerebral artery; MCA, middle cerebral artery

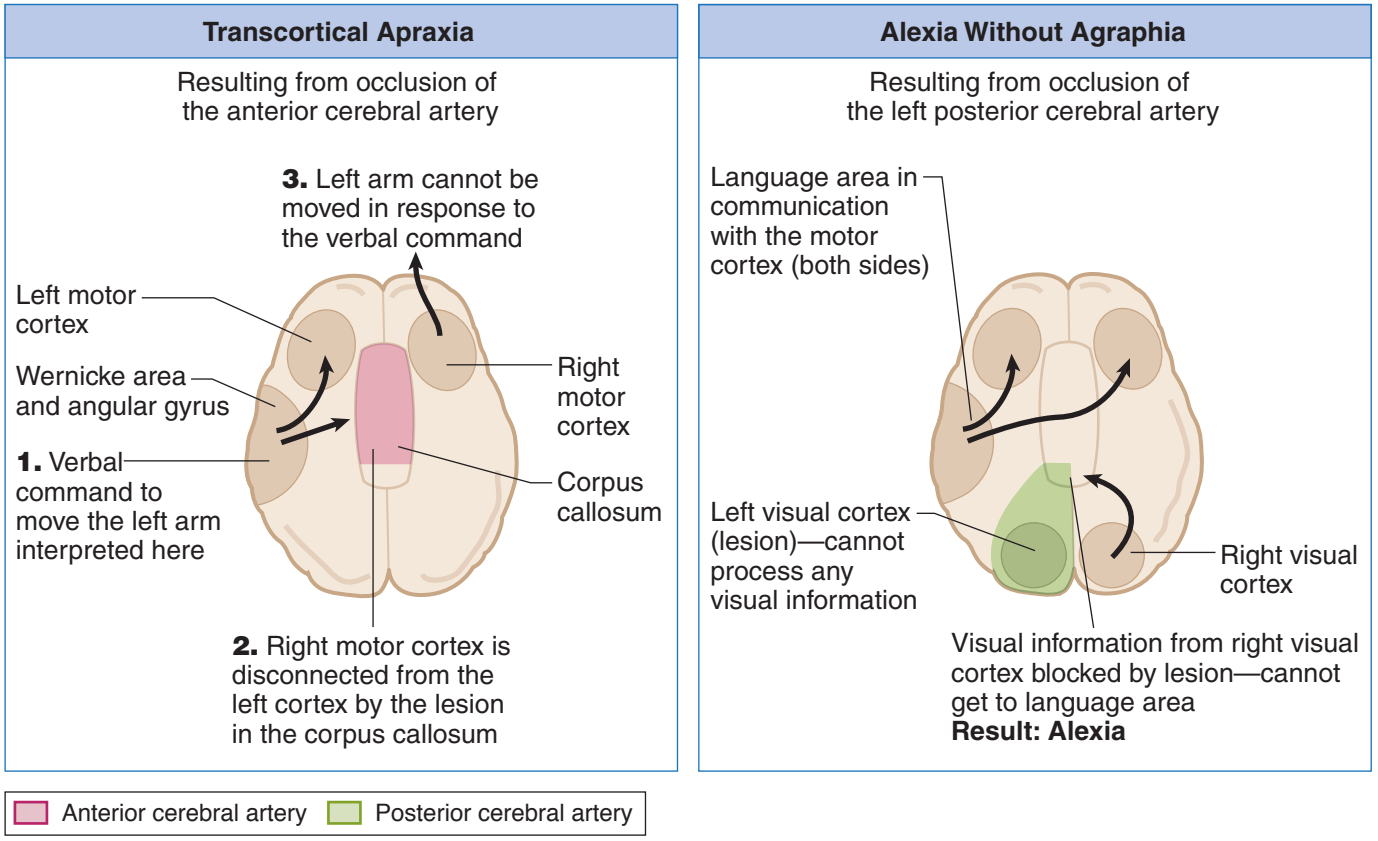

Figure III-10-13. Disconnect Syndromes

Table III-10-3. CNS Blood Supply and Stroke-related Deficits

System	Primary Arteries	Branches	Supplies	Deficits after Stroke
Vertebrobasilar (posterior circulation)	**Vertebral arteries**	**Anterior spinal artery**	Anterior two-thirds of spinal cord	Dorsal columns spared; all else bilateral
		Posterior inferior cerebellar (PICA)	Dorsolateral medulla	See Brain-Stem Lesions in Chapter IV-5.
	Basilar artery	Pontine arteries	Base of pons	
		Anterior inferior cerebellar artery (AICA)	Inferior cerebellum, cerebellar nuclei	
		Superior cerebellar artery	Dorsal cerebellar hemispheres; superior cerebellar peduncle	
		Labyrinthine artery (sometimes arises from AICA)	Inner ear	
	Posterior cerebral arteries	—	Midbrain, thalamus, occipital lobe	**Contralateral hemianopia with macular sparing** Alexia without agraphia*
Internal carotid (anterior circulation)	Ophthalmic artery	Central artery of retina	Retina	Blindness
	Posterior communicating artery	—	—	Second most common **aneurysm** site (often with CN III palsy)
	Anterior cerebral artery	—	Primary motor and sensory cortex (leg/foot)	Contralateral spastic paralysis and anesthesia of **lower limb** Frontal lobe abnormalities
	Anterior communicating artery	—	—	Most common site of **aneurysm**
	Middle cerebral artery	Outer cortical	Lateral convexity of hemispheres	Contralateral spastic paralysis and anesthesia of **upper limb/face** **Gaze palsy Aphasia*** Gerstmann syndrome* Hemi inattention and neglect of contralateral body†
		Lenticulostriate	Internal capsule, caudate, putamen, globus pallidus	

*If dominant hemisphere is affected (usually the left)

†Right parietal lobe lesion

Table III-10-4. Key Features of Lobes

Lobes	Important Regions	Deficit After Lesion
Frontal	Primary motor and premotor cortex	Contralateral spastic paresis (region depends on area of homunculus affected), premotor: apraxia
	Frontal eye fields	Eyes deviate to ipsilateral side
	Broca speech area* (Areas 44, 45)	**Broca aphasia (expressive, nonfluent aphasia):** patient can understand written and spoken language, but speech and writing are slow and effortful; patients are aware of their problem; often associated with right arm weakness and right lower face weakness.
	Prefrontal cortex	**Frontal lobe syndrome:** symptoms can include poor judgment, difficulty concentrating and problem solving, apathy, inappropriate social behavior
Parietal	Primary somatosensory cortex	Contralateral hemihypesthesia (region depends on area of homunculus affected)
	Superior parietal lobule	Contralateral astereognosis/apraxia
	Inferior parietal lobule (Angular gyrus; Area 39)	**Gerstmann syndrome** (if dominant hemisphere): right/left confusion, alexia, dyscalculia and dysgraphia, finger agnosia, contralateral hemianopia or lower quadrantanopia; unilateral neglect (nondominant)
Temporal	Primary auditory cortex	Bilateral damage → deafness Unilateral leads to slight hearing loss
	Wernicke area* (Area 22)	**Wernicke aphasia (receptive, fluent aphasia):** patient cannot understand any form of language; speech is fast and fluent, but not comprehensible
	Hippocampus	Bilateral lesions lead to inability to consolidate short-term to long-term memory
	Amygdala	**Klüver-Bucy syndrome:** hyperphagia, hypersexuality, visual agnosia
	Olfactory bulb, tract, primary cortex	Ipsilateral anosmia
	Meyer loop (visual radiations)	Contralateral upper quadrantanopia ("pie in the sky")
Occipital	Primary visual cortex	Cortical blindness if bilateral; macular sparing hemianopia

*In the dominant hemisphere. Eighty percent of people are left-hemisphere dominant.

Limbic System 11

Learning Objectives

- ❑ Solve problems concerning general features
- ❑ Solve problems concerning olfactory system
- ❑ Demonstrate understanding of limbic system

GENERAL FEATURES

The limbic system is involved in emotion, memory, attention, feeding, and mating behaviors. It consists of a core of cortical and diencephalic structures found on the medial aspect of the hemisphere. A prominent structure in the limbic system is the hippocampal formation on the medial aspect of the temporal lobe. The hippocampal formation extends along the floor of the inferior horn of the lateral ventricle in the temporal lobe and includes the hippocampus, the dentate gyrus, the subiculum, and adjacent entorhinal cortex. The hippocampus is characterized by a 3-layered cerebral cortex. Other limbic-related structures include the amygdala, which is located deep in the medial part of the anterior temporal lobe rostral to the hippocampus, and the septal nuclei, located medially between the anterior horns of the lateral ventricle. The limbic system is interconnected with thalamic and hypothalamic structures, including the anterior and dorsomedial nuclei of the thalamus and the mammillary bodies of the hypothalamus. The cingulate gyrus is the main limbic cortical area. The cingulate gyrus is located on the medial surface of each hemisphere above the corpus callosum. Limbic-related structures also project to wide areas of the prefrontal cortex.

Note

Functions of the Limbic System

- Visceral—smell
- Sex drive
- Memory/Learning
- Behavior and emotions

OLFACTORY SYSTEM

Central projections of olfactory structures reach parts of the temporal lobe without a thalamic relay and the amygdala. The olfactory nerve consists of numerous fascicles of the central processes of bipolar neurons, which reach the anterior cranial fossa from the nasal cavity through openings in the cribriform plate of the ethmoid bone. These primary olfactory neurons differ from other primary sensory neurons in 2 ways. First, the cell bodies of these neurons, which lie scattered in the olfactory mucosa, are not collected together in a sensory ganglion, and second, primary olfactory neurons are continuously replaced. The life span of these cells ranges from 30 to 120 days in mammals.

Within the mucosa of the nasal cavity, the peripheral process of the primary olfactory neuron ramifies to reach the surface of the mucous membrane. The central processes of primary olfactory neurons terminate by synapsing with neurons found in the olfactory bulb. The bulb is a 6-layered outgrowth of the brain that rests on the cribriform plate. Olfactory information entering the

olfactory bulb undergoes a great deal of convergence before the olfactory tract carries axons from the bulb to parts of the temporal lobe and amygdala.

Clinical Correlate

Alzheimer disease results from neurons, beginning in the hippocampus, that exhibit neurofibrillary tangles and amyloid plaques. Other nuclei affected are the cholinergic neurons in the nucleus basalis of Meynert, noradrenergic neurons in the locus coeruleus, and serotonergic neurons in the raphe nuclei. Patients with Down syndrome commonly present with Alzheimer in middle age because chromosome 21 is one site of a defective gene.

Clinical Correlate

Olfactory deficits may be incomplete (hyposmia), distorted (dysosmia), or complete (anosmia). Olfactory deficits are caused by transport problems or by damage to the primary olfactory neurons or to neurons in the olfactory pathway to the central nervous system (CNS). Head injuries that fracture the cribriform plate can tear the central processes of olfactory nerve fibers as they pass through the plate to terminate in the olfactory bulb, or they may injure the bulb itself. Because the olfactory bulb is an outgrowth of the CNS covered by meninges, separation of the bulb from the plate may tear the meninges, resulting in cerebrospinal fluid (CSF) leaking through the cribriform plate into the nasal cavity.

LIMBIC SYSTEM

The limbic system is involved in emotion, memory, attention, feeding, and mating behaviors. It consists of a core of cortical and diencephalic structures found on the medial aspect of the hemisphere. The limbic system modulates feelings, such as fear, anxiety, sadness, happiness, sexual pleasure, and familiarity.

The Papez Circuit

A summary of the simplified connections of the limbic system is expressed by the Papez circuit (Figure III-11-1). The Papez circuit oversimplifies the role of the limbic system in modulating feelings, such as fear, anxiety, sadness, happiness, sexual pleasure, and familiarity; yet, it provides a useful starting point for understanding the system. Arbitrarily, the Papez circuit begins and ends in the hippocampus. Axons of hippocampal pyramidal cells converge to form the fimbria and, finally, the fornix. The fornix projects mainly to the mammillary bodies in the hypothalamus. The mammillary bodies, in turn, project to the anterior nucleus of the thalamus by way of the mammillothalamic tract. The anterior nuclei project to the cingulate gyrus through the anterior limb of the internal capsule, and the cingulate gyrus communicates with the hippocampus through the cingulum and entorhinal cortex.

The amygdala functions to attach an emotional significance to a stimulus and helps imprint the emotional response in memory.

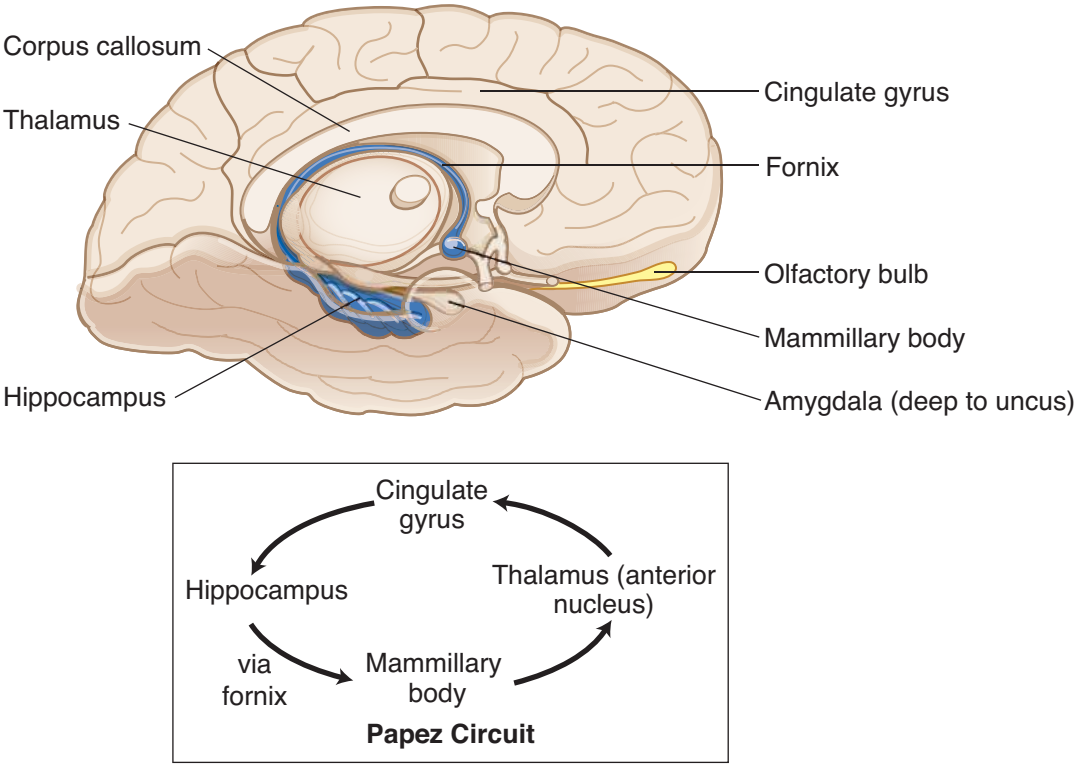

Figure III-11-1. The Limbic System and Papez Circuit

Limbic Structures and Function

- Hippocampal formation (hippocampus, dentate gyrus, the subiculum, and entorhinal cortex)
- Amygdala
- Septal nuclei
- The hippocampus is important in learning and memory. The amygdala attaches an emotional significance to a stimulus and helps imprint the emotional response in memory.

Limbic Connections

- The limbic system is interconnected with anterior and dorsomedial nuclei of the thalamus and the mammillary bodies.
- The cingulate gyrus is the main limbic cortical area.
- Limbic-related structures also project to wide areas of the prefrontal cortex.
- Central projections of olfactory structures reach parts of the temporal lobe and the amygdala.

Papez Circuit

Axons of hippocampal pyramidal cells converge to form the fimbria and, finally, the fornix. The fornix projects mainly to the mammillary bodies in

the hypothalamus. The mammillary bodies project to the anterior nucleus of the thalamus (mammillothalamic tract). The anterior nuclei project to the cingulate gyrus, and the cingulate gyrus projects to the entorhinal cortex (via the cingulum). The entorhinal cortex projects to the hippocampus (via the perforant pathway).

Clinical Correlate

Anterograde Amnesia

Bilateral damage to the medial temporal lobes including the hippocampus results in a profound loss of the ability to acquire new information, known as anterograde amnesia.

Korsakoff Syndrome

Anterograde amnesia is also observed in patients with Korsakoff syndrome. Korsakoff syndrome is seen mainly in alcoholics who have a thiamine deficiency and often follows an acute presentation of Wernicke encephalopathy. Wernicke encephalopathy presents with ocular palsies, confusion, and gait ataxia and is also related to a thiamine deficiency. In Wernicke-Korsakoff syndrome, lesions are always found in the mammillary bodies and the dorsomedial nuclei of the thalamus.

In addition to exhibiting an anterograde amnesia, Korsakoff patients also present with retrograde amnesia. These patients confabulate, making up stories to replace past memories they can no longer retrieve.

Klüver-Bucy Syndrome

Klüver-Bucy syndrome results from bilateral lesions of the amygdala and hippocampus. These lesions result in:

- Placidity–there is marked decrease in aggressive behavior; the subjects become passive, exhibiting little emotional reaction to external stimuli.
- Psychic blindness–objects in the visual field are treated inappropriately. For example, monkeys may approach a snake or a human with inappropriate docility.
- Hypermetamorphosis–visual stimuli (even old ones) are repeatedly approached as though they were completely new.
- Increased oral exploratory behavior–monkeys put everything in their mouths, eating only appropriate objects.
- Hypersexuality and loss of sexual preference
- Anterograde amnesia

Alzheimer Disease

- Alzheimer disease accounts for 60% of all cases of dementia. The incidence increases with age.
- **Clinical:** insidious onset, progressive memory impairment, mood alterations, disorientation, aphasia, apraxia, and progression to a bedridden state with eventual death
- Five to 10% of Alzheimer cases are hereditary, early onset, and transmitted as an autosomal dominant trait.

Lesions involve the neocortex, hippocampus, and subcortical nuclei, including forebrain cholinergic nuclei (i.e., basal nucleus of Meynert). These areas show atrophy, as well as characteristic microscopic changes. The earliest and most severely affected areas are the hippocampus and temporal lobe, which are involved in learning and memory.

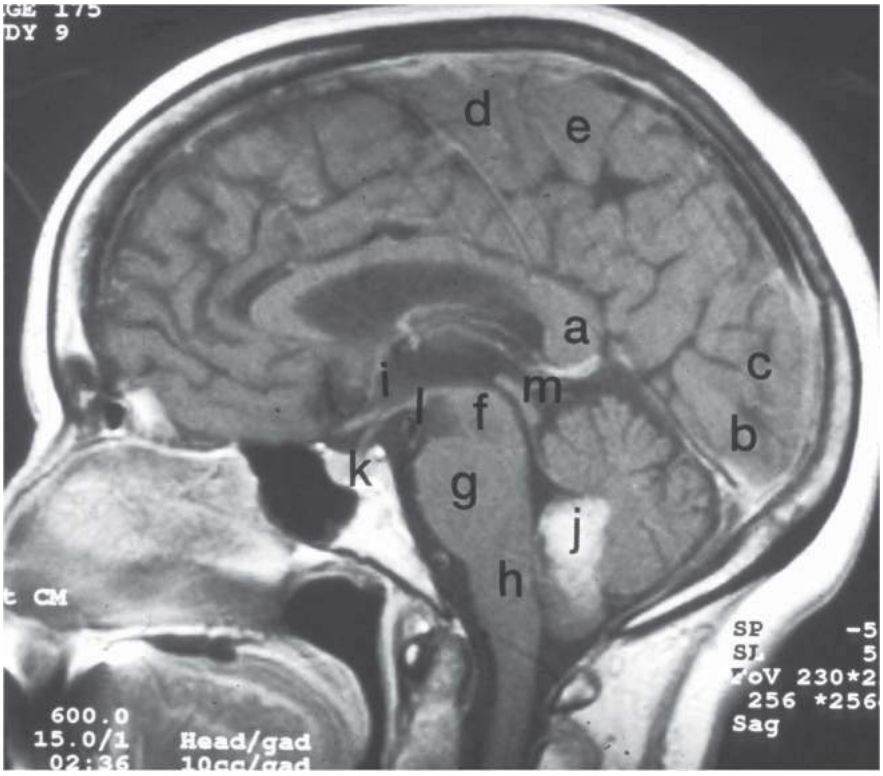

Figure III-11-2. MRI of Medial View of the Central Nervous System

(a) Corpus callosum (splenium) (b) Lingual gyrus (c) Cuneus gyrus (d) Primary motor cortex (e) Primary somatosensory cortex (f) Midbrain (g) Pons (h) Medulla (i) Hypothalamus in wall of third ventricle (j) Posterior vermis of cerebellum with intracerebral hemorrhage (k) Pituitary (l) Mammillary body (m) Pineal

Index

A

Abdominal aortic hiatus, 70
Accessory nucleus, 296
Accommodation of lens, 339
Acetylcholine (ACh), 121, 331, 335
Acetylcholinesterase (AChE), 236, 238
Acidosis
  metabolic. *See* Metabolic acidosis
  respiratory. *See* Respiratory acidosis
Acini, 14, 17, 128, 129, 130
Acoustic neuromas, 255
Acrosome, 167
Adductor brevis innervation, 204
Adductor longus, 102
Adductor magnus innervation, 204
Adrenal cortex mesoderm embryology, 239
Adrenal glands, 107, 155
Adrenal medulla ectoderm embryology, 12, 239
Adult polycystic kidney disease, 360
Aganglionic megacolon, 117
Agraphia, 363, 364, 366, 369
Alar plate, 235
Albuminocytologic dissociation in Guillain-Barré syndrome, 251
Alexia, 364, 366, 369
Alkalosis
  metabolic. *See* Metabolic alkalosis
  respiratory. *See* Respiratory alkalosis
Allantois, 103, 141, 144
Alpha motoneurons, 266, 270, 271, 284
Alveolar macrophages, 57, 58, 59
Alveoli (lungs), 56, 58
Alzheimer disease, 19, 248, 372, 375
Amnesia, 350, 374
Amnion, 9, 10
Ampulla (oviduct), 7, 174, 176, 177
Ampulla (semicircular canal), 302, 305
Amygdala, 371, 372, 373, 374
Amyotrophic lateral sclerosis (ALS), 248, 285
Anal canal, 103, 107, 116, 137, 157, 160, 163
Analgesia, 277
Analgesic medication, 348
Anal triangle, 160, 162, 163
anatomy
  anatomy
    brain, 354
Androstenedione from corpus luteum, 177
Anemia, 286
Anencephaly, 236, 238
Angiotensin via lung endothelium, 51
Angular gyrus, 361, 363, 364, 366
Anhydrosis, 37
Ankle, 205, 206, 213, 270
Annular pancreas, 110
Anopsia, 345
Anorectal canal, 143, 144
Anterior cerebral arteries
  anatomy, 357, 358
  issues, 368, 369
Anterior commissure, 332
Anterior communicating arteries, 313, 357, 369
Anterior cruciate ligament (ACL), 212, 213
Anterior division fibers (brachial plexus), 187
Anterior inferior cerebellar arteries, 313, 316, 358, 369
Anterior interventricular artery, 83
Anterior interventricular sulcus, 83
Anterior mediastinum, 70
Anterior neuropore, 236, 238
Anterior nuclear group, 348, 347, 371, 373
Anterior pituitary, 239, 12, 176
Anterior spinal artery
  anatomy, 358
  occlusion, 314, 369
Anterior superior iliac spine, 94, 95, 109, 191, 220, 310, 323, 331, 339, 354
Anterolateral system
  anatomy, 275, 291, 277, 278
  lesions, 276, 280
Antidiuretic hormone (ADH), 349, 350
Anulus fibrosus, 29, 31
Aorta
  anatomy, 44, 86, 107, 134, 139
  atherosclerotic plaques, 134
  coarctation, 73
  fetal circulation, 61
  radiology, 56, 90
Aortic arch, 86, 196, 219
Aortic arch, 72
Aortic hiatus, 134
Aortic hiatus, 70
Aortic insufficiency, 82
Aorticolpulmonary (AP) septum, 66, 239
Aortic semilunar valve, 81, 82
Aortic vestibule, 60
Apathy from prefrontal lesions, 362
Aphasia, 357, 362, 363, 364, 369, 375
Appendix, 103, 107, 115
Apraxia, 260, 361, 363, 364, 375
Aqueous humor, 337
Arachnoid granulations, 259, 260, 227
Arachnoid mater
  cranial meninges, 259, 225, 226
  embryology, 12
  spinal meninges, 31, 238, 263
  subarachnoid space, 238
  subdural hematoma, 229
Arcuate fibers (sensory system), 275
Arcuate nuclei, 351
Areflexia, 273
Arginine vasopressin. *See* Antidiuretic hormone (ADH)
Argyll Robertson pupil, 339
Argyll Robertson pupil, 282
Arnold-Chiari malformation, 238, 285
Ascending colon, 103, 107, 108
Ascending pharyngeal artery, 217, 218
Asomatognosia, 365
Astereognosis, 276, 286, 363
Asterixis, 334
Astrocytes, 239, 249, 238, 12, 19
Astrocytoma, 255
Ataxias, 280, 286, 325, 327, 374
Athetosis, 334, 335
Atonic bladder, 146, 284
Atria
  anatomy, 84
  embryology
    fetal circulation, 60, 62
    heart tube formation, 59
    heart tube septation, 62, 64
    radiology, 84, 87
    septal defects, 69
  radiology, 90
Atrial septal defect (ASD), 64, 69
Atrioventricular (AV) node, 83, 84
Auditory system
  anatomy, 288, 290, 348
    thalamus, 347
  auditory association cortex, 367

damage to, 304, 367, 370
primary, 304, 348, 361, 367, 369
auditory tests, 305
cochlear duct, 302, 303
hyperacusis, 303
auditory system, 304
lateral lemniscus, 296, 299, 303
middle-ear diseases, 303
spiral ganglion, 303
superior olivary nuclei, 292, 297, 303, 304
thalamus, 347
tinnitus, 255
Auditory tube, 220, 239, 220
Auerbach's plexus, 117
Autonomic nervous system (ANS)
anatomy
parasympathetic nervous system, 38
sympathetic nervouas system, 36
sympathetic nervous system, 36
inguinal canal, 98
motor innervation, 36
pre- vs. postganglionic neurons, 240, 36, 36
sympathetic nervous system, 242, 243
Axilla and radial nerve lesion, 193
Axillary artery, 196, 199
Axillary nerve
anatomy, 187, 189, 195, 196, 197, 199, 201
lesions, 191, 194, 195
Axillary nodes (breast), 42
Axillary recess (rotator cuff), 199
Axon
anatomy, 254
Axon hillock, 248
Axons
anatomy, 245, 248
disorders of myelination, 250
histology, 245, 249, 250
regeneration of neurons, 252, 254
transport functions, 248, 237
Axotomy, 254
Azygos system of veins, 71, 141

B

Babinski sign, 272, 273
Bacteria, 51, 54, 118, 120, 125, 127, 261
Bartholin glands, 161
Basal body, 23, 269
Basal cells, 55
Basal ganglia
anatomy, 329, 347, 349, 332, 356, 357
diseases of, 334, 360
histology, 332
radiology, 332
Basal nucleus of Meynert, 332, 375
Basal plate, 235
Basilar artery
anatomy, 313, 356, 358
occlusion, 315, 369
Basilar membrane, 302, 303
Basis pontis, 251, 290
Basket cells (cerebellum), 323
Basophils and hypothalamus, 351
Bell palsy, 301, 303
Berry aneurysm, 230, 360
Biceps, 192, 270
Biceps brachii tendon, 200
Bicuspid valve, 63, 79, 81
Bicuspid valve, 79
Bifid scrotum, 156
Bilateral acoustic schwannomas, 255
Bilateral renal agenesis, 44
Bile canaliculi, 131
Biliary apparatus
anatomy, 131
bile functions, 132
embryology, 102
hepatic ducts, 112, 131
Bladder
anatomy
parasympathetic nervous system, 242
pelvic viscera, 158
atonic bladder, 146, 284, 285
embryology, 239, 143, 143
histology, 16, 17
pelvic viscera, 161
spastic bladder, 284
Blastema of metanephric mass, 142, 143
Blastocyst, 8
Blink reflex, 318
Blood–brain barrier, 253, 261
Blood embryology, 239
Blood pressure, 148
Blood–testis barrier, 168
Blood–testis barrier, 165
Blood vessels
carpal tunnel, 198
embryology, 240
histology, 252, 152
Bone embryology, 239
Bone marrow, 250, 9
Bowman's capsule, 142, 149
Brachial artery, 196
Brachialis, 192
Brachial nodes, 42, 43
Brachial plexus
anatomy, 187, 215, 190
lesions of, 191, 192
ventral rami, 187, 34
Brachiocephalic artery, 72, 196
Brachiocephalic trunk radiology, 89
Brachiocephalic veins, 89
Brachioradialis, 192, 270
Bradykinesia, 334
Bradykinin, 62
Brain
anatomy, 330, 288, 329, 225
embryology, 235, 236, 237
tumors, 254, 255
Brain stem
amyotrophic lateral sclerosis
corticobulbar innervation, 300
corticospinal tract, 269
reticular formation, 320
caloric test, 307, 308
detail, 294, 319
embryology, 235, 236
horizontal conjugate gaze, 308
lateral pontine syndrome, 316, 317
medial medullary syndrome, 314, 315
medial midbrain syndrome, 318
medial pontine syndrome, 316
medulla syringomyelia, 286
pontocerebellar angle syndrome, 318
motoneurons, 267, 269, 272
motor systems neural tracts, 294
sensory systems, 274, 281
Brain stem. See also Medulla (brain); Midbrain; Pons
amyotrophic lateral sclerosis
reticular formation, 348
neuron Lewy bodies, 247
Branchial cysts, 220
Bridging veins, 227, 229, 360
Broad ligament, 160
Broca's motor speech area, 332, 359, 361, 362, 364
Bronchi
aspiration of foreign body, 49
embryology, 42, 239
histology, 51, 55
lung cancers, 51
sympathetic nervous system, 36
trachea at carina, 53, 55, 73
Bronchiolar secretory cells, 56
Bronchioles, 55
Brown-Séquard syndrome, 284, 285
Brunner glands, 119, 124
Brush cells, 54, 55
Bulb of penis, 161, 162
Bulbospongiosus muscle, 161, 172
Bulbourethral glands, 158, 161, 172
Bulbs of vestibule, 161, 163
Bulbus cordis, 60
Bullous pemphigoid, 20
Bundle of His, 83, 84

C

Cadherins, 19, 20
Calcarine sulcus, 353, 355, 344
Calcium ions in cell junctions, 20
Callosomarginal artery, 358
Calyces embryology, 142
Camper fascia, 95
Canal of Schlemm, 338
Cardiac tamponade, 75
Cardinal cervical ligament, 160
Carina, 53, 73

Carotid arteries
  aortic arch, 72
  brain stem, 312
  cavernous sinus thrombisis, 228
  cerebral cortex, 356, 358
  circle of Willis, 360
  dural venous sinuses, 227, 228
  head/neck arterial supply, 217
  mediastinum, 71
  radiology, 358
  stroke-related deficits, 369
  sympathetic nervous system, 36
Carpal bones, 194, 201
Carpal tunnel syndrome, 198, 201
Catheterization and urethra laceration, 173
Cauda equina, 265, 33
Caudal block, 27
Caudate nucleu, 332
Caudate nucleus, 44, 329, 334, 46
Caval hiatus, 84, 138
Cavernous dural venous sinus, 259, 259, 228
Cavernous sinus thrombosis, 229
Cecum, 103, 115, 142
Celiac artery, 103, 134
Celiac ganglion, 103
Central artery (retina) occlusion, 369
Central canal, 237
Central nervous system (CNS)
  anatomy, 240, 249, 36, 36
  embryology, 236, 237, 239
  gliomas, 249
  immune system link, 250
  stroke-related deficits, 369
  tumors, 255
Central pontine myelinolysis, 251
Central retinal artery occlusion, 344, 369
Central scotoma, 345
Central sulcus (of Rolando), 353, 354, 361
Centromeres in meiosis, 4, 5
Cerebellar peduncles, 296, 306
Cerebellum
  anatomy
    arterial supply, 313
    circuitry, 325, 326
    cytoarchitecture, 322
    detail, 321, 322
    flocculonodular lobe, 290, 321, 322, 323, 326, 306
  brain, 354
  embryology, 237, 321
  lesion, 238
  lesions, 325, 327, 369
  proprioception, 267
  Romberg sign, 276
  spinocerebellar tracts, 279
  thalamus, 347
Cerebral aqueduct (of Sylvius)
  brain anatomy, 257, 259, 287, 289, 299
  hypothalamus anatomy, 349
Cerebral cortex
  anatomy
    arterial supply, 356, 357, 360, 362
    basal ganglia pathways, 329, 330
    detail, 353
  cerebellum, 322, 326
  cerebrovascular disorders, 360
  cortical blindness, 365
  embryology, 237
  horizontal conjugate gaze, 311
  language, 356
  motoneurons lesions, 271
  sensory systems, 280
Cerebral infarcts, 360
Cerebral peduncles, 290, 299, 318
Cerebral veins, 227
Cerebrospinal fluid (CSF)
  anatomy, 257, 259
  arachnoid granulations, 259
  issues, 251, 352
    cranium, 259, 258, 225
    spinal cord, 33, 261
Cervical parietal pleura, 46
Cervical spinal nerves, 263, 265, 285, 296
Cervical vertebrae, 27, 28, 30, 31, 33
Cervicothoracic ganglion, 36
Cervix, 178, 179
Cervix, 160
Cholecystokinin, 119, 133
Chorda tympani, 221
Chordoma, 11
Chorea, 334, 335
Chorion, 10
Choroid, 338
Choroid plexus, 252, 259, 261,
Chromaffin cells, 235
Chronic obstructive pulmonary disease (COPD), 56
Cilia
  cystic fibrosis, 54
  dynein, 23, 54
  epithelial irritation, 55
  Kartagener syndrome, 23, 54, 269, 311, 320
  mucociliary escalatory system, 54
  stem cells, 55
Ciliary ganglion, 241, 239, 38
Ciliary muscles, 339, 240, 339, 49, 51
Cimetidine, 121
Cingulate gyrus, 288, 348, 353, 371, 372, 373
Cingulate sulcus, 353, 354
Cingulum, 374
Circle of Willis, 230, 356, 357, 358, 360
Circumferential arteries, 313
Circumflex artery, 83, 84
Circumvallate papillae, 221
Cisterna chyli, 71
Clara cells, 52, 55, 56
Clarke nucleus, 267, 279
Clavicle, 44, 195
Clearance
  of creatinine. *See* Creatinine clearance
Cleavage of zygote, 8
Cleft lip, 222
Cleft palate, 222, 223
Climbing fibers (cerebellum), 322, 324
Clitoris, 144, 155, 163
Cloacal membrane, 10, 144
Coccygeus, 157
Coccyx, 28, 33, 95
  spinal nerves, 33
Cochlea, 304
Cochlear nuclei, 293, 296, 297, 299, 303, 304
Colchicine, 19, 284, 285, 303
Collateral motor ganglia, 36, 243
Collecting ducts (kidney), 147, 149, 153
Colles' fascia, 161
Colobomas, 223
Colon
  anatomy, 107, 115
  embryology, 102
  histology, 116
Colonic aganglionosis, 111
Common annular tendon, 230
Common bile duct
  anatomy, 112, 113, 114, 115, 130, 133
  anatomy, 130
  carcinoma of pancreas, 113
  embryology, 110
Common fibular nerve, 203, 204
Common hepatic artery, 135
Complete androgen insensitivity (CAIS), 156
Conduction aphasia, 364
Cones (retina), 337
Cones (retina), 342
Confluence of sinuses, 259, 227
Conjoint tendon, 96, 99
Connexons, 21
Constipation, 117, 124
Constrictor pupillae, 339
Contraction(s)
  in muscle. *See* Muscle contraction
Conus arteriosus, 60
Conus medullaris, 265, 33, 33
Convergence of lens, 339
Cornea, 335
Corona radiata cells, 7, 167, 176
Coronary arteries, 82
Coronary sinus, 62
Coronary sulcus, 83, 84
Corpus albicans, 172

Corpus callosum
anatomy, 354, 332
arterial supply, 358
radiology, 332, 375
Corpus callosum. See also Splenium
anatomy, 288
arterial supply, 357
Dandy-Walker malformation, 238
glioblastoma multiforme, 255
lesions, 364
Corpus cavernosum, 162, 172
Corpus luteum, 10, 172, 176
Corpus spongiosum, 172
Cortex (kidney), 147, 148, 150
Corticobulbar tract
anatomy, 290, 291, 327, 332
facial paralysis, 301
Corticospinal tract
anatomy
cerebral peduncles, 299
medulla, 291, 296
midbrain, 290
neocortex, 356
pons, 290
ventral horn, 267
histology, 280, 283
internal capsule, 367
lesions, 269, 294, 314
lesions of motoneurons, 272
motoneurons, 269
Costal parietal pleura, 45, 46, 47
Costocervical artery, 217
Cranial nerves
brain stem, 314
CN I
brain stem anatomy, 287, 289
cribriform plate, 223
detail, 371
innervations, 292
CN II
arterial supply, 357
brain stem anatomy, 287
innervations, 292
multiple sclerosis demyelination, 344
optic chiasm, 342, 344
pupillary light reflex, 338, 345
retina, 342
visual system, 337
CN III
brain stem anatomy, 287
innervations, 292
midbrain origin, 287
nucleus of Edinger-Westphal, 338
orbital muscles, 292
vestibular nerve, 305
CN IV
brain stem anatomy, 287
brain stem lesions, 314
innervations, 292
midbrain origin, 287
orbital muscles, 230, 292
CN IX
brain stem anatomy, 287
dysphagia, 224
medulla, 287
CN V
brain stem anatomy, 287
foramen ovale, 222
innervations, 298
lateral medullary syndrome, 315
maxillary nerve, 228
medulla, 291, 296
nuclei, 297
pons, 287, 292
schwannomas, 255
tongue, 221
CN VI
brain stem anatomy, 287
internal strabismus, 229
lateral rectus, 230
CN VII
brain stem anatomy, 287
lesions, 303
motor nucleus, 297
parotid gland tumors, 129
pons, 287, 290, 292
pontine syndromes, 317
schwannomas, 255
solitary nucleus, 295
ventral posteromedial nucleus, 297
CN VIII
brain stem anatomy, 287
lesions, 304
pons, 287, 299
schwannomas, 254, 255, 318
vestibular system, 306, 307
CN X
brain stem anatomy, 287
dorsal motor nucleus, 295
esophageal plexuses, 71
gut innervation, 103
heart rate, 85
innervations, 300
mediastinum, 72
medulla, 287, 291
pulmonary plexus, 73
sliding hiatal hernia, 114
CN XI
foramen magnum, 225
jugular foramen, 224
spinal cord, 225
trapezius weakness, 224
CN XII
brain stem anatomy, 287
hypoglossal nucleus, 295
medulla, 287, 291, 294
occipital somites, 219
tongue, 224
embryology, 237
innervations, 292, 293
medulla
Cranial nerves, 291
paraympathetic nervous system, 38, 243
pharyngeal arches, 219
sympathetic nervous system, 36
Craniopharyngioma, 255, 344
Craniosacral outflow, 242, 38
Cranium
anatomy
dural venous sinuses, 225
sinuses, 259
venous drainage, 226
issues, 11, 230
radiology, 231
spinal dura mater, 31
Cremasteric muscle, 97, 99
Cremasteric reflex, 99, 272
Cribriform plate, 371, 372
Cricothyroid muscle, 219
Crossing over in meiosis, 4, 5
Cryptorchidism, 99, 156
Crypts of Lieberkühn, 29, 123, 126
Crypts of palatine tonsil, 220
Cumulus oophorus, 176
Cuneocerebellar tract, 279, 280
Cuneus gyrus, 358, 344, 375
Cyclic adenosine monophosphate (cAMP), 21
Cystic artery, 135
Cystic duct, 112, 133
Cystic fibrosis, 14, 55
Cytoplasm of cells, 248, 168
Cytoskeletal elements, 245, 249, 21
Cytotrophoblast, 7, 8, 9, 10

D

Dandy-Walker malformation, 238
Dantale nucleus, 289, 290
Decerebrate rigidity, 272
Deep cerebellar nuclei, 323, 324, 327
Deep femoral artery, 208
Deep fibular nerves, 206, 207
Deep inguinal ring, 97, 98
Deep lymphatic plexus, 50
Deep perineal pouch, 161
Deep tendon reflex, 270
Deep transverse perineus, 157
Deltoid, 192
Demyelination, 251, 252
Dendrites, 245, 248
Dentate gyrus, 371, 373
Dentate nucleus, 324, 326
Denticulate ligaments, 32
Depression from Parkinson's disease, 334
Dermatomes, 192
Descending aorta, 44
Descending colon
anatomy, 107

embryology, 102
radiology, 182
Desmosomes, 20, 22, 175
Detrusor muscle, 146, 157, 284
Diagonal artery, 83
Diaphragma sellae, 225
Diaphragmatic parietal pleura, 45
Diaphragmatic surface (lung), 48
Diaphragm (thoracic)
anatomy, 157
apertures
aortic hiatus, 134
caval hiatus, 138
esophageal hiatus, 87, 114
congenital diaphragmatic hernia, 44, 87
pain referral, 87
radiology, 88, 182
thoracic outlet, 44
Diencephalon, 237, 329, 347, 356
Digastric muscle, 219
DiGeorge sequence, 220, 223
Dihydrotestosterone (DHT), 3, 155, 168
Dilator pupillae, 338
Diploic vein, 227
Diplopia, 308
Direct hernias vs. indirect, 101
Disjunction in meiosis, 4, 100
Dislocations, 194, 199, 207
Distal convoluted tubule, 148, 150, 153
Diuretics, 153
DNES cells (Diffuse Neuro Endocrine System), 54
Dopamine, 331, 349
Dorsal column–medial lemniscal system
anatomy, 275, 277
lesions, 276
Dorsal column nuclei, 289, 295
Dorsal columns
anatomy, 275
spinal cord section identification, 282
subacute combined degeneration, 286
tabes dorsalis, 286
Dorsal embryonic mesentery, 103, 104
Dorsal funiculus, 275
Dorsal horn
anatomy, 266
histology, 281
rexed laminae
anterolateral system, 277
spinal cord anatomy, 263, 265
spinocerebellar tracts, 280
sensory neurons
spinal cord anatomy, 263
Dorsalis pedis artery pulse point, 208
Dorsal midbrain syndrome, 318
Dorsal motor nucleus, 291, 292
Dorsal rami, 34
Dorsal root ganglia. See also Sensory ganglia
spinal cord anatomy, 34
Dorsal root (spinal nerves)
dorsal horn, 266
reflexes, 271
sensory systems
anterolateral system, 279
dorsal column–medial lemniscal system, 275
general sensory pathways, 275
spinal cord anatomy, 263, 265, 34
Dorsal scapular nerve, 190
Dorsal spinocerebellar tract, 279, 284
Dorsomedial nucleus, 347, 349, 351, 348, 373, 374
Down syndrome, 239, 248, 372
Drawer signs, 212
Driving force. *See* Net force
Ductuli efferentes, 169
Ductus arteriosus, 61, 62, 219
Ductus deferens
anatomy, 158
embryology, 142
histology, 164, 171
Ductus epididymidis embryology, 142
Ductus venosus, 61
Duodenal atresia, 111
Duodenitis, 124
Duodenum
anatomy, 107, 112, 114, 123
embryology, 102, 103
histology, 119
issues, 124
Dural venous sinuses, 33, 226
Dura mater
cranium, 255
embryology, 239
spinal cord, 238, 31, 236, 33
Dynein, 249, 19, 23, 23
Dyskinesias, 335
Dysmetria, 325, 327
Dysosmia, 223
Dysphagia, 293, 315
Dystonia, 335

E

Ear
anatomy, 302
embryology, 239, 220
issues, 220, 223, 307
vestibular system, 305
Ectopic parathyroid, 223
Ectopic pregnancy, 10, 178
Ectopic thymus, 223
Edinger-Westphal nucleus, 289, 299
Ejaculatory duct
5α-reductase 2 deficiency, 156
embryology, 155
histology, 170
Elastic fibers, 52, 55, 58
Elbow
innervation, 188
issues, 192, 193, 194
radiology, 189
reflex, 270
Elderly, 168, 229
Electrolytes, 127, 148
Electromyography, 272
Embolic infarcts, 360
Emboliform nucleus, 325
Embryo, 8
Embryonic mesentery, 103
Emissary veins, 259, 227, 228
Emphysema, 56
Endocardial cushions, 12, 63, 64, 239
Endocardium, 80
Endocrine system, 54, 119, 122, 155, 176
Endocrine system, 125
Endocytose, 119
Endolymph, 302
Endometrium, 9, 173, 178
Endoplasmic reticulum (ER), 248
Enema barium radiology, 181
Enterocytes, 15, 124, 125
Enteroendocrine (EE) cells, 119, 122, 133
Entorhinal cortex, 371, 372, 373
Eosin stain, 14
Ependymal cells, 261, 252, 255
Ependymoma, 255
Epiblast, 9, 10, 11
Epicardium, 75, 80
Epidermis embryology, 239, 12
Epididymis
histology, 164, 170
Epidural hematoma, 217, 229, 360
Epidural space
epidural hematoma, 217
spinal meninges, 31
Epiploic foramen (of Winslow), 107, 108
Epispadias, 156
Epithalamus, 347, 349
Erb-Duchenne palsy, 191
Erection of penis, 172
Erector spinae, 263
Erythrocytes, 152
Esophageal branch, 135
Esophageal hiatal hernia, 87
Esophageal veins, 140
Esophagogastric sphincter, 87
Esophagus
anatomy, 44, 114, 117, 120, 135, 295
anatomy, 141
embryology, 42, 102
histology, 119
Estradiol, 176
Estrogens, 352
Eustachian tube, 302

Excitability
neuronal. *See* Neuronal excitability/conduction
Expressive aphasia, 362
Exstrophy of bladder, 156
Extensor digitorum innervation, 204
Extensor hallucis innervation, 204
External abdominal oblique muscle, 95, 99
External anal sphincter, 116, 127
External auditory meatus, 220, 302
External ear, 302
External hemorrhoids, 116
External iliac artery, 208
External spermatic fascia, 95
External urethral sphincter, 146, 157, 160
Extraembryonic mesoderm, 9
Extrafusal fibers, 266, 270
Extrahepatic biliary atresia, 110
Extraperitoneal connective tissue, 97
Extrastriate cortex, 365
Eye
achromatopsia, 366
anatomy, 357
embryology, 239
frontal eye field, 361
innervation, 305
internuclear ophthalmoplegia, 251, 294, 309, 310, 312
Kayser-Fleischer ring, 334, 335
movement control, 308
night blindness, 337
nystagmus, 306, 307, 308
open-angle glaucoma, 338
pupillary abnormalities
lens, 339
pupillary light reflex, 338
scotoma, 344, 345, 365
strabismus, 316, 318
vestibulo-ocular reflex, 305
Eyelid, 230
Eyelid, 301

F

Facial artery, 217
Facial colliculus, 290
Falciform ligament, 103, 109, 111
Falx cerebri
anatomy, 225, 227
dural venous sinuses, 259
Falx inguinalis, 96, 99
Fasciculations, 272, 273
Fasciculi, 263
Fastigial nucleus, 326
Fat, 95, 97
Feeding center, 349, 352
Female pseudointersexuality, 155
Femoral artery, 97, 102, 208
Femoral canal, 102
Femoral hernias, 102
Femoral nerve, 203, 206, 102
Femoral sheath, 97, 102
Femoral triangle, 209
Femoral vein, 97, 102
Fertilization, 6, 176
Fetus
congenital adrenal hyperplasia, 155
hematopoiesis, 9
lung surfactant, 42, 58
Fibrillations, 272
Fibroblasts, 19, 126, 153, 168
Fibrocytes, 19
Fibronectin, 20, 21
Fibula, 206, 211
Fibula, 213
Fibular artery, 208
Fibular collateral ligament, 211
Fibularis brevis innervation, 204
Fibularis longus innervation, 204
Fibularis tertius innervation, 204
Filaments, 19, 20
Filtration
renal. *See also* Glomerular filtration
Filum terminale, 265, 33, 33
Fimbria, 173
Fimbriae, 177
Finger agnosia, 364
First arch syndrome, 223, 239
First jejunal artery, 135
Fissures (lungs), 48
5α-reductase deficiency, 156
Flaccid paralysis, 272, 273, 284, 285, 286
Flaccid weakness, 269
Flagella, 19, 23, 167
Flexor digitorum longus innervation, 204
Flexor digitorum profundus, 198
Flexor digitorum superficialis, 198
Flexor hallucis longus innervation, 204
Flexor pollicis longus, 198
Flocculonodular lobe, 321, 322, 326, 306
Fluid balance, 121, 127, 147
Folia (cerebellum), 321
Follicles (ovaries), 155
Foot
arterial supply, 208
foot drop, 207
"glove and stocking" sensation, 237
innervation, 203, 205, 207
Foramen cecum, 221
Foramen lacerum, 224
Foramen magnum, 238, 32, 33
Foramen of Luschka, 258, 261
Foramen of Magendie, 258
Foramen ovale (FO), 62, 64
Foramen primum, 63
Foramen secundum, 63
Force. *See also* Net force
Forebrain adult derivatives, 237
Foregut
anatomy
arterial supply, 134
parasympathetic nervous system, 241, 242, 38, 295
sympathetic nervous system, 36, 243
embryology, 102
Fornix, 288, 354, 373, 332
Fossa ovalis, 62, 64
Free radicals and phagocytosis, 250
"Fried egg" appearance, 255
Frontal eye field, 362
Frontal lobe
anatomy
arterial supply, 357, 358
corticospinal tract, 269
detail, 353, 361, 370
motor homunculus, 355
primary motor cortex, 269
Frontal lobe
arterial supply, 358
frontal lobe syndrome, 362
horizontal conjugate gaze, 311
lesions, 370
Fundus (gallbladder), 93, 133
Fundus (stomach), 114, 119, 121
Fundus (uterus), 178

G

GABA (γ-aminobutyric acid), 299, 331, 323
Gag reflex, 315
Galactorrhea from arcuate nuclei lesions, 350
Galea aponeurotica, 259
Gallbladder
anatomy, 107, 112
embryology, 102, 109
histology, 133
histology, 133
GALT (gut-associated lymphoid tissue), 117, 118, 124, 126
Gametes, 4
Gamma motoneurons, 266, 270, 271
Gap junctions, 20, 21, 80, 118, 175
Gas exchange, 43, 51, 54, 57, 58
Gastric pits, 121
Gastric veins, 140
Gastrin, 119
Gastrocnemius, 204, 270
Gastroduodenal artery, 135
Gastrointestinal (GI) tract
anatomy, 295
bowel ischemia, 138
colonic aganglionosis
endoderm, 239, 12, 239
embryology
congenital abnormalities, 110
foregut, 103
midgut, 106
primitive gut tube, 102, 103

enteroendocrine (EE) cells, 119
Helicobacter pylori, 122
immune functions, 118
Gastrosplenic ligament, 103, 110
Gate under Parkinson's disease, 334
Gaze
cerebellar hemisphere lesions, 327
gaze palsy, 369
horizontal, 362
parallel, 292, 293
paralysis, 318, 320
superior colliculi, 299, 342
Genital ducts histology, 169
Genitalia (external), 3, 156, 160, 162
Genitalia (external), 162
Genitofemoral nerve, 99
Genu, 330, 332, 357, 367
Germ layer derivatives, 239
Gerstmann syndrome, 363, 364, 369
Gestational trophoblastic disease, 10
Glaucoma, 338
Glenohumeral joint, 199
Glial cells, 249
Glioblastoma multiforme, 255
Gliomas, 249
Globus pallidus, 329, 332, 348, 369
Glomeruli (cerebellum), 323
Glomeruli (kidney)
anatomy, 147, 148
histology, 13, 151, 154
mesangial cell abnormalities, 153
"Glove and stocking" sensation, 237
Glucose across blood–brain barrier, 253
Glutamate, 322, 323
Gluteus maximus innervation, 205
Gluteus medius innervation, 205
Gluteus minimus innervation, 205
Glycocalyx, 22
Goblet cells
gallbladder, 133
GI tract, 19, 119, 122, 125, 127
irritation of, 55
respiratory, 18, 51, 54, 56
Golgi apparatus, 248
Golgi cells, 323, 325
Golgi tendon organs (GTOs), 279
Gonadal arteries, 138
Gonadal veins, 138
Gonads
indifferent, 3, 155
mesoderm, 239, 12, 239
urogenital ridge, 97
Gonotrophic hormones, 349
Graafian follicle, 176
Gracilis innervation, 204
Granule cell layer (cerebellum), 322
Granule cells, 322, 325
Granulosa cells (follicle), 175, 177
Gray matter
periaqueductal gray matter, 290
spinal cord, 265, 34
sympathetic nervous system, 36
Gray ramus communicans, 38
Greater omentum, 103
Greater sac (peritoneal cavity), 107, 108
Greater vestibular glands, 161
Guillain-Barré syndrome, 251
Gyri of cerebral cortex, 353

H

Habenular nuclei, 349
Hair cells, 302
Hand
arterial supply, 196
"glove and stocking" sensation, 237
innervation, 190, 198
Klumpke's paralysis, 192
lesions of brachial plexus, 192, 193
syringomyelia, 286
Head
anatomy
arterial supply, 217
parasympathetic nervous system, 38
sympathetic nervous system, 36
embryology
pharyngeal apparatus, 218, 219, 220
facial expression muscles, 219
hydrocephalus, 238
parasympathetic nervous system, 242
Heart
anatomy
arterial supply, 82, 83
cardiac impression in lungs, 48
conducting system, 84
contraction, 80, 81
internal features, 78
venous drainage, 84
auscultation, 81, 82
embryology
septal defects, 65
myocardial infarction, 83
pericardium, 45, 75
pericardium, 70, 74
sympathetic nervous system, 36
valves
atrioventricular embryology, 63
murmurs of heart, 81
pulmonary semilunar valve, 78
regurgitation, 81
stenosis, 81, 82
tricuspid valve, 78, 81, 82
valvular insufficiency, 81
Hematomas, 217, 226, 229
Hematopoiesis, 9
Hematoxylin-and-eosin (H&E) staining, 14
Hemianopia, 345, 360
Hemiballism, 334, 349
Hemidesmosomes, 20
Hemiparesis from epidural hematoma, 229
Hemispheres of cerebral cortex, 237, 238, 356
Hemorrhoids, 116
Hepatic arteries, 112, 130, 135
Hepatic flexure radiology, 181
Hepatic portal system, 139
Hepatic portal vein, 108, 113, 139
Hepatic sinusoids, 130
Hepatic veins, 112, 139
Hepatocytes, 130, 131
Hepatoduodenal ligament, 108, 112
Hepatogastric ligament, 108, 111
Hepatopancreatic ampulla (of Vater), 113, 115, 130, 133
Herpes and retrograde axonal transport, 249
Heschl's gyrus, 304
Hindbrain adult derivatives, 237
Hindgut
anatomy
parasympathetic nervous system, 38
colonic aganglionosis, 111
embryology
derivatives of, 103
kidneys, 142, 143
primitive gut tube, 102
urorectal septum, 143
terminal rectum, 115
Hip
anatomy, 210
innervation, 203
Hippocampal formation, 354, 371, 373
Hippocampus
Alzheimer disease, 375
entorhinal cortex, 373
hippocampal formation, 371, 373
lesions, 374
limbic system, 373
mammillary bodies, 348
Papez circuit, 372, 373
rabies Negri bodies, 247
thiamine deficiency, 348
Hirschsprung disease, 111, 117, 241
Histamine, 121
HIV-1 virus microglia cells, 250
Hoarseness, 295, 315
Holoproscencephaly, 238
Homeostasis
hypothalamus, 349
kidneys, 148
Homologous chromosomes, 4
Homonymous hemianopia, 345, 360, 365, 366
Hook of hamate, 194
Horizontal conjugate gaze, 311
Horner syndrome
brain stem lesions, 320
hypothalamic axon lesion, 314

ipsilateral symptoms, 37, 242
spinal cord section, 281
Human chorionic gonadotropin (hCG), 10
Humerus
axillary nerve lesion, 194
mid-shaft, 193, 200
radiology, 189
axillary nerve, 200
posterior humeral circumflex artery, 196, 200
radiology, 189
Hunger, 118
Huntington disease, 334, 335
Hyaline cartilage, 53
Hydatidiform moles, 10
Hydrocele, 156
Hydrocephaly, 238, 260, 255
Hydrochloric acid (HCl), 119
Hyoid bone embryology, 219
Hyperextension of vertebral whiplash, 30
Hyperflexia of motoneuron lesions, 273
Hyperphagia, 349
Hypersexuality, 374
Hyperthermia, 349, 352
Hypertrophic pyloric stenosis, 110
Hypocalcemia, 220
Hypochondrium, 94
Hypoglossal nucleus, 314
Hypophyseal-portal veins, 351
Hypophysis, 349
Hyposmia, 372
Hypospadias, 156
Hypotension infarcts, 360
Hypothalamic fibers
anatomy
brain stem, 290, 291
medulla, 294
midbrain, 299
pons, 296
spinothalamic fibers, 294
Horner syndrome, 294, 314, 315, 316
Hypothalamus
anatomy
brain, 287
histology of basal ganglia, 332
hypothalamic axons, 290
brain, 354
circadian rhythms, 343, 349
detail, 349
embryology, 237
homeostasis, 349, 352
Hypothalamus anatomy
optic tract fibers, 342
lesions, 349
limbic system, 371
Papez circuit, 372
pituitary gland, 350, 351
radiology, 375
sympathetic nervous system, 36
Hypotonia from cerebellar lesions, 325, 327

I

IgA, 117, 181
IgG, 251, 124
Ileal diverticulum, 111
Ileocolic artery, 136
Ileum
anatomy, 107, 115, 123, 136, 137
embryology, 102
histology, 119, 124
Iliac crest, 35, 146
Ilioinguinal nerve, 98
Implantation, 8
Impotence, 349
Incus, 219
Indifferent stage of gonads, 3, 155
Infants, 58, 66, 241
Inferior cerebellar peduncle (ICP), 293, 295, 315
Inferior colliculi
anatomy, 288, 290, 296, 348
Inferior epigastric vessels, 72, 97, 98, 101
Inferior frontal gyrus, 353
Inferior gemellus innervation, 205
Inferior glenohumeral ligament, 199
Inferior gluteal nerve, 203, 205, 206
Inferior lingual gyrus, 353
Inferior mesenteric artery, 103
Inferior mesenteric artery, 134, 137
Inferior mesenteric ganglion, 103
Inferior mesenteric vein, 139, 141
Inferior oblique, 230
Inferior olivary nucleus, 293, 324, 295
Inferior pancreaticoduodenal arteries, 113, 136
Inferior parathyroid gland embryology, 220
Inferior parietal lobule, 353
Inferior petrosal dural venous sinus, 259, 228
Inferior quadrantanopia, 344
Inferior rectal veins, 141
Inferior sagittal dural venous sinus, 259, 227
Inferior sagittal sinus, 259
Inferior temporal gyrus, 353, 357
Inferior thyroid artery, 217
Inferior vena cava
anatomy
abdominal viscera, 107, 138
abdominal wall, 145
liver, 111, 112
Infraspinatus muscle, 190, 196, 199
Infundibulum (uterus), 176, 177
Inguinal canal, 98, 156
Inguinal hernias, 98, 100, 101, 102
Inguinal ligament, 94, 95, 96, 102
Inguinal region, 95, 98, 100
Inguinal triangle, 100, 101
Inhibin, 168
Inhibitory factors, 351
Initial segment of axon, 248
Inner ear
anatomy, 302, 303
embryology, 239
stroke-related deficits, 369
Integrins, 20, 21
Intention tremor, 325, 327
Interatrial septum, 85
Intercalated ducts, 130, 153
Intercerebral hemorrhage, 360
Intercostal arteries, 44, 70
Intercostal nerves, 46
Intercostal spaces, 44, 77
Interlaminar space, 35
Intermediate filaments, 19, 20, 277, 284, 301, 303, 304, 306, 307
Intermediate hemisphere (cerebellum), 321, 326
Internal abdominal oblique muscle, 96
Internal anal sphincter, 115, 127
Internal arcuate fibers, 293, 294
Internal capsule
anatomy, 348, 372
arterial supply, 357, 367
lesions, 369
radiology, 332
Internal hemorrhoids, 116, 141
Internal jugular veins
dural venous sinuses, 259
lymphatic system, 49
Internal pudendal artery, 160, 163
Internal spermatic fascia, 97
Internal urethral sphincter, 146, 157
Internuclear ophthalmoplegia, 251, 310, 312
Interpectoral nodes, 42
Interposed nuclei, 324, 327
Interthalamic adhesion, 354
Intertubercular plane, 93
Interventricular foramen, 258, 64, 258
Interventricular septum, 63, 83, 84
Interventricular sulci, 76
Intervertebral disks, 27, 29, 30, 31
Intervertebral foramina, 29, 31
Intestinal arteries, 136
Intrafusal muscle fibers, 266, 270, 271
Intralaminar nuclei, 348
Intraperitoneal organs, 107
Intrinsic factor, 119, 121
Ion channels, 248, 253
Iris, 339
Ischemia, 85
Ischial spine, 95
Ischial tuberosity, 158
Ischiocavernosus muscle, 161, 172
Islets of Langerhans, 129

J

Jaundice, 113
Jaw jerk reflex, 298
Jejunal artery, 136
Jejunum
  anatomy, 107, 115
  embryology, 102
  histology, 124
Jugular foramen, 259, 226, 228
Juxtoglomerular complex, 154

K

Kartagener syndrome, 23, 178, 269, 311, 320
Karyotypes of hydatidiform moles, 11
Kayser-Fleischer ring, 334
Keratins, 19
Kidney. *See also* Renal entries
  flow distribution in. *See* Filtration fraction (FF)
  functions of, 6
Kidneys
  adult polycystic kidney disease, 360
  anatomy
    as retroperitoneal, 107
    Bowman's capsule, 149
    detail, 147, 148
    extraperitoneal connective tissue, 97
    pancreas, 113
    peritoneum, 106
    renal pelves, 145
  arterial supply, 143, 148
  embryology, 239
  endocrine gland, 147
  histology
    nephrons, 153
    renal corpuscle, 150
    simple cuboidal epithelium, 14, 17, 154
    simple squamous epithelium, 16
Kinesin, 248, 19
K (Kulchitsky) cells, 54
Klüver-Bucy syndrome, 374
Knee
  anatomy, 208, 211, 212, 213
  injuries, 206, 212, 213
  innervation, 203
Korsakoff syndrome, 374
Kupffer cells, 130

L

Labia majora embryology, 155
Labia minora, 155, 163
Labyrinthine artery, 313, 369
Lacrimal gland, 38
Lacteals, 117
Lactiferous duct, 43
Lactiferous sinus, 42
Lacunar infarcts, 360
Lacunar ligament, 95
Lacuna spaces, 10
Laminae (vertebrae), 29
Lamina terminalis, 354
Laminin, 20, 21
Language
  agraphia, 369
  alexia, 369
  aphasia, 357, 369, 375
  Broca's motor speech area, 332, 359, 364
  dominant hemisphere, 356
  Wernicke's area, 304, 360, 361, 363
Large intestine
  anatomy, 115, 137, 138
  embryology, 102
  histology, 119, 126, 127
Larynx
  embryology, 239, 218
Lateral cervical cysts, 220
Lateral circumflex femoral artery, 208, 211
Lateral epicondyle radiology, 198
Lateral femoral cutaneous innervations, 205
Lateral fissure (of Sylvius), 353
Lateral funiculus, 266, 277
Lateral geniculate body
  anatomy, 347, 348, 365, 366
  visual pathways, 345
Lateral horns
  spinal nerve ventral root, 34
  sympathetic nervous system, 36
Lateral hypothalamic nucleus, 349
Lateral menisci, 212
Lateral plantar artery, 208
Lateral pterygoid, 219, 297
Lateral rectus, 305, 309
Lateral sulcus (of Sylvius), 353, 361
Lateral thoracic artery, 196
Lateral ventricle, 257, 258
Lateral vestibulospinal tract, 305
Latissimus dorsi muscle, 41, 190, 192
Left anterior descending (LAD) artery, 83
Left colic artery, 137
Left gastric artery, 134, 135
Left gastric vein, 141
Left gastroepiploic artery, 135
Left hypochondrium, 94
Left renal vein, 139
Left suprarenal vein, 139
Lens of eye, 239, 339, 339, 12
lesser omentum, 107
Lesser omentum
  anatomy, 111
  embryology, 103, 109
Lesser sac (peritoneal cavity), 107, 109
Leukocytes, 20, 261
Leukodystrophies, 250
Levator ani, 157
Levator ani, 161
Lewy bodies, 247, 334
Leydig cells, 3, 168
Ligamentum arteriosum, 62, 66, 76
Ligamentum flava, 35
Ligamentum teres, 62, 108, 112
Ligamentum venosum, 62, 112
Light reflex, 345
Limbic system, 371
  anatomy, 348, 352
  Papez circuit, 372, 373
Limbs
  sympathetic nervous system, 36
Line of Gennari, 356, 365
Lingual artery, 217
Lingual branch of mandibular nerve, 221
Lingual gyrus, 344, 375
Lingula (lung), 47
Lipase from stomach, 121
Lipase precursor, 119
Lips, 222
Lissauer's tract, 279
Lithiasis, 133
Liver
  anatomy
    arterial supply, 112, 132, 135
    hepatic lobules, 131
    portalcaval anastomoses, 133
    portal triad, 112
    portal triad, 131
    venous drainage, 112, 130
  central pontine myelinolysis, 251
  cirrhotic diseases, 19, 133
  detail, 107, 111
  detoxification
    endoderm, 239, 12, 239
    fetal hematopoiesis, 9
  embryology
    endoderm, 109
    foregut derivative, 103, 109
  histology, 130, 132
  Wilson disease, 334, 335
"Locked in" syndrome, 251
Locus caeruleus, 320
Locus coeruleus, 372
Long pectoral nerve, 190
Long thoracic nerve, 41, 190, 194
Loop of Henle, 153
Loss of consciousness from epidural hematoma, 229, 360
Lower limb
  anatomy
    lumbosacral plexus, 203, 204, 205
    lumbosacral plexus lesions, 203
    sensory innervation, 207
    sympathetic nervous system, 36, 38, 243
  embryology of limb bud, 218
  lumbosacral plexus, 263

Lower subscapular nerve, 190
Lumbar puncture, 35
Lumbar region of abdomen, 94
Lumbar spinal nerve lumbar enlargement, 263, 265
Lumbar splanchnic nerves
  innervation, 103, 116, 146, 158
  sympathetic nervous system, 36, 103
  white rami, 38
Lumbar vertebrae
  abdominopelvic cavity, 96
  anatomy, 25, 41, 93
  herniated disk, 30
  lumbar puncture, 35
  spinal cord termination, 33
  spinal nerves, 33
Lumbosacral plexus
  anatomy, 203, 263
  lesions, 206
  lumbar enlargement, 263, 265
  muscles innervated, 204, 263
  ventral rami forming, 34
Lunate, 198, 201
Lung cancer, 50
Lungs
  anatomy, 46, 48, 55, 56
    lymphatic drainage, 50
    pleura, 45, 46, 47, 51
    thoracic cavity, 44
    trachea, 53, 54
  diseases, 54, 56
    endoderm, 239
  embryology
    endoderm, 42, 42, 12
    gastrointestinal embryology, 102
    malformations, 43
  pneumothorax, 46
  surfactants, 43, 56, 57
  sympathetic nervous system, 36
Lutein cells, 177
Lymphatic system
  anatomy
    abdominal wall, 98
    lamina propria of GI mucosa, 117
    mammary gland, 41
    Peyer's patches, 119, 124
    testes, 99, 168
  embryology of lymph, 239
  mammary gland
    mammary gland, 41
  metastasis of cancer, 50, 99
  thoracic duct, 49, 70
Lymphocytes, 117, 124, 180, 261
Lysosomes, 249, 251
Lysozyme, 119, 125

M

Macrophages, 58, 59
Macula densa, 154
Macula (retina), 338, 360, 365
Macula (retina), 344
Macula (vestibular system), 305
Magnocellular system, 349, 366
Main pancreatic duct of Wirsung, 113, 115
Major duodenal papilla, 113
Male pelvic viscera, 3, 155
Male pseudointersexuality, 155
Malignant trophoblastic disease, 11
Malleus, 219
Malnourishment and central pontine myelinolysis, 251
Malrotation of the midgut, 111
Mammary glands, 41, 180, 349
Mammillary bodies
  anatomy, 354, 371
  issues, 374
Mammillothalamic tract, 374, 352
Mandible, 219
Mandibular nerve, 219, 221, 223, 292
Manubrium, 44
Marfan syndrome, 360
Marginal artery, 84, 137
Masseter, 219, 297
Mastectomy and long thoracic nerve, 41, 194
Mastication, 219, 298, 300
Maxilla, 217, 219, 222
Maxillary artery, 217
Maxillary nerve, 292
M cells (intestines), 126
Meckel diverticulum, 111
Medial antebrachial cutaneous nerve, 190
Medial brachial cutaneous nerve, 190
Medial circumflex femoral artery and avascular necrosis, 208, 209
Medial epicondyle radiology, 200
Medial geniculate body, 289, 304, 347, 348
Medial lemniscus
  anatomy, 294, 296, 299, 314, 348
  sensory system, 275
Medial lemniscus. See also Dorsal column–medial lemniscal system
  lesions, 316
Medial longitudinal fasciculus
  anatomy, 290, 291
  gaze, 309
  lesions, 309
Medial menisci, 211, 213
Medial nuclear group, 348
Medial pectoral nerve, 190
Medial plantar artery, 208
Medial plantar nerve, 207
Medial pterygoid, 219, 297
Medial rectus, 339, 230, 305, 309
Medial umbilical ligament, 62
Median nerve
  brachial plexus, 187
  innervation, 188
  lesions, 195
  radiology, 189
Mediastinal parietal pleura, 46, 47
Mediastinal surface (lung), 48
Mediodorsal nucleus, 347
Medulla (brain
  spinal cord, 263
Medulla (brain)
  anatomy
    arterial supply, 312
    brain, 288
    cranial nerves, 288
    detail, 287, 291
  arterial supply, 358
  cerebral cortex, 353
  embryology, 237
  issues, 286, 313, 369
  radiology, 375
  vestibular nuclei, 305
Medulla (kidney), 147, 148, 153
Medulloblastoma, 255
Meiosis, 4, 6, 7, 19
  oocyte metaphase arrest, 7
  oocyte metaphase arrest, 176
Meissner's plexus, 117
Melanin in substantia nigra, 299
Melanocyte embryology, 239
Melatonin from pineal gland, 349
Melena from Helicobacter pylori, 122
Membranous urethra, 146, 173
Meningeal dura mater, 226, 229
Meningeal veins, 227
Meningioma, 255, 345
Meningitis, 261
Meningomyelocele, 238
Mesangial cells, 154
Mesencephalic nuclei, 299
Mesencephalon, 237
Mesonephric ducts, 3, 155
Mesonephros, 144
Mesothelioma, 51
Mesothelium, 80, 117, 133
Metabolic activity of hepatocytes, 132
Metachromatic leukodystrophy (MLD), 251
Metanephric mass, 142
Metanephros, 142
Metencephalon, 237, 321
Meyer's loop, 343, 345, 357
Microfilaments, 19
Microglia cells, 250
Micrognathia, 220
Microphallus, 156
Microtubules
  axon transport functions, 248
  cell structure, 19, 23
  neurons, 247, 248
  sperm flagellum, 167
  sperm flagellum, 167

Microvilli
  actin filaments, 19, 20
  cell surfaces, 20, 23
  epididymis, 170
  hepatocytes, 131
  oocytes, 175
  proximal convoluted tubules, 153
  small intestine, 119
Midbrain
  adult derivatives, 237
    cranial nerves, 287
    substantia nigra, 329
  anatomy
    arterial supply, 313, 357
    brain, 287
    brain stem, 287
    cranial nerve nuclei, 297, 299
    detail, 287, 290
  embryology, 237
  radiology, 375
  stroke-related deficits, 369
Middle cerebellar peduncle (MCP), 322
Middle cerebral artery
  anatomy, 357, 358, 367
  occlusion, 357, 360, 369
  radiology, 358
Middle colic artery, 136
Middle ear, 220, 302
Middle frontal gyrus, 353
Middle mediastinum, 74
Middle meningeal artery, 217, 225, 229, 360
Middle scalene, 215
Middle subscapular nerve, 190
Middle temporal gyrus, 353
Midgut
  anatomy
    duodenum, 114
    parasympathetic nervous system, 242, 38
    sympathetic nervous system, 242, 36
  embryology, 102
Midline nucleus, 347
Miosis
  anatomy, 339
  Horner syndrome, 37, 242
  Horner syndrome, 286
  pupillary light reflex, 338
Mitosis, 9, 19
  mitotic rates, 14, 57, 122
Mitotic spindle, 19
Mitral insufficiency, 82
Mitral valve, 81, 82
Molecular layer (cerebellum), 322
Monocytes, 250, 59, 130, 130, 261
Mononuclear phagocyte system, 130
Morula, 8
Mossy fibers (cerebellum), 322, 324
Motoneurons
  cerebellum, 327
  corticobulbar tract, 300
  facial motor nucleus, 301
  lesions, 271, 272, 273
  nucleus ambiguus, 295
  poliomyelitis, 285
  reflexes, 270
Motor cortex
  basal ganglia, 329
  corticobulbar fibers, 300
  lesions, 362
  motor homunculus, 355
  premotor cortex, 361, 363
  primary
    cerebellum, 324
    cerebral cortex, 362
    frontal lobe, 361
    stroke-related deficits, 369
  thalamus, 347
  transcortical apraxia, 357
Motor end plates, 270
Motor homunculus, 355
Motor units and alpha motoneurons, 270
Müllerian ducts, 3, 144, 155
Müllerian-inhibiting factor (MIF), 3, 155
Multiple sclerosis (MS), 251, 339, 293, 310
Muscle
  anatomy
    actin microfilaments, 19
    motor units, 270
    muscle spindle, 266, 270
    muscle tone, 270, 272
    sympathetic nervous system, 36
  anterior body wall, 94, 98
  embryology, 42, 239
  fasciculations, 273
  histology
    blood vessel smooth, 17
    cardiac heart wall, 79
  stretch reflex, 268, 270
  sympathetic nervous system, 243
Muscle(s)
  nonstriated. *See* Smooth muscle
  striated. *See* Cardiac muscle; Skeletal muscle
Muscle twitch. *See* Muscle contraction
Muscularis externa, 117, 119, 120
Muscularis mucosa, 53, 117, 123
Musculocutaneous nerve, 189, 192, 194
Mydriasis, 318
Myelencephalon, 237
Myelin
  central nervous system, 239, 251, 337
  disorders of, 250
  embryology, 239
  histology, 245, 250
  Schwann cells, 250, 239, 254
Mylohyoid, 219
Myoepithelial cells, 128, 130
Myometrium histology, 173
Myosin, 19, 152
Myotatic reflex, 270

N

Nail embryology, 239, 12
Nasal cavity
  anatomy, 297
  CSF leak, 372
  nasal mucosa, 371
Nausea, 229, 315, 317
Neck, 215
Necrosis, 201, 255
Negri bodies, 237, 241, 247, 248
Neocortex, 347, 354, 375
Nephric tubules embryology, 142
Nephrons
  anatomy, 150, 154
  histology, 149
Nephrotomes, 142
Neural crest cells, 239, 11, 12
Neural tube
  central nervous system, 235, 237
  derivatives of, 239
  ectoderm, 239, 12, 239
  PNS axons, 235
Neuroectoderm
  derivatives of, 239
  embryology, 239
  preganglionic neurons, 36
Neuroendocrine cells, 54, 55
Neurofibrillary tangles, 248, 372
Neurofibromatosis, 254, 255
Neurohypophysis, 239, 12
Neuromuscular junctions, 266
Neurons
  anatomy, 245, 247
  CNS vs. PNS, 241
  cytoplasmic inclusions, 247
  embryology, 235
  free radicals and calcium, 250
  histology, 245
  magnocellular neurons, 349
  neurofibrillary tangles, 248
  pre- vs. postganglionic, 36, 240
  pseudounipolar cell bodies, 34
  synapses, 249
Neuropathies, 237
Neuropore abnormalities, 238
Neurosyphilis, 339, 286
Neurotransmitters
  acetylcholine as, 331
  astrocytes removing, 249
  dopamine as, 331
  fast anterograde axonal transport, 248
  GABA as, 330, 330, 323
  glutamate as, 322, 323
  retina membrane potential, 337
Nissl substance, 245, 248, 253

Node of Ranvier, 245, 250
Node of RanvierAxotomy, 253
Noncommunicating hydrocephalus, 319, 320
Norepinephrine, 320
Notochord, 11
Nucleus ambiguus, 289, 315
Nucleus basalis of Meynert, 372
Nucleus cuneatus, 289, 294, 275
Nucleus gracilis, 289, 284
Nucleus of cell
H&E staining, 14
neurons, 245, 247
nuclear envelope lamins, 19
Nucleus of Edinger-Westphal, 289, 338, 299
Nucleus pulposus, 29, 30, 31
Nystagmus
cerebellar hemisphere lesions, 325
CN VIII, 293
medial longitudinal fasciculus lesion, 310
vestibular nystagmus, 308, 315
vestibulo-ocular reflex, 308

O

Oblique pericardial sinus, 75
Obturator artery, 208
Obturator internus muscle, 205
Obturator internus muscle, 161
Obturator nerve, 203, 204, 206
Occipital artery, 217
Occipital cortex lesion, 366, 370
Occipital lobe
anatomy, 353, 365, 370
arterial supply, 357
lesions, 366, 370
stroke-related deficits, 369
visual association cortex, 365
visual cortex, 347, 365
Occipital sinuses, 259, 228
Ocular muscles
embryology, 218
horizontal conjugate gaze, 310
orbital muscles, 339, 292
Ocular palsy, 374
Oculomotor nuclei, 299, 308
Odontoblast embryology, 12, 239
Olfactory bulb, 371, 372
Olfactory cortex, 354
Olfactory system, 49, 371, 373
Olfactory tract, 372, 290
Oligodendrocytes, 239, 250, 251, 12
Oligodendroglioma, 255
Oligohydramnios, 44
Olives, 295
Olivocerebellar tract, 322
Omental bursa, 107, 108
Omentum
lesser omentum
anatomy, 111
embryology, 103
Omphalomesenteric veins, 60
Oocytes, 167, 175
Oogenesis, 4
Oogonia, 175
Open-angle glaucoma, 338
Open pneumothorax, 46
Ophthalmic artery, 217, 357, 369
Ophthalmic nerve, 228, 292
Ophthalmic veins, 227
Optic canal, 223, 225, 357
Optic chiasm
anatomy, 288, 354
histology, 332
issues, 345
Optic disc, 337
Optic neuritis, 251
Optic radiations, 344, 348, 357, 367
Optic tract, 290, 342, 344, 345, 351
Oral cavity
histology, 119
oral mucosa, 20
teeth, 239, 12, 298
Orbital artery, 358
Orbital muscles, 339, 292
Organ of Corti, 303
Organ system embryology, 10
Oropharynx, 224
Ossicles, 302
Otosclerosis, 303
Ova
fertilization, 176, 177
meiosis, 4, 6, 7
metaphase arrest, 6
oviducts, 177
ovulated over lifetime, 175
ovulation, 175, 176
Ovarian vessels, 160
Ovaries
anatomy, 160
histology
follicles, 174, 175
oviducts, 177
meiosis, 4, 6, 7
oogenesis, 4
Oviducts
anatomy, 177
ectopic pregnancy, 178
fertilization, 6, 177
histology, 173, 177
ovulation, 176
Ovulation, 175, 176
Oxyntic cells, 121
Oxytocin from hypothalamus, 349

P

Palatoglossus muscle, 221
Palmar cutaneous branch, 198
Palpebral fissures, 223
Pampiniform venous plexus, 99
Pancoast tumor, 48
Pancreas
anatomy
arterial supply, 113
annular pancreas, 110
detail, 107
embryology
foregut derivative, 103
histology as exocrine, 129
Pancreatic ducts, 109
Paneth cells, 118, 123, 125
Papez circuit, 372, 373
Papilla (kidney), 147, 148
Parafollicular (C) cell embryology, 12, 239
Parallel fibers, 322, 325
Parallel gaze, 292, 293
Paramedian arteries, 357
Paramedian arteries, 313
Paramedian pontine reticular formation (PPRF), 309, 310
Paramesonephric ducts, 3, 144, 155
Parasternal nodes, 41, 42
Parasympathetic nervous system
anatomy, 242, 38, 39
bladder, 242, 146
eye muscles, 337, 338, 340
gut innervation, 242, 103, 115
penile erection, 172
salivary glands, 38, 128
Parathyroid glands, 223, 239
Paraumbilical veins, 141
Paraventricular nucleus, 349, 351
Paravertebral motor ganglia, 36, 243
Parellel fibers, 322
Paresthesias, 284
Parietal lobe
anatomy
arterial supply, 357, 358
auditory association cortex, 367
corticospinal tract, 268
detail, 353, 370
magnocellular system, 366
thalamus, 348
visual association cortex, 365
visual information, 345
lesions, 365, 370
sensory homunculus, 355
Parietal peritoneum, 97, 100
Parietal pleura, 45, 47
Parieto-occipital sulcus, 353
Parinaud syndrome, 320
Parkinson's disease, 247, 334
Parotid gland, 239, 12, 38, 129
Parvocellular-blob system, 365
Parvocellular neuron, 349
Passive immunity, 124, 181
Patella, 270

Patella, 214
Patellar ligament, 270
Patellar tendon, 270
Patent ductus arteriosus (PDA), 66, 73
Pectinate line, 116, 139, 144
Pectinate muscles, 60, 62
Pectineus innervation, 204
Pectoralis major, 190, 192
Pectoralis minor, 190
Pectoral nodes, 41
Pedicles (vertebrae), 29
Pelvic diaphragm, 157
Pelvic splanchnic nerves
  innervation, 103, 116
  parasympathetic nervous system, 103
Pemphigus vulgaris, 20
Penile urethra, 147, 158, 173
Penis
  ejaculation, 172
  erection, 172
  issues, 98, 155, 172
Periaqueductal gray matter, 320
Pericallosal artery, 358
Pericardiocentesis, 75
Pericardium, 45
Pericranium, 259
Pericytes and blood–brain barrier, 250
Perikaryon histology, 245
Perilymph, 302
Perineal membrane, 160
Perineum, 95, 146, 157, 160
Periosteal dura mater, 225, 229
Peripheral nervous system (PNS)
  anatomy
    cranial and spinal nerves, 235
    myelin, 250, 239, 251
    neurons, 245
    parasympathetic nervous system, 240
    pre- vs. postganglionic neurons, 36
  embryology, 235, 236
  neurons, 19
Peritoneal cavity, 100, 107
Peritoneum
  anatomy, 45
  parietal peritoneum, 97, 100
Persistent truncus arteriosus, 220
Peyer's patches, 119, 126
Pharyngeal apparatus embryology, 218, 220
Pharyngeal arches, 12, 218, 221, 223, 239
Pharyngeal grooves, 218, 223
Pharyngeal pouches, 218, 223
Pharyngeal tonsil, 51
Pharynx
  embryology, 218, 239, 220
Philtrum, 222
Phrenic nerve, 46, 71, 73
Pia mater
  cranial meninges, 259
  embryology, 239
  spinal meninges, 31, 263
"Pill-rolling" tremor, 334
Pineal gland
  anatomy, 288, 354
  anatomy, 351
  as epithalamus, 349, 352
  circadian rhythm, 349
  embryology, 237, 239
  melatonin, 349
  miosis, 339
  radiology, 375
  tumors, 339, 318
Piriformis syndrome, 206
Pituitary gland
  anatomy
    brain, 288, 354
    pituitary stalk, 255
  hypothalamus, 349
  pituitary adenoma, 344
  radiology, 375
Placenta, 8, 60, 62, 177
Plantar arterial arch, 208
Plantar muscles, 204
Plasma cells, 120, 180
Plasma membrane at cell junctions, 21
Pleura, 45, 47, 51, 87
Pleural cavity, 45
Pleural recesses, 47
Pleural reflections, 47
Pleurisy, 46
Plicae circulares, 124
Pneumocytes, 43, 57, 58
Pneumothorax, 46
Podocytes, 150, 152
Poikilothermia and hypothalamus, 349
Polar body in oogenesis, 6
Polkissen cell, 153
Polydipsia from diabetes insipidus, 349
Polyhydramnios, 43, 236
Polymorphonuclear leukocytes in CSF, 261
Polysomes, 245, 248
Polyuria, 349
Pons
  anatomy
    brain, 288
    cranial nerves, 288, 299
    detail, 287, 290
    vestibular system, 297
  arterial supply, 358
  brain, 353, 354, 355
  embryology, 237
  hypertension infarcts, 360
  pontine gaze center, 309
  pontine syndromes, 369
  radiology, 375
Pontine arteries, 369
Pontine nuclei, 325
Pontocerebellum, 326
Popliteal artery, 208
Popliteus ligament, 211
Pores of Kohn, 58
Portal vein, 60, 108, 112, 130
Postcentral gyrus, 275, 279, 279
Postductal coarctation, 73
Posterior auricular artery, 217
Posterior cerebral arteries
  anatomy, 357, 358, 359, 360
  disconnect syndromes, 369
  occlusion, 318, 360, 369
Posterior communicating arteries, 312, 358, 360, 369
Posterior cruciate ligament, 212
Posterior division fibers (brachial plexus), 187
Posterior femoral cutaneous innervations, 205
Posterior fossa, 255
Posterior inferior cerebellar artery (PICA), 313, 358, 369
Posterior interventricular artery, 83
Posterior mediastinum, 69, 70
Posterior parietal association cortex, 363
Posterior tibial artery, 208
Potter's sequence, 44
Precentral gyrus, 353, 361
Prechordal plate, 10
Preductal coarctation, 73
Prefrontal cortex, 348, 373, 362
Premature infants, 43
Preoptic area, 349, 352
Presbycusis, 303
Pretectal nuclei, 289, 339
Prevertebral motor ganglia, 36, 243
Primitive neuroectodermal tumor (PNET), 255
Primitive streak, 11
Primordial follicle, 175
Primordial germ cells, 239, 12, 175
Processus vaginalis, 100, 156
Profunda femoris artery, 208
Progesterone, 10, 177
Progressive multifocal leukoencephalopathy (PML), 251
Prolactin inhibition, 350
Prolapse of uterus, 160
Proper hepatic artery, 108, 112, 135
Prosopagnosia, 366
Prostaglandin E (PGE), 62, 66
Prostaglandins from kidney, 147
Prostate gland
  hyperplasia, 158
Prostatic urethra, 144, 146, 159, 170
Proximal convoluted tubule, 150
Psammoma bodies, 255
Pseudobulbar palsy, 251
Pseudopalisading necrosis, 255
Pseudounipolar neurons, 12, 274
Pterygoid venous plexus, 228
Puberty
  hypothalamic lesion, 349

seminiferous tubules and Sertoli cells, 168
spermatogenesis, 165
Pubic symphysis, 95
Pubic tubercle, 95
Pubis and descent of testes, 99
Puborectalis, 115, 157
Pudendal canal, 163
Pudendal nerve
anatomy, 160
anatomy, 163
innervation, 116, 127, 160, 172
pudendal nerve block, 160
Pudendal vessels, 146
Pulmonary arteries
embryology, 218
Pulmonary hypoplasia, 44
Pulmonary neuroendocrine (PNE) cells, 54
Pulmonary semilunar valve, 81
Pulmonary trunk, 66, 71, 75
Pulmonary veins, 75, 78, 87
Pulse points, 208
Pulvinar nucleus, 347
Pupil
anatomy, 338
Argyll Robertson, 339
mydriasis, 318
pupillary abnormalities, 318, 320
pupillary light reflex, 338
Purkinje cells, 322
cerebellum
anatomy, 322, 323, 324
circuitry, 324
muscle, 85
Purkinje layer (cerebellum), 322
Putamen, 329, 334, 369
Pyloric antrum, 113
Pylorus, 93, 103, 113, 119, 135
Pyramidal decussation
anatomy of medulla, 291
motoneuron lesions, 272
spinal cord, 263
Pyramids, 295

Q

Quadrantanopsia, 357
Quadratus femoris innervation, 205
Quadriceps femoris, 204, 211, 270

R

Radial artery, 196
Radial groove, 196, 200
Radial nerve
anatomy, 187, 189, 198
lesions, 195
Radial pulse and thoracic outlet syndrome, 215
Radiation causing lung cancer, 51
Radical mastectomy and long thoracic nerve, 41
Radiology
abdomen, 180
brain, 331, 358, 375
Radius, 201
Rami
dorsal ramus, 34
ventral ramus, 34
Raphe nuclei, 320, 372
Rathke's pouch, 239, 255
Receptive aphasia, 364
Rectum
anatomy, 107, 137, 138, 141, 157
embryology, 102
Rectus abdominus muscle, 96
Rectus sheath, 95, 96
Recurrent laryngeal nerves, 219
Red nucleus, 268, 289, 316, 326, 327
Referred pain, 87, 103, 118
Reflections of pleura, 47, 146
Renal arteries, 134, 138
Renal corpuscle, 150
Renal pyramids embryology, 143
Renal veins, 139
Renin from kidney, 147
Renshaw cells, 267
Reproductive organs
embryology, 239
histology of testes, 164, 169
Respiratory bronchioles, 56
Respiratory system
chronic infections, 23
embryology, 42
pain, 46
Rete ovarii embryology, 155
Rete testes, 155, 164
Reticular formation, 326
Reticular lamina, 20, 21
Reticulospinal tract, 266
Retina
anatomy
arterial supply, 357, 369
detail, 342, 344
eye, 338
image, 342
light path, 337
Meyer's loop, 343
circadian rhythms, 349
embryology, 237
image, 308, 344
light path, 337, 342
Retinoblastoma, 255
Rheumatic fever, 335
Rhinorrhea from cribriform plate fractures, 223
Rhomboids innervation, 190
Ribs
anatomy, 215
spleen laceration, 114
sternal angle, 69
Right colic artery, 136
Right colic artery, 136
Right gastroepiploic artery, 135
Right hypochondrium, 94
Right inguinal, 94
Right-left disorientation, 364
Right lumbar, 94
Right lymphatic duct, 49
Right renal vein, 138
Right suprarenal vein, 139
Rigidity, 272, 334, 335
Rinne test, 305
Robin sequence, 223
Rods (retina), 337
Rods (retina), 342
Romberg sign, 284, 327
Rosenthal fibers, 255
Rosettes, 255
Rotator cuff, 192, 199
Round ligament (uterus), 98
Round window, 303
Rubella and patent ductus arteriosus, 66
Rubrospinal tract, 326
Rugae, 119, 120

S

Saccule, 306
Sacral hiatus, 27
Sacral region chordoma, 11
Sacral vertebrae
anatomy, 25, 41, 93, 95
nerves, 33, 242, 38
Sacrococcygeal teratomachordoma, 11
Sacrotuberous ligament, 163
Saddle injury, 173
Salivary glands
anatom
detail, 129
anatomy, 120
as exocrine
submandibular glands, 18
detail, 128
histology
detail, 17, 128
parotid gland, 129
sublingual glands, 129
submandibular glands, 129
tumors, 129
viruses in saliva, 129
Saltatory conduction, 250
Saphenous nerve innervation, 207
Sartorius innervation, 204
Satiety center, 349, 352
Savage behavior and hypothalamus, 349
Scala tympani, 302
Scalene triangle of neck, 215
Scalp, 259
Scanning dysarthria, 325, 327
Scaphoid, 201
Scapula, 41, 44, 90

Scarpa fascia, 95, 162
Schwann cells
  embryology, 250, 239
  histology, 245, 255
  myelin for PNS, 239, 250
Schwannomas, 255
Sciatica from herniated disk, 31
Sciatic nerve, 206
Sclera, 338
Sclerotome cells, 27
Scrotum, 98, 100, 155, 156, 173
Secondary oocytes, 6, 7, 167
  metaphase arrest, 6, 175
Secondary retroperitonealization, 107
Secretin from duodenum, 119
Secretion(s)
  gastric. *See* Gastric secretions
Segmental innervation, 263
Selectin, 20
Selective transport at blood–brain barrier, 253
Sella turcica, 259
Semen, 172
Semicircular canal, 305
Semicircular ducts
  anatomy, 305, 306
Semimembranosus innervation, 204
Seminal vesicles
  emission of sperm, 172
  male pelvic viscera, 163
Seminiferous tubules
  histology, 166
  rete testis, 169
Semitendinosus innervation, 204
Sensory ganglia, 12, 34, 239, 249
Sensory homunculus, 355
Septal nuclei, 373, 334
Septation of heart tube
  anatomy, 63
Septomarginal trabecula, 79
Septum pellucidum, 288, 354
Septum primum, 63
Septum secundum, 64
Seromucous glands, 52, 55
Serosa, 117
Serotonin, 320
Serous membranes
  embryology, 239
  reflections, 47, 75
  serous fluid, 45, 46, 75
Serous pericardium, 75
Serratus anterior, 190
Sertoli cells
  FSH receptors, 168
  histology, 166
  Müllerian-inhibiting factor, 3
Shoulder
  arterial supply, 217
  innervation, 188
  lesions, 195
  radiology, 189
  referred pain, 46
Sigmoid arteries, 137
Sigmoid colon, 103, 107, 115, 137
Sigmoid dural venous sinus, 259, 228
Sinoatrial (SA) node, 83
Sinus venosus
  embryology, 59
Skeletal muscle
  anatomy
    cerebellum, 321
    motoneurons lesions, 273
    motor units, 270
    muscle spindle, 283
    muscle tone, 273
    reflexes, 266
  embryology, 239
  fasciculations, 273
  motor cortex, 361
  Parkinson's disease, 334
  retrograde axonal transport disorders, 249
Skin
  anatomy, 93, 259
  histology, 13
Skull
  arterial supply, 217
  dural venous sinuses, 259
  epidural space, 226
Small intestine
  histology
    detail, 122
    lacteals, 123, 124, 126
    microvilli, 119, 123
    simple columnar epithelium, 15, 117
    villi, 124
Smooth muscle
  anatomy
    autonomic motor innervation, 240, 36
    GI-tract gap junctions, 117
    parasympathetic nervous system, 242, 38
    sympathetic nervous system, 36, 243
  embryology, 239
  histology, 177
Snuffbox, 195
Soft palate, 219, 295
Soleus innervation, 204
Solitary nucleus and tract, 292, 316
Somatic motor efferents and ejaculation, 172
Somatosensory cortex
  lesions
    thalamus, 347
  primary
    anterolateral system, 275
    dorsal column–medial lemniscal system, 274
    lesions, 363
    parietal lobe, 363
    sensory homunculus, 363
    stroke-related deficits, 369
  radiology, 375
Somites, 27, 236, 11, 219
Somitomeres, 219
Space of Disse, 130, 133
Spastic bladder, 146
Spastic hemiparesis, 314, 316, 318
Spastic paralysis, 272, 369
Spastic paresis, 273, 286, 357, 362
Spastic quadriparesis, 251
Spastic weakness, 273, 285
Spenoidal sinus, 228
Spermatic cord, 98
Spermatids, 6, 166, 168
Spermatocytes, 6, 165, 166, 168
Spermatogenesis, 4, 6, 165, 168
Spermatogonia, 6, 165
Spermatozoa
  anatomy, 169
  ejaculation, 172
  histology, 167
  issues, 11, 23, 53
  Sertoli cells, 168
  spermatogenesis, 6
Spermiogenesis, 6, 167
Sphincter of Oddi, 115, 130
Spina bifida, 235, 238
Spinal cord
  anatomy
    Clarke nucleus, 267
    conus medullaris, 33
    detail, 263, 265
    dorsal horn, 263
    motoneurons, 268
    motoneurons lesions, 273
    rexed laminae, 266
    segmental innervation, 263
    sensory systems, 274
    sympathetic nervous system, 36
    trigeminal nucleus, 297
  corticobulbar innervation, 300
  embryology, 27, 235, 236, 237
  lesions, 283
Spinal cord. See also Cerebrospinal fluid; Spinal nerves
  lesions, 146, 318
  spina bifida, 235, 238
  stroke-related deficits, 369
Spinal meninges
  arachnoid mater, 31, 32, 32, 239
  detail, 31
  dura mater, 32
  epidural space, 35
  intervertebral foramina, 31
  pia mater, 265, 33
  spina bifida, 238
Spinal nerves
  anatomy, 265, 33

as peripheral nervous system, 33
cauda equina, 33
dorsal root as sensory, 34
herniated disk, 30
segmental innervation, 263, 265
spinal meninges, 31
ventral rami, 187, 34
vertebral column, 27, 29, 31
Spinal tap, 35
Spines of vertebrae, 29
Spinocerebellar tract, 322, 326
Spinothalamic tract
anatomy
hypothalamic fibers, 290, 295, 296, 299
medulla, 290, 295
midbrain, 290
pons, 290
thalamu, 348
anterior spinal artery occlusion, 286
lesions of spinal cord, 284
Spleen
anatomy, 107, 135
embryology, 239, 103, 110
hematopoiesis, 9
Splenic artery, 135
Splenic flexure, 138
Splenium
arterial supply, 357, 359
Dandy-Walker malformation, 238
posterior cerebral artery occlusion, 366
radiology, 332, 375
Splenorenal ligament
anatomy, 109, 114
embryology, 110
splenorenal ligaments
embryology, 103
Spontaneous abortion hCG levels, 10
Sprains of ankle, 213
Squamous metaplasia, 55
Staining tissue
eosinophilic, 45, 247, 255
hematoxylin and eosin, 14
immunostaining with GFAP, 255
Nissl stain, 248
Stapedius, 219, 302
Stapes, 219
Stapes, 302
Stellate cells (cerebellum), 322, 325
Stellate cells (liver), 133
Stensen's ducts, 129
Stereocilia, 22, 170
Sterility, 99, 156
Sternal angle, 72, 75
Sternocleidomastoid, 215, 224, 296, 300
Sternum, 44, 47
Steroids from theca interna, 175
Stomach
anatomy, 107, 114, 134
embryology, 102
histology, 119, 121, 122
mucosal secretions, 119
Stomach, 122
Straight dural venous sinus, 259, 259, 227
Stratum basale, 17
Stratum corneum, 17
Stratum granulosum, 17
Stratum lucidum, 17
Stratum spinosum, 17
Striate cortex, 344, 365
Striated ducts, 128, 130
Striatum (basal ganglia), 329, 331, 335
Stroke-related deficits, 369
Stylohyoid, 219
Styloid process embryology, 219
Stylopharyngeus muscle, 219
Subarachnoid hemorrhage, 226, 360
Subarachnoid space, 226
cranium
cerebrospinal fluid, 238, 258, 259, 260, 261
cranial meninges, 226
hydrocephalus, 238
subarachnoid hemorrhage, 230
spinal meninges, 31
Subclavian arteries
head/neck arterial supply, 217
mammary gland, 41
neck, 215
upper limb, 196
Subclavian nodes, 41
Subclavian veins, 49
Subcortical nuclei, 375
Subdural hematoma, 360
Subdural space, 226
Subiculum, 371, 373
Sublingual glands, 38, 239
Submandibular glands
embryology, 239
histology, 128
Submucosal layer of GI tract, 117
Subscapular arteries, 73, 196
Subscapularis, 190, 199
Subscapular nodes, 42
Substantia nigra
basal ganglia, 329, 331, 332
midbrain, 287
neuron Lewy bodies, 247
Parkinson's disease, 334
ventral anterior thalamic nuclei, 348
Subthalamic nucleus, 329, 334, 349, 360
Subthalamus, 237, 347, 349
Sulci (cerebral cortex), 353
Sulcus limitans, 235
Superficial abdominal veins, 141
Superficial fibular nerves, 204, 206
Superficial inguinal ring, 95, 96, 98
Superficial lymphatic plexus, 50
Superficial palmar cutaneous branch, 190
Superficial perineal fascia, 161
Superficial temporal artery, 217
Superior cerebellar artery, 313, 316, 357, 369
Superior cerebellar peduncle (SCP), 292, 290, 369
Superior cervical ganglion, 36, 230, 243
Superior colliculi, 290, 320, 344
Superior cuneus, 353
Superior frontal gyrus, 353, 357
Superior gemellus innervation, 205
Superior glenohumeral ligament, 199
Superior gluteal nerve, 203, 205, 206
Superior inch, 357
Superior laryngeal nerve, 219
Superior longitudinal fasciculus lesions, 364
Superior mediastinum, 71
Superior mesenteric ganglion, 103
Superior mesenteric vessels
abdominal aorta, 134, 136
inferior vena cava, 138, 139
midgut, 103
Superior oblique muscle, 230
Superior olivary nuclei, 292
Superior pancreaticoduodenal branches, 113, 136
Superior parathyroid gland embryology, 220
Superior parietal lobule, 353, 357
Superior petrosal dural venous sinus, 259, 227, 228
Superior quadrantanopia, 344, 357
Superior rectal artery, 137
Superior rectal veins, 141
Superior rectus, 230
Superior sagittal dural venous sinus, 261
Superior temporal gyrus, 353
Superior thyroid artery, 217
Superior vena cava
heart anatomy, 75
heart conducting system, 84
Supinator, 192
Suprachiasmatic nuclei, 344, 349
Supramarginal gyrus, 353, 363
Supraoptic nuclei, 349
Suprarenal gland, 113
Suprascapular artery, 196, 217
Suprascapular nerve, 190, 192, 195
Supraspinatus muscle, 190, 195, 199
Supraspinatus tendon, 199
Sural nerves innervation, 207
Surface ectoderm derivatives, 12
Surfactants, 43
Suspensory ligament (lens), 339
Suspensory ligament (ovary), 159
Sydenham chorea, 335
Sympathetic
sympathetic nervous system, 36
Sympathetic ganglion, 263

Sympathetic nervous system
anatomy, 36, 243
innervation, 85, 103, 116, 117, 128, 230, 338
Synapses, 249
Synapsis of chromosomes, 4
Syncytiotrophoblast, 8, 9
Synovial articulations, 27
Synovial membrane, 199
Syringomyelia, 238, 285

T

Tabes dorsalis, 339, 284, 284
"Talk and die" syndrome, 360
Tanycytes, 252
Taste, 295, 298, 315
Taste, 221
Tau protein, 248
Tectorial membrane, 302
Teeth, 239, 12, 255
Teeth, 222
Telencephalon, 237, 238, 329
Temporalis, 219, 297
Temporal lobe
Alzheimer disease, 375
anatomy, 357, 360, 366, 370
auditory system, 367
detail, 353
lesions, 370, 374
olfactory system, 371, 373
Temporal Lobe, 367
Tendons and Golgi tendon organs, 270
Teniae coli, 126
Tension pneumothorax, 46
Tensor fasciae latae innervation, 205
Tensor tympani, 219, 302
Tensor veli palatini, 219
Tentorium cerebelli, 259, 225, 226, 228
Teres major, 190, 196
Teres minor, 199
Terminal bronchioles, 55
Terminal ganglia of PNS, 242, 241, 38
Testes
anatomy, 99, 165
cremasteric reflex, 99
descent, 98, 99
histology
detail, 165
genital ducts, 169
interstitial tissue, 168
prostate, 172
seminal vesicles, 171
issues, 98, 99, 155
lymphatic drainage, 99
meiosis, 4, 6
spermatogenesis, 4, 6
Testicular artery, 98
Testicular feminization syndrome, 156
Testis-determining factor (TDF), 3, 155
Testosterone, 3, 155
Tetanus toxin, 249
Tetralogy of Fallot, 69, 239
Thalamic pain syndrome, 348
Thalamocortical projections, 356, 367
Thalamus
anatomy
basal ganglia, 329
brain, 288
cerebellum, 326
detail, 347
hypothalamus, 352
limbic system, 371, 372, 373
Papez circuit, 372
embryology, 237, 347
radiology, 332
stroke-related deficits, 369
Theca folliculi, 175, 177
Thigh
anatomy, 97, 207, 208
cremasteric reflex, 99
innervation, 203
Thirst from diabetes insipidus, 349
Thoracic aorta, 44, 71, 73
Thoracic inlet, 44, 69
Thoracic outlet syndrome, 48
Thoracic spinal nerves, 263
Thoracic splanchnic nerves
innervation, 103
sympathetic nervous system, 36, 103
Thoracic vertebrae, 27, 44, 33, 36
Thoracodorsal nerve, 41, 190
Thoracolumbar outflow, 36, 243
Thromboses, 229, 360
Thymoma, 70
Thymus
embryology, 239, 220
thymoma, 70
Thyrocervical artery, 217
Thyroglossal duct, 221, 223
Thyroid gland
embryology, 218, 221, 239
Tibia, 208, 211
Tibial collateral ligament, 211
Tibialis anterior innervation, 204
Tibialis posterior innervation, 204
Tibial nerve, 203, 204, 206, 207, 208
Tics from Tourette syndrome, 334, 335
Tinnitus, 255
Tongue
embryology, 218
issues, 314
Tonofilaments, 20
Tourette syndrome, 334, 335
Trachea
cilia, 16, 52
embryology, 42, 239
lung lymph nodes, 50
sympathetic nervous system, 36
Tracheoesophageal septum, 43
Transcortical apraxia, 364
Transport. *See* Active transport
Transversalis fascia, 96
Transverse acetabular ligament, 210
Transverse cervical artery, 215
Transverse cervical ligament, 160
Transverse colon, 103, 107, 115, 137, 181
Transverse dural venous sinus, 259, 259, 228
Transverse gyri of Heschl, 367
Transverse pericardial sinus, 75
Transverse processes (vertebrae), 29
Transverse temporal gyrus, 304
Transversus abdominis muscle, 96
Trapezium carpal bone radiology, 201
Trapezius, 215, 296, 300
Trapezoid body, 304
Treacher Collins syndrome, 223
Triceps reflex, 270
Tricuspid valve
anatomy, 78
issues, 80
Trigeminal nuclei, 297
Trigone (bladder), 144
Triquetrum, 198, 201
Trisomy 13 holoproscencephaly, 238
Trochlea, 230
Trochlear nucleus, 287, 299
Trophoblast, 8, 11
Trophoblastic disease, 10, 11
Truncus arteriosus, 59, 60, 66
Tubal ectopic pregnancy, 178
Tuber cinereum, 354
Tubercle (scaphoid), 198
Tuberohypophysial tract, 349
Tuberoinfundibular tract, 351
Tubuloalveolar glands, 172
Tunica albuginea, 164
Tunica vaginalis, 100
Tuning fork, 305
Tympanic cavity embryology, 239

U

Ulna, 201
Ulnar nerve
innervation, 187, 188
lesions, 195
radiology, 189
Umbilical arteries, 62
Umbilical cord, 106
Umbilical region of abdomen, 141
Umbilical vein, 60, 61
Uncinate process, 109, 113
Unicellular gland histology, 18
Upper limb
brachial plexus, 187, 190
rotator cuff, 192
sympathetic nervous system, 36
Upper subscapular nerve, 190
Urachus, 144
Ureteric bud, 142

Ureters
anatomy, 107, 146, 160
embryology, 239
Urethra
anatomy, 157, 162
ejaculation, 172
embryology, 239
epispadias, 156
hypospadias, 156
laceration in catheterization, 173
Uriniferous tubules, 149
Urogenital diaphragm, 157, 161, 163
Urogenital folds, 155
Urogenital membrane, 146
Urogenital triangle, 160
Uterosacral ligament, 160
Uterus
anatomy, 98, 159
embryology, 177
histology, 178, 179
prolapse, 160
tubal ectopic pregnancy, 178
Utricle, 305, 306
Uvula, 295, 315

V

Vagina
anatomy, 157, 159, 163
histology, 179
issues, 161
Varicoceles, 99, 138
Vasectomy, 170
Vasopressin. *See* Antidiuretic hormone (ADH)
Venae cordis minimae, 84
Ventral anterior thalamic nuclei (VA), 324, 347
Ventral embryonic mesentery, 103
Ventral horn, 266, 267, 269, 281, 285
Ventral lateral thalamic nucleus (VL), 326, 347
Ventral nuclear group, 348
Ventral posterolateral nucleus (VPL)
detail, 347
Ventral posteromedial nucleus (VPM), 348
Ventral rami, 34
Ventral root (spinal nerves), 265, 265, 267, 268, 34
Ventral white commissure, 277
Ventricles (brain)
anatomy
brain, 288
cerebral aqueduct, 258, 261, 299
choroid plexus, 252, 257
detail, 257
ependymal cells, 252
medulla, 291
pons, 290
congenital malformations of brain, 238
embryology of vesicles, 237
histology of basal ganglia, 332
holoproscencephaly, 238
internal capsule, 367
radiology, 375
Ventricles (heart)
anatomy, 79, 85
embryology
heart tube septation, 65
radiology, 91
Ventromedial nucleus, 349
Vermis (cerebellum), 347
anatomy, 290, 321, 322, 326
lesions, 238
radiology, 375
Vertebrae
anatomy, 238
whiplash, 30
Vertebral artery
cerebral cortex, 356, 358
stroke-related deficits, 369
Vertebral column
herniated disk, 30
ligaments, 27, 30
spinal cord, 263
spinal meninges, 12, 31
spinal nerves, 33
vertebrae, 27, 29
whiplash, 30
Vertebrobasilar circulation, 360, 369
Vertigo, 251
Vesicouterine pouch, 159
Vestibular labyrinth, 302
Vestibular nuclei
cerebellum, 322, 323, 326
lesion, 306, 315
medulla, 291
Vestibular system
anatomy, 291
eye movement, 309
lesions, 307
Vestibulocerebellar tract, 322, 326
Villi, 126
Vinblastine, 19
Viruses, 249
Visceral peritoneum, 107, 111, 178
Visceral pleura, 46, 47, 50
Visual agnosia, 366
Visual association cortex, 360
Visual cortex
primary, 365
Visual pathways
anatomy, 338
visual reflexes, 338, 299
Vitamin A, 337
Vitelline fistula, 111
Vitreous humor, 337
Vomiting, 229, 316
Vomiting, 315

W

Wallerian degeneration, 254
Weber syndrome, 318
Weber test, 305
Wernicke encephalopathy, 349, 374
Wernicke's area, 329, 360
Wharton's ducts, 129
White blood cells in GI tract, 117
White matter, 34
White ramus communicans, 38
Wilson disease, 334
Wrist, 189, 192, 193, 195

Z

Zona pellucida, 8, 175, 176
Zonula adherens, 19, 20, 22
Zygomatic arches, 223
Zymogen granules, 122, 129